

Adam Mohamad<sup>1</sup>, Wan Ishlah Leman<sup>2</sup>, Zamzil Amin Asha'ari<sup>2</sup>, Irfan Mohamad<sup>1</sup>

## Guz Potta w przebiegu zapalenia zatok czołowych

### Pott's puffy tumour secondary to frontal sinusitis

<sup>1</sup> Department of Otorhinolaryngology, Head & Neck Surgery, School of Medical Sciences, Universiti Sains Malaysia Health Campus, 16150 Kota Bharu, Kelantan, Malaysia

<sup>2</sup> Department of Otorhinolaryngology, Head & Neck Surgery, International Islamic University Malaysia Medical Centre, Bandar Indera Mahkota, Jalan Sultan Ahmad Shah, 25200 Kuantan, Pahang, Malaysia

Correspondence: Adam Mohamad, Department of Otorhinolaryngology, Head & Neck Surgery, School of Medical Sciences, Universiti Sains Malaysia Health Campus, 16150 Kota Bharu, Kelantan, Malaysia, e-mail: persona522115@gmail.com

#### Streszczenie

Zapalenie zatok czołowych jest często spotykanym schorzeniem w praktyce otorynologicznej. U większości pacjentów obserwuje się ból w okolicy czołowej nasilający się podczas pochylania do przodu, upośledzenie zmysłu węchu, a w niektórych przypadkach kakosmię. Guz Potta to zapalenie kości i szpiku w obrębie kości czołowej – pierwotnie opisywano go jako następstwo urazu, jednak może być również spowodowany zapaleniem zatok czołowych. W pracy przedstawiono przypadek guza Potta obejmującego zatokę czołową i charakteryzującego się szybką progresją. Po ustąpieniu obrzęku w wyniku zastosowanej antybiotykoterapii pacjenta poddano zabiegowi czynnościowo-endoskopowej chirurgii zatok przynosowych.

**Słowa kluczowe:** zapalenie zatok przynosowych, guz Potta, czynnościowo-endoskopowa chirurgia zatok przynosowych

#### Abstract

Frontal sinusitis is a common encounter in otorhinolaryngology practice. Most patients will present with frontal headache which worsens on bending forward, reduced sense of smell and sometimes cacosmia. Pott's puffy tumour is an osteomyelitis of the frontal bone, which was originally described as a result of trauma, but it can also develop as a result of frontal sinusitis. We present a rare case of a rapidly progressing Pott's puffy tumour involving the frontal sinus. The oedema subsided after antibiotic treatment and the patient underwent functional endoscopic sinus surgery.

**Keywords:** frontal sinusitis, Pott's puffy tumour, functional endoscopic sinus surgery

## INTRODUCTION

Pott's puffy tumour is a rare non-neoplastic complication of frontal sinusitis characterised by osteomyelitis of frontal bone and subperiosteal abscess formation. It was first described by Sir Percival Pott in 1768 in relation to frontal head trauma. Later this condition was known to occur secondary to frontal sinusitis<sup>(1)</sup>. Despite its rare occurrence, it can also give rise to serious intracranial complications such as epidural abscess, subdural abscess, meningitis, cavernous sinus thrombosis and brain abscess<sup>(2)</sup>.

## CASE REPORT

A 45-year-old man presented with right frontal swelling of one-week duration accompanied by mild pain, yellowish nasal discharge and nasal congestion. The swelling on the right side of the forehead resembled a "flower-horn fish." Other than that, the patient reported facial discomfort and cacosmia. There was no fever or history of facial trauma.

On examination, the patient was alert and conscious. His vital signs were stable. There was a large doughy swelling measuring 3 × 3 cm over his right frontal region, which was tender on palpation. Nasendoscopic examination revealed inflamed, congested and oedematous right ostiomeatal complex with mucopus and a grade I polyp. Computed tomography (CT) of paranasal sinuses (PNS) showed sclerosis of the surrounding bony structures of the right frontal sinus with minimally enhancing soft tissue density occupying the right frontal sinus (Fig. 1), which

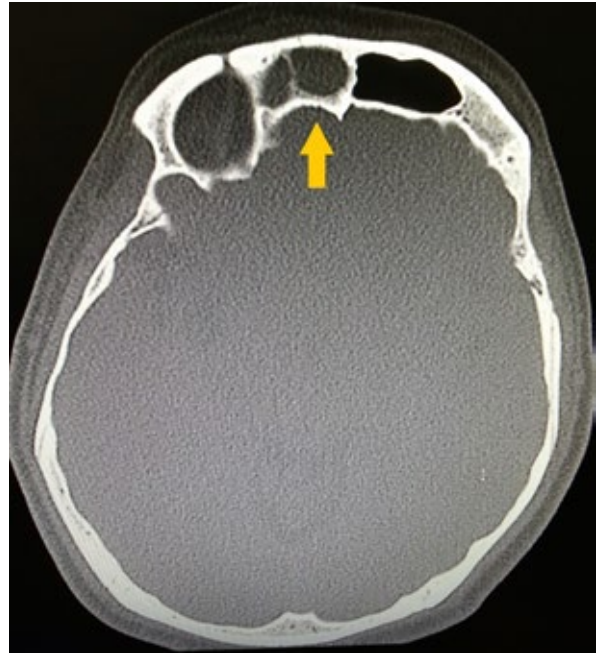

Fig. 1. Axial view of the CT scan showing sclerosis of the surrounding bony structures of the right frontal sinus with dense soft tissue located inside (arrow)

extended in the right frontal recess. Other than that, the overlying scalp was mildly thickened with irregularity and enhancement in the adjacent right frontalis and right orbicularis oculi muscle with bony defects identified in anterior and posterior walls of the right frontal sinus (Fig. 2 A, B). Other than that, a mucosal thickening was found in the right ethmoidal and right maxillary sinuses.

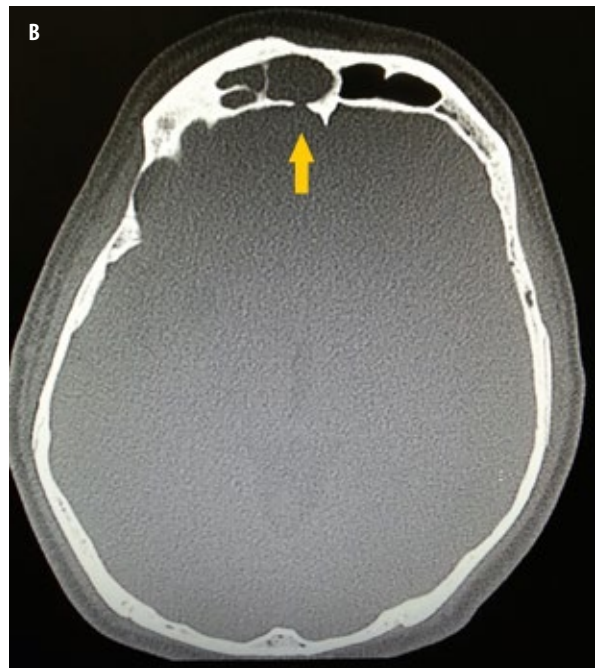
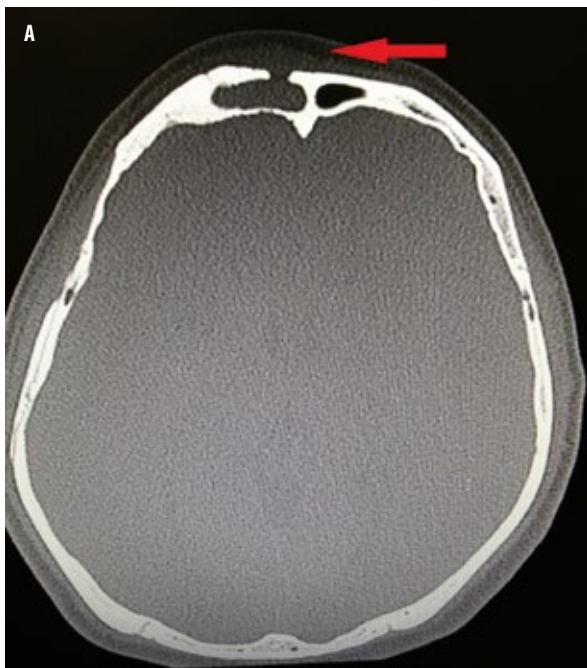
Fig. 2. A bony defect in the anterior and posterior wall of the right frontal sinus (arrow). There is also mild thickening with irregularity and enhancement at the adjacent right frontalis and orbicularis muscle (arrow)

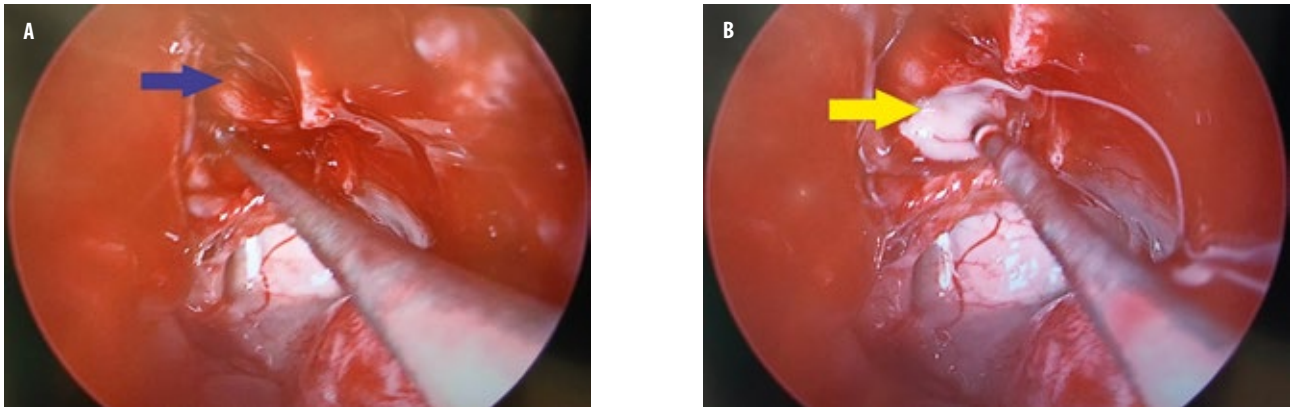


Fig. 3. Mucocele (blue arrow) found in the right frontal sinus, which ruptured during manipulation (yellow arrow)

However, there was no evidence of subdural or extradural collections adjacent to the frontal sinus.

The patient was diagnosed with right frontal sinusitis with Pott's puffy tumour. Intravenous (IV) amoxicillin-clavulanic acid 1.2 g thrice daily for 1 week, followed by tablet amoxicillin-clavulanic acid 625 mg thrice daily for another 2 weeks as well as tapering dosage of oral prednisolone were included. The swelling subsided after antibiotic treatment and the patient underwent right functional endoscopic sinus surgery using image guided system. Mucocele were found intraoperatively in the frontal sinus, which ruptured upon manipulation, releasing purulent discharge (Fig. 3 A, B). There was no cerebrospinal fluid leakage. The patient received postoperative IV amoxicillin/clavulanic acid 1.2 g thrice daily and tablet diclofenac 50 mg thrice daily. He was discharged 2 days after the surgery. A follow-up a week later confirmed complete oedema resolution and improved condition of the patient (Fig. 4).

## DISCUSSION

Pott's puffy tumour is a rare clinical entity in this antibiotic era. A lot of cases have been reported since it was originally described<sup>(3,4)</sup>, but nowadays only few cases are encountered due to the introduction of antibiotics. It was initially described to be associated with head trauma; however, it was later found that it may be caused by untreated or partially treated frontal sinusitis<sup>(5)</sup>. The infection erodes through the wall of infected frontal sinus, leading to the development of subperiosteal abscess, and extends intracranially if treated late. Pott's puffy tumour occurs in all age groups<sup>(6)</sup>, with patients ranging from 2 to 83 years of age, and it predominantly affects young males, with a male to female ratio of 9:1<sup>(7)</sup>. The disease is often polymicrobial, including streptococci, staphylococci and anaerobic bacteria as they develop at lower oxygen levels.

The signs and symptoms include frontal headache, fever, rhinorrhoea, doughy forehead swelling tender on palpation. Patients with intracranial extension may present with vomiting, altered mental status and signs

of meningism. Our patient presented with painful right frontal swelling persisting for one week and accompanied by purulent nasal discharge. However, there was no history of head trauma or rhinosinusitis symptoms. Diagnosis was based on a CT scan, which showed opacified frontal sinus with stranding and swelling of the overlying scalp. Other than that, the bone algorithm often demonstrates a defect in the anterior wall of the sinus, subperiosteal collection as well as intracranial extension<sup>(5)</sup>.

As in our case, the CT showed soft tissue density in the right frontal sinus extending to the frontal recess and sclerosis of the frontal sinus as well as bony defects of both anterior and posterior walls as a result of erosive complication of the lesion as in contrast with ordinary frontal sinusitis, which is usually not associated with erosive complications. Fortunately, there was no intracranial abscess collection.

The treatment of Pott's puffy tumour consists of medical and surgical approaches. Ibarra et al. suggested long-term antibiotic therapy of at least 8 weeks combined with surgical treatment to prevent further purulent complications<sup>(8)</sup>.

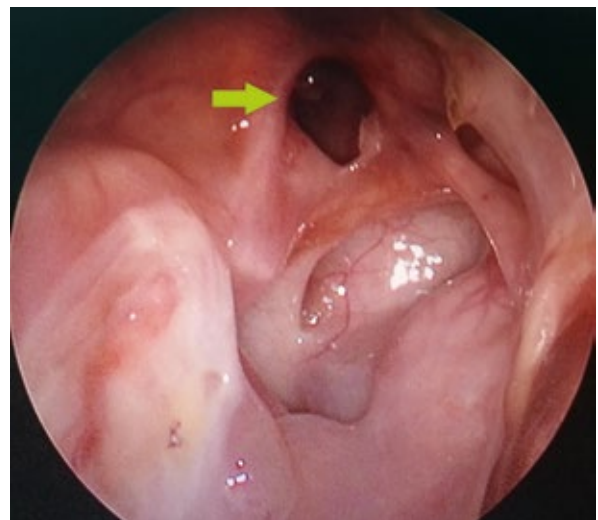


Fig. 4. Right frontal sinus, 3 weeks after the operation (arrow)

Our patient underwent functional endoscopic sinus surgery whereby large amounts of pus were found in the right nasal cavity at an early stage of procedure. Widening of the frontal recess revealed mucopyocele in the right frontal sinus.

## CONCLUSION

Early diagnosis and aggressive treatment of Pott's puffy tumour is crucial for the prevention of intracranial complications if treated late.

### Conflict of interest

*The authors do not declare any financial or personal links to other persons or organisations that could adversely affect the content of this publication or claim rights thereto.*

## Piśmiennictwo

1. Mortazavi MM, Khan MA, Quadri SA et al.: Cranial osteomyelitis: a comprehensive review of modern therapies. *World Neurosurg* 2018; 111: 142–153.
2. Babu RP, Todor R, Kasoff SS: Pott's puffy tumor: the forgotten entity. Case report. *J Neurosurg* 1996; 84: 110–112.
3. Tudor RB, Carson JP, Pulliam MW et al.: Pott's puffy tumor, frontal sinusitis, frontal bone osteomyelitis, and epidural abscess secondary to a wrestling injury. *Am J Sports Med* 1981; 9: 390–391.
4. Morgan PR, Morrison WV: Complications of frontal and ethmoid sinusitis. *Laryngoscope* 1980; 90: 661–666.
5. Sharma P, Sharma S, Gupta N et al.: Pott puffy tumor. *Proc (Bayl Univ Med Cent)* 2017; 30: 179–181.
6. Tsai BY, Lin KL, Lin TY et al.: Pott's puffy tumor in children. *Childs Nerv Syst* 2010; 26: 53–60.
7. Skomro R, McClean KL: Frontal osteomyelitis (Pott's puffy tumour) associated with *Pasteurella multocida* – a case report and review of the literature. *Can J Infect Dis* 1998; 9: 115–121.
8. Ibarra S, Aguirrebengoa K, Pomposo I et al.: [Osteomyelitis of the frontal bone (Pott's puffy tumor). A report of 5 patients]. *Enferm Infecc Microbiol Clin* 1999; 17: 489–492.