

Shall intraoperative OCT become standard equipment of modern operating room?



Dorota Maria Kaczmarek¹, Radosław Kaczmarek²

¹ Ophthalmology Clinical Centre Spektrum, Wrocław
Head: Prof. Maria Hanna Niżankowska, MD, PhD

² Department and Clinic of Ophthalmology, Wrocław Medical University
Head: Prof. Marta Misiuk-Hojko, MD, PhD

HIGHLIGHTS

To assess the role of intraoperative OCT in ophthalmic surgery, evaluate the current state-of-the-art and to show possible future directions in the field.

ABSTRACT

The role of intraoperative OCT (iOCT) in ophthalmic surgery is still a matter of active research and enhancements to integrative technologies. Further research is necessary to better define the specific applications of iOCT that impact surgical decision-making and as such help to achieve better patient outcomes, both in anterior and in posterior segment of the eye. In time to come advancements in integrative systems, OCT-friendly instrumentation, and software algorithms will most likely expand the horizon of iOCT even further.

Key words: intraoperative OCT, retinal surgery, corneal surgery, vitrectomy, keratoplasty

INTRODUCTION

If one was to name one diagnostic tool without which we cannot imagine modern ophthalmology it would most likely be optical coherent tomography (OCT): it is difficult to find one domain in which we do not use it nowadays to diagnose or monitor treatment. And yet, in its early days, OCT was perceived by some as an experimental method, most likely useful in research but not in everyday use [1]. Today we are witnessing the development of yet another application of OCT: ophthalmic surgery. Intraoperative OCT (iOCT) has been recently introduced in the operating theatre and as it's a relative novelty, questions arise concerning its real value and what benefit it can add.

CLINICAL APPLICATIONS

Intraoperative OCT is a non-contact imaging technology that allows to obtain live images of both anterior and posterior segment of the eye. Its first clinical use was reported in 2005 by Geerling et al. it was an anterior segment time-domain OCT [2]. Other first attempts were made with the use of handheld OCT (hh-OCT), mostly advantageous in intensive neonatal care units by Dayani et al. [3]. Application of hh-OCT, because of the image-acquisition procedure, was limited, as the images had low reproducibility and were much affected by motion artefacts. To overcome these problems, first commercially available systems with OCT mounted on the microscope were delivered: the Biotigen EnVisu (Biotigen, Research Triangle Park, NC/Leica, Wetzlar, Germany) and the Optovue iVue (Optovue, Fremont, CA, USA) [3, 4].

Today we have three FDA-approved systems commercially available: the Haag-Streit iOCT, Zeiss Rescan 700 and Leica EnFocus – all using swept-source OCT technique [5].

LITERATURE OVERVIEW

In 2011 PIONEER study results were published in “American Journal of Ophthalmology”, with spectral domain OCT mounted on microscope, and two treatment arms: anterior and posterior segment. It was a prospective, single-center, consecutive, case series. Surgeon feedback was recorded immediately after the surgical procedure to answer questions regarding iOCT utility. Duration of the study was 24 months, 531 eyes were enrolled, of which intraoperative imaging was successfully recorded in 518 cases.

The most common anterior segment surgical procedure was Descemet stripping automated endothelial keratoplasty (DSAEK, n = 135) and deep anterior lamellar keratoplasty (DALK) and vitrectomy with membrane peeling was the most common procedure for posterior segment surgery (n = 154). For anterior segment surgeons stated that information received from iOCT influenced surgical decision

69/144 (48%) lamellar keratoplasty cases and 63/146 (43%) in posterior segment – membrane peeling procedures. Acquisition of scans required 4.9 minutes per scan session on average and no adverse events specific for intraoperative imaging OCT were recorded.

IN ANTERIOR SEGMENT

In DSAEK the most evident advantage of iOCT was excellent visualization of fluid in the graft/host interface – it allowed monitoring graft apposition and so the procedure was continued until optimal fluid removal was achieved. For DALK intraoperative imaging facilitated evaluation of extent of trephination and residual bed of corneal stroma.

IN POSTERIOR SEGMENT

The most common indications for posterior segment surgery were epiretinal membrane (ERM), full-thickness macular hole (FTMH), vitreomacular traction (VMT), rhegmatogenous retinal detachment (RD), proliferative diabetic retinopathy (PDR), and vitreous hemorrhage (VH). The procedure performed most often was pars plana vitrectomy (ppV) but 15 eyes (out of 256) underwent scleral buckling. In cases of ERM surgery, iOCT was especially helpful with visualizing areas of already performed membrane peeling and revealing any residual membranes. Moreover, alterations in the outer retinal layers architecture were visualized, regarding the border between the ellipsoid zone and the retinal pigment epithelium (RPE) after peeling.

PEELING OF EPIRETINAL MEMBRANES

Modern retinal surgery often requires use of dyes such as brilliant blue and indocyanine green (ICG) to identify and enhance visualization of internal limiting membrane (ILM) and/or ERM and facilitate their peeling. It is not of no consequence for the retina however: there have been numerous reports considering potential retinal toxicity of ICG [6]. IOCT reduces or potentially even eliminates the need to stain membranes, especially when after initial peeling there are doubts whether whole ILM-ERM complex has been removed. Instead of restraining the surgeon might scan the retina which saves not only time but diminishes potential toxicity.

Similarly, in FTMH and VMT surgery, intraoperative changes in foveal architecture were noted, such as releasing tractions, improvement of ellipsoid zone / RPE border architecture and, in selected cases, identification of newly formed macular holes. With regards to retinal detachment surgery, following perfluorocarbon liquid exchange iOCT revealed potential residual fluid under neurosensory retina. In conclusion the authors stated that iOCT is a feasible option for both anterior and posterior segment ophthalmic

surgical procedures as it provided efficient imaging during surgery that allowed deeper understanding of intrasurgical ophthalmic anatomy.

In 2019 results of a study similar to the above mentioned were published, the DISCOVER study: prospective, multi-center, multi-surgeon consecutive surgical case series evaluating potential role of iOCT integrated with microscope; both for anterior and posterior segment [7]. The study included three microscope-integrated iOCTs: the Rescan 700 prototype (Carl Zeiss Meditec, Inc., Oberkochen, Germany), the EnFocus prototype (Biotigen / Leica Microsystems, Wetzlar, Germany) and a prototype internally developed at Cleveland Clinic Cole Eye Institute. Display systems were both head-up display and incorporated in microscope oculars and/or external screen. All systems being integrated with operating microscope enabled real-time OCT imaging intraoperatively and immediate feedback. Data obtained was reviewed during operation by the surgeon and, in selected cases, also independently reviewed postoperatively. A trained coordinator was present at the time of surgery and assisted with OCT image acquisition and collection of surgeon feedback and data.

The study involved a total of 837 eyes enrolled during 36 months. It was 244 eyes in the anterior segment arm and 593 eyes in the posterior segment arm. In 820 cases image acquisition was successful (97.8%), which meant that only 17 cases were not imaged (due to either system malfunction, poor view, decision of the surgeon and other).

Surgeon feedback was collected in form of a standardized questionnaire completed immediately after surgery for all cases, focusing on several specific areas of interest related to the microscope-integrated system and surgical procedures. Questions included value of iOCT added to the procedure and its impact on decision making. Additionally, questions concerning procedures such as membrane peeling, retinal detachment repair, DALK etc. were asked to assess procedure-specific value of iOCT.

For anterior segment (244 eyes) the most frequent indication for surgery were Fuch's endothelial dystrophy, bullous keratopathy, failed penetrating keratoplasty, and keratoconus. The most frequent procedure was lamellar keratoplasty – 193 cases: DSAEK performed in 123 eyes, followed by Descemet membrane endothelial keratoplasty (DMEK) in 60 eyes, and DALK in 10 eyes; other procedures were less common. In 216 cases (88.5%) surgeons reported that iOCT provided them with valuable feedback. The most often mentioned was evaluation of draft/host apposition and assessment of the residual fluid in DSAEK and DMEK procedures. Also, the graft orientation and evaluation of the needle depth within the cornea to form the big bubble were commonly reported.

In conclusion, the DISCOVER iOCT study showed both relevant feasibility and usefulness based on the impact on

surgical decision making reported by surgeons. This large-scale study confirmed similar findings from other studies on the value and impact of iOCT in ophthalmic operating theatre.

Worth mentioning is the use of iOCT for gene therapy. In recent years new hope for better vision was offered to patients with inherited retinal disorders (IRD) due to mutation in both copies of *RPE65* gene. In such case subretinal administration of voretigene neparvovec (Luxturna) can offer sufficient visual acuity and visual field improvement. Drug admission requires creation of retinal bleb which serves as a reservoir for human RPE65 cDNA carried within an adeno-associated viral (AAV) vector. IOCT greatly facilitates this task and helps to make sure that this drug, which costs around 850,000 \$, reaches its proper place [8]. An interesting summary of surgeons' opinions was published in 2018 as a Clinical Update in EyeNet Magazine by American Academy of Ophthalmology (AAO). Annie Stuart interviewed Justis P. Ehlers, Adreas K. Lauer and Robert MacLaren, all experienced ophthalmic surgeons, and all expressing their strong opinion that even though they may have been skeptical at first, they now regard iOCT as indispensable in their everyday practice – though they admit that it still requires technical improvements such as better visualization or eye-tracking systems or non-shadowing instruments that do not obscure view of the retina. Despite these shortcomings, Ehlers believes that iOCT is an instrument that, in time, will become a standard feature in modern operating theatres as it adds information that the surgeon otherwise wouldn't have and that can change surgical perspective [9].

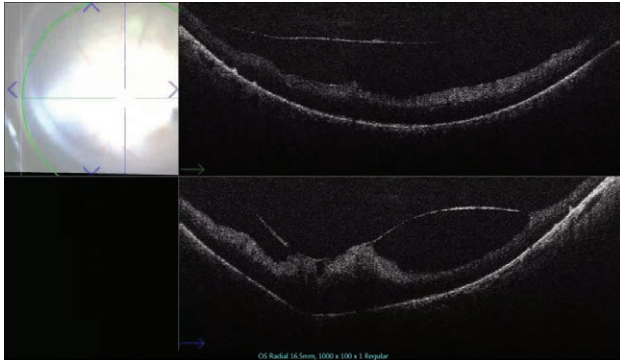
CONCLUSION

IOCT is now changing surgical practices. In both the DISCOVER and PIONEER studies, iOCT impacted surgical decision-making and altered the surgical approach in a significant percentage of cases – as we know from various studies, it may be about 20% to 35% of cases. There might be less need for peeling the membranes, or on the contrary – immediate indications to better attach the transplanted tissues – all these maneuvers could change how the patient does postoperatively [10–12]. From our own experience, in figure 1, we show the advantage of iOCT visualisation when peeling proliferative diabetic membranes.

What must be mentioned is that this technology, though obviously advanced, still requires further research and development. One area that is in need of improvement is notable shadowing and light scattering that occurs in posterior segment surgery due to metallic instruments. This obstacle removed, it will facilitate many surgical stages i.e., peeling of retinal membranes should be easier and smooth procedure. Shadowing of the forceps during ILM peeling

FIGURE 1

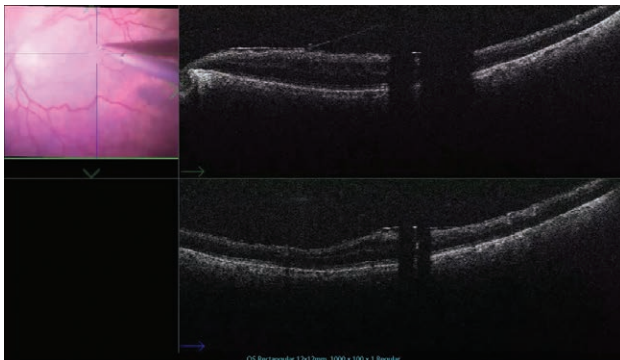
With proliferative diabetic retinopathy iOCT guided membrane removal makes the procedure much safer for the patient and much efficient for the surgeon (Leica EnFocus).



performed by the author of this manuscript (RK) is shown in figure 2.

FIGURE 2

ILM-peeling assisted with iOCT. Visualisation of membrane helps creating the flap but shadowing of the instrument (surgical forceps) is a challenge to overcome (Leica EnFocus).

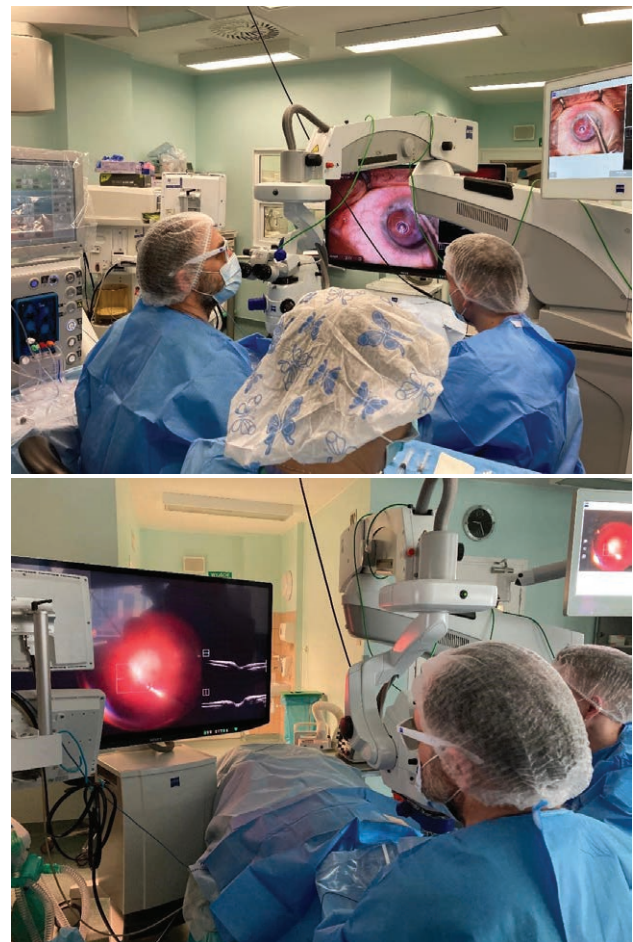


Under construction are now more advanced software platforms, automated instrument tracking, better yet visualization, deeper penetration of OCT light beam, voice-command and heads up display [13]. All these no doubt help the surgeon but, what is worth mentioning, is the fact that integration of iOCT into the surgical theater may also have an impact on the entire crew: better understanding of the

procedure helps to more engage the assistant personnel and of course is an immense value for the learning curve. Intraoperative OCT, though meaning significant expense, appears to be of benefit for a surgeon as it frequently offers key information regarding the anatomy of treated tissues, details not otherwise seen. This may impact surgical decision-making process and make the surgery more beneficial and safe for the patient. Authors of this manuscript (one of them shown in action in figures 3 and 4 – RK) share this opinion and feel the answer to the question stated in article's title will be "yes" – if not now, then most definitely so in the near future.

FIGURE 3, 4

iOCT with 3D viewing system (Zeiss Rescan 700) in the operating theatre.



Figures: authors' own resources.

CORRESPONDENCE**Dorota Maria Kaczmarek, MD, PhD**

Ophthalmology Clinical Centre Spektrum

53-334 Wrocław, ul. Zaolziańska 4

e-mail: dorota.kaczmarek@spektrum.wroc.pl

ORCIDDorota Maria Kaczmarek – ID – <http://orcid.org/0000-0002-0397-1115>Radosław Kaczmarek – ID – <http://orcid.org/orcid.org/0000-0001-9920-4406>**References**

- Ehlers JP, Dupps WJ, Kaiser PK et al. The prospective intraoperative and perioperative ophthalmic imaging with optical CoherEncE TomogRaphy (PIONEER) study: 2-year results. *Am J Ophthalmol.* 2014; 158(5): 999-1007. <http://doi.org/10.1016/j.ajo.2014.07.034>.
- Geerling G. Intraoperative 2-Dimensional Optical Coherence Tomography as a New Tool for Anterior Segment Surgery. *Arch Ophthalmol.* 2005; 123(2): 253. <http://doi.org/10.1001/archophth.123.2.253>.
- Dayani PN, Maldonado R, Farsiu S et al. Intraoperative use of handheld spectral domain optical coherence tomography imaging in macular surgery. *Retina.* 2009; 29(10): 1457-68. <http://doi.org/10.1097/IAE.0b013e3181b266bc>.
- Carrasco-Zevallos OM, Viehland Ch, Keller B et al. Review of intraoperative optical coherence tomography: technology and applications [Invited]. *Biomed Opt Express.* 2017; 8(3): 1607. <http://doi.org/10.1364/boe.8.001607>.
- Lauer A, Vasconcelos H. Intraoperative OCT: an emerging technology. *Eyenet Magazine.* 2018; 31-3.
- Gandorfer A, Haritoglou C, Kampik A. Toxicity of indocyanine green in vitreoretinal surgery. *Dev Ophthalmol.* 2008; 42: 69-81. <http://doi.org/10.1159/000138974>.
- Ehlers JP, Modi YS, Pecun PE et al. The DISCOVER Study 3-Year Results: Feasibility and Usefulness of Microscope-Integrated Intraoperative OCT during Ophthalmic Surgery. *Ophthalmology.* 2018; 125(7): 1014-27. <http://doi.org/10.1016/J.OPHTHA.2017.12.037>.
- Gao J, Hussain RM, Weng CY. Voretigene neparvovec in retinal diseases: A review of the current clinical evidence. *Clin Ophthalmol.* 2020; 14: 3855-69. <http://doi.org/10.2147/OPHTH.S231804>.
- Ehlers JP. Intraoperative optical coherence tomography: Past, present, and future. *Eye (Basingstoke).* 2016; 30(2): 193-201. <http://doi.org/10.1038/eye.2015.255>.
- Ehlers JP, Uchida A, Srivastava SK et al. Predictive model for macular hole closure speed: Insights from intraoperative optical coherence tomography. *Transl Vis Sci Technol.* 2019; 8(1): 18. <http://doi.org/10.1167/tvst.8.1.18>.
- Patel AS, Goshe JM, Srivastava SK et al. Intraoperative Optical Coherence Tomography-Assisted Descemet Membrane Endothelial Keratoplasty in the DISCOVER Study: First 100 Cases. *Am J Ophthalmol.* 2020; 210: 167-173. <http://doi.org/10.1016/j.ajo.2019.09.018>.
- Khan M, Srivastava SK, Reese JL et al. Intraoperative OCT-assisted Surgery for Proliferative Diabetic Retinopathy in the DISCOVER Study. *Ophthalmol Retina.* 2018; 2(5): 411-7. <http://doi.org/10.1016/j.oret.2017.08.020>.
- Ehlers JP, Srivastava SK, Feiler D et al. Integrative advances for OCT-guided ophthalmic surgery and intraoperative OCT: Microscope integration, surgical instrumentation, and heads-up display surgeon feedback. *PLoS One.* 2014; 9(8): e105224. <http://doi.org/10.1371/journal.pone.0105224>.

Authors' contributions:

Dorota Maria Kaczmarek: idea of the manuscript, collecting the literature, preparation of the manuscript; Radosław Kaczmarek: edition of the manuscript, photos from the OR.

Conflict of interest:

None.

Financial support:

None.

Ethics:

The content presented in the article complies with the principles of the Helsinki Declaration, EU directives and harmonized requirements for biomedical journals.