

Endogenous endophthalmitis with iridolenticular involvement – a case report and systematic review



Ru Jian Jonathan Teoh, Yin Peng Lai, Rohanah Alias, Nor Azita Ahmad Tarmidzi, Swee Ying Choo

Department of Ophthalmology, Hospital Kuala Lumpur
Head of Department: YBrs. Dr. Jamalia binti Rahmat

HIGHLIGHTS

Endogenous endophthalmitis with involvement of the iris and crystalline lens is an uncommon presentation. *Candida albicans* was identified as the main causative organism, and the main associated risk factors being intravenous drug use and a history of invasive medical procedures. Early vitrectomy and lensectomy have been associated with a favourable visual prognosis.

ABSTRACT

Endogenous endophthalmitis (EE) is a sight- and life-threatening disease. EE associated with the involvement of iris and crystalline lens is an uncommon presentation. We reported a case of EE with iridolenticular involvement in a 19-year-old woman with a history of candidemia. Therapeutic vitrectomy with lensectomy was performed, and the patient was treated with intravitreal meropenem and amphotericin B. She was discharged with 6 weeks of oral fluconazole. At follow-up, her vision was 20/60 with aphakic correction. We also conducted a systematic review of the current literature to analyse the clinical features, risk factors, and outcomes of EE with iridolenticular involvement. The systematic review included 10 cases, and found that *Candida albicans* was the main causative organism. Intravenous drug use and a history of invasive procedures were important risk factors. 70% of the cases required vitrectomy and lensectomy. Post treatment, majority of the cases (80%) had a good visual prognosis of better than 20/60. Our results suggested that in cases of EE with iridolenticular involvement, early surgical removal of the infectious nidus via vitrectomy and lensectomy is recommended for a good visual outcome. A high level of suspicion is crucial in diagnosing the disease, and early aggressive therapy is fundamental.

Key words: endogenous endophthalmitis, lens abscess, lenticular abscess, iridolenticular abscess, *Candida*

INTRODUCTION

Endogenous endophthalmitis (EE) is a sight-threatening intraocular inflammation that results from the hematogenous dissemination of infective organism from distant foci [1]. EE accounts for 2–15% of all cases of endophthalmitis [1–3]. Previous studies found that fungal organisms account for 11.1% to 17.54% of the cases, which majority of the cases were caused by *Candida albicans* [4, 5]. Classical presentations of EE due to *Candida* species are vitritis and white, fluffy, well-circumscribed retinal lesions that may protrude into the vitreous giving an appearance of “puff ball” abscesses [1, 3]. Iris and lens abscesses are uncommon presentations, which may be associated with a history of ocular trauma, ocular surgery, and metastatic infection [6]. We reported a case of *Candida* endophthalmitis with iridolenticular abscess. We also performed a systematic review of literature to identify cases of EE with iridolenticular involvement, and described their clinical features, risk factors, and outcome. To our limited knowledge, this is the first systematic review of EE with iridolenticular involvement in adults.

CASE REPORT

A 19-year-old Bangladeshi female was referred to the eye clinic of Hospital Kuala Lumpur with a one-month history of right eye painful blurring of vision. She had an underlying well-controlled asthma. 2 months ago, she had a one-and-a-half-month hospital admission for intracranial bleed after a road traffic accident. Her condition was complicated with nosocomial infection, which blood cultures grew extended-spectrum beta lactamase (ESBL) – producing *Klebsiella pneumoniae* and *Candida albicans*. She had completed intravenous ertapenem and fluconazole for a week and was discharged on oral antibiotics and antifungal for a month.

She was initially diagnosed with low-grade anterior uveitis in the right eye and topical corticosteroid was initiated in a different eye centre. Subsequently, she developed hypopyon on the next day, and topical levofloxacin was commenced. She was then referred to our centre for further management. However, the patient defaulted and presented 3 weeks later to our centre. At the time of assessment, she had developed dense vitritis. Vision was hand movement OD with positive relative afferent pupillary defect, with an intraocular pressure of 36 mmHg. Slit-lamp examination revealed a hazy cornea and dense fibrin in the anterior chamber covering the pupil with 4+ cells and flare. Anterior chamber paracentesis and vitreous aspiration of the right eye were performed and intravitreal vancomycin (2 mg/0.1 ml), ceftazidime (2 mg/0.1 ml) and amphotericin B (5 µg/0.1 ml) were administered. Blood cultures were obtained and she was admitted to the hospital for initiation

of intravenous ertapenem and fluconazole, with reference to her previous blood cultures and sensitivity results. All cultures taken during the admission were negative. The patient was referred to an infectious disease specialist. No disseminated infection was found in other organs, such as the lungs, liver, spleen, and kidneys.

After 2 courses of intravitreal vancomycin, ceftazidime, and amphotericin B 48-hours apart, there was improvement in the severity of vitritis based on ultrasound B-scan. However, the anterior segment demonstrated worsening signs, with a nodular elevation in the iris from six to nine o'clock and shallowing of the anterior chamber with iridocorneal touch (fig. 1). There was iris neovascularization. Ultrasound biomicroscopy (UBM) showed an iridolenticular abscess with vitritis (fig. 2).

The patient underwent diagnostic and therapeutic pars plana vitrectomy combined with lensectomy, and excision of the involved iris. Intraoperatively, there were white fluffy lesions resembling fungal balls in the vitreous, cyclitic membrane, and whitish exudates over the pars plana. White fluffy lesions were also found in the crystalline lens. There were perivascular exudates on the retina with generalized vasculitis, retinitis, and two retinal holes at three o'clock, anterior to the equator. The choroid was not involved. Intravitreal meropenem (500 µg/0.1 ml) and amphotericin B (5 µg/0.1 ml) were administered. Vitreous culture was positive for *Candida albicans*, which was sensitive to fluconazole and voriconazole. Chronic granulomatous inflammation of the iris and fungal infection of the lens were demonstrated by histopathology. The patient was discharged with oral fluconazole in addition to topical amphotericin B, topical fluconazole, and topical prednisolone. Upon 6 weeks follow-up after treatment, the patient's visual acuity in the right eye with aphakic correction was 20/60.

FIGURE 1

Anterior segment photo of the right eye demonstrated nodular elevation in the iris from six to nine o'clock, with dense fibrin overlying the pupil.

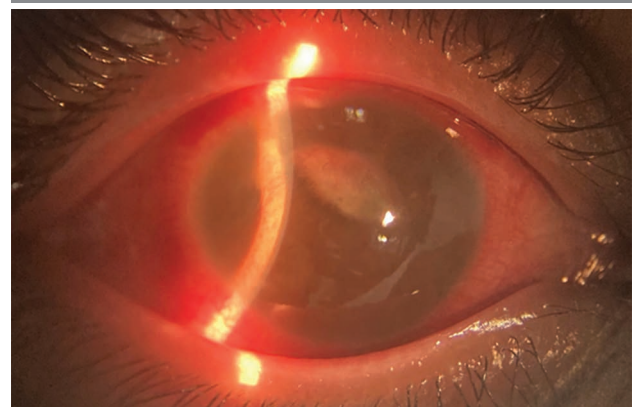
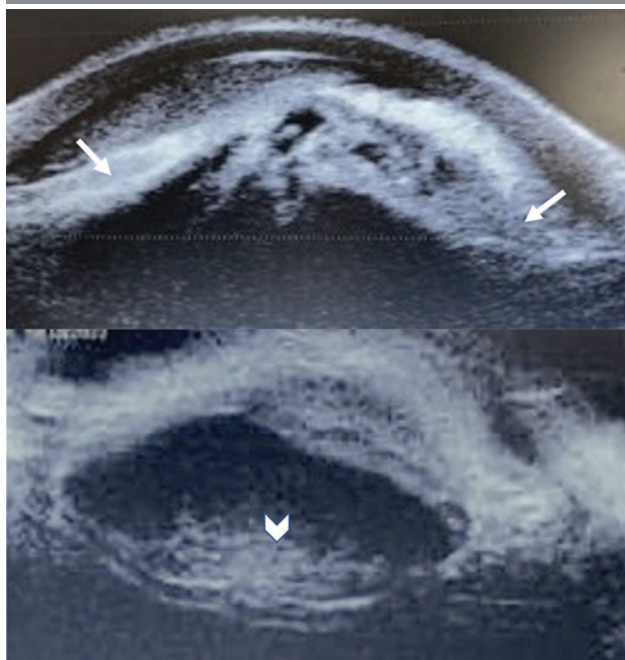


FIGURE 2

UBM of the right eye found hyperechoic lesion seen behind the iris at nine o'clock position, resembling a collection (arrow); and hyperechoic lesion in the crystalline lens, resembling an active inflammation (arrowhead).



Slit-lamp examination showed a quiet anterior chamber and vitreous cavity, with resolved vasculitis and retinitis. There was no involvement of the fellow eye throughout the course of the disease.

SYSTEMATIC REVIEW

Method

We performed a systematic review of PubMed and Embase databases till December 18, 2022 according to the PRISMA guidelines (Table S1) [7]. Search terms (both free text and medical subject headings thesaurus) for endophthalmitis, iris, lens, and abscess were combined (Supplementary Digital Content S1). The search was limited to human studies, with no language restriction. Reference lists of the retrieved articles were manually searched. EndNote database was used to import and manage abstracts and full texts. Duplicate records were removed. Two investigators (R.J.J.T. and Y.P.L.) independently searched published articles, screened titles and abstracts, and identified potential articles. Eligibility queries were resolved by discussion. The search was repeated to ensure accuracy and completeness.

Case reports, case series, and observational studies describing clinical features, risk factors, and outcome of EE with iridolenticular involvement were included in the systematic review.

Studies of exogenous endophthalmitis and without clinical features or outcome were excluded.

The demographic data, risk factors, clinical features, treatment, and outcomes were recorded. The definition of a favourable visual outcome was defined as a best corrected visual acuity of better than 20/400 [8].

Informed consent was obtained from the patient in our case report.

RESULTS

We identified 50 citations on Embase and 43 citations on PubMed, of which nine meet the inclusion criteria [9–17]. We included our case report in the following discussion, totalling up to 10 cases of EE with iridolenticular involvement in adults (fig. 3).

We analysed the demographics, predisposing medical conditions, cultures, concurrent focus of infection, treatment, and the final vision of the 10 patients (including our case) (tab. 1). The case reports included 6 women and 4 men, with a median age of 33 years (range 14–72). There were 3 patients with a history of intravenous drug use (IVDU) [10, 12, 17], 3 patients with a history of invasive procedure [11, 13, 15], and 2 patients with a history of *Candida albicans* sepsis [16], our case. All 10 cases had positive eye specimen cultures, which 6 out of the 10 cases were attributed to *Candida albicans*. Seven of the cases had negative blood cultures. Three cases were found to have a concurrent focus of infection. Majority of the cases required pars plana vitrectomy (70%), and all cases were treated with systemic antibiotics. Eight cases (80%) achieved a favourable visual outcome post treatment.

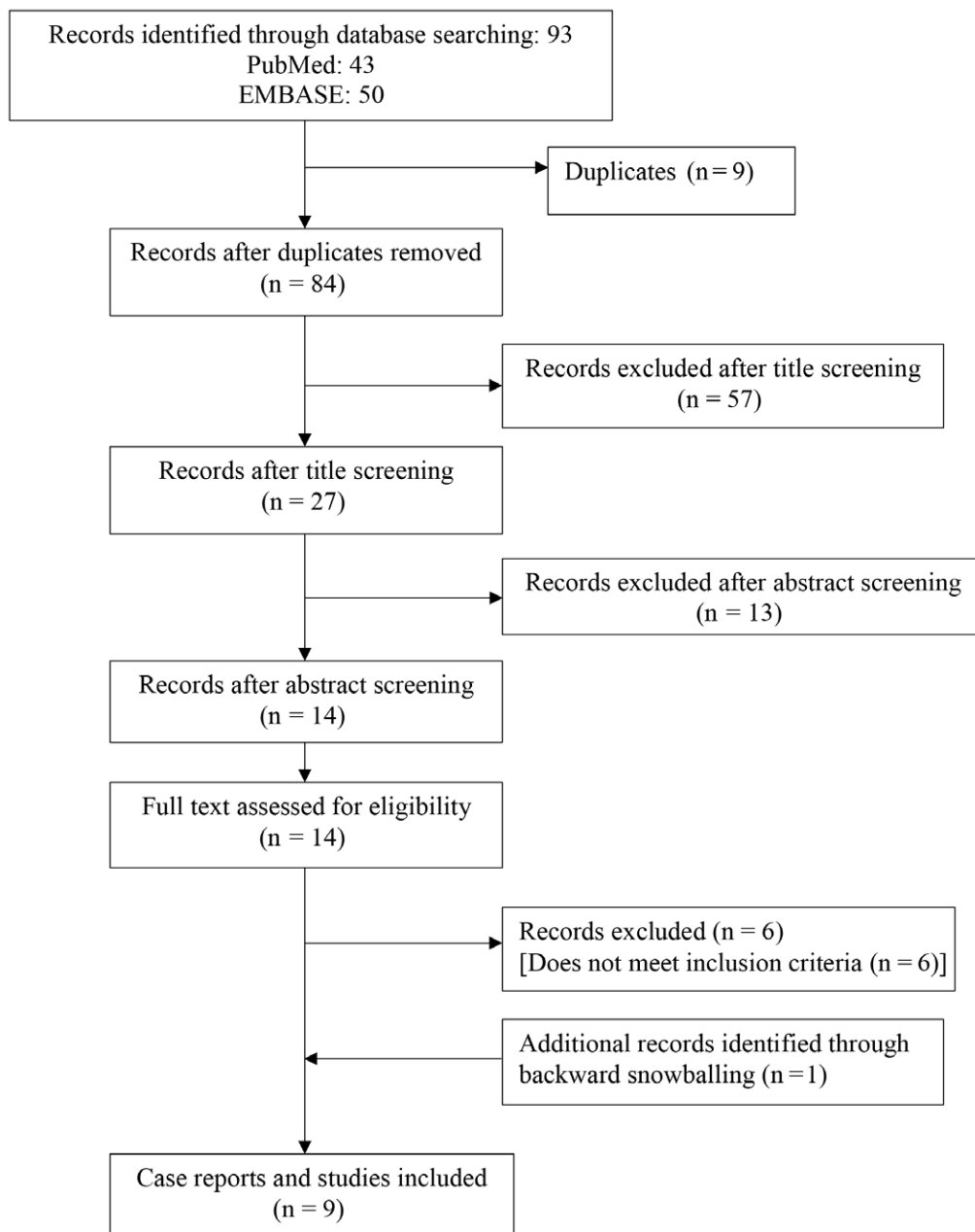
DISCUSSION

Iridolenticular abscess secondary to EE is a rare presentation that poses a diagnostic and therapeutic challenge. As EE results from the hematogenous spread of infective organisms, it primarily affects highly vascularized areas, such as the choroidal space and ciliary body. Subsequently, it will progress to affect the retina and the vitreous space. In our case, it is likely that *C. albicans* spread into the ciliary body, followed by extension into the iris and then the body of the crystalline lens, leading to the formation of an iridolenticular abscess. The crystalline lens is an avascular, protein-rich environment, which the reach and penetration of antibiotics is difficult, leading to inadequate treatment.

From the systematic review, there was no age predilection demonstrated. The age range of the patients were 14 to 72 years old. IVDU was found to be a risk factor in 3 cases in this review [10, 12, 17]. IVDU carries a risk of introducing organisms into the bloodstream, which may result in the development of EE. The incidence of drug use-associated

FIGURE 3

Study selection process.



EE had increased four-fold from 0.08 per 100,000 in 2003 to 0.32 per 100,000 in 2016 [18]. This also corresponded to a study by Patel et al., which found that more than half of the patients with EE had a history of IVDU, and had poor visual prognosis despite treatment [19]. Detailed history and examination are necessary in patients with IVDU for early detection and management of EE.

Three patients had invasive procedures performed prior to the diagnosis of EE with iridolenticular involvement [11, 13, 15]. All 3 cases mentioned had bacterial EE, which organisms were *Enterobacter agglomerans*, *Streptococcus intermedius*, and *Staphylococcus aureus* [11, 13, 15]. *Entero-*

bacter is a Gram-negative commensal bacterium present in the human gut [15]. *Staphylococcus aureus* is a Gram-positive bacteria which was found colonizing the human skin, while *Streptococcus intermedius* is a Gram-positive bacteria found as part of the normal flora in the oropharynx [20, 21]. Previous studies reported an association of EE with gastrointestinal, genitourinary, and dental procedures [22]. A history of invasive procedures poses a risk of inoculation of pathogens into the bloodstream crossing the blood–retina barrier and causes EE.

Two of the cases in this review (Monshizadeh et al. [16] and current case) had a history of *C. albicans* sepsis 2 months

TABLE 1

Characteristics of the cases included in the systematic review.

Author, year	Sex	Age	Predisposing medical conditions	Positive vitreous/aqueous culture	Positive blood culture	Concurrent focus of infection	Pars plana vitrectomy and lensectomy	Systemic treatment	Final vision
Budmann et al., 2021 [9]	female	27	HIV syphilis	<i>Candida albicans</i>	negative	none	yes	Intravenous C-penicillin for 2 weeks. Oral fluconazole for 6 months	20/20
Pierce et al., 2016 [10]	female	30	IVDU hepatitis C	<i>Candida albicans</i>	negative	axillary abscess	yes, with iridectomy	Intravenous vancomycin, cefepime, voriconazole. Discharged with oral voriconazole for 4 weeks	20/20 with +12D contact lens
Mali et al., 2015 [13]	female	50s	one week after routine dental cleaning	<i>Streptococcus intermedius</i>	<i>Streptococcus intermedius</i>	none	no, did extraction of iris granuloma	Sulfamethoxazole and trimethoprim and clindamycin for 2 weeks	20/25
Braich et al., 2011 [14]	male	33	nil	<i>Candida albicans</i>	negative	none	yes	Intravenous amphotericin, oral fluconazole	20/50
Cumurcu et al., 2010 [11]	female	65	two weeks after an Intramuscular injection	methicillin-sensitive <i>Staphylococcus aureus</i>	methicillin-sensitive <i>S. aureus</i>	gluteal abscess	no	Intravenous piperacillin-tazobactam for 2 weeks	20/60
Ramonas and Freilich, 2003 [12]	male	37	IVDU	methicillin-sensitive <i>S. aureus</i>	methicillin-sensitive <i>S. aureus</i>	bacterial endocarditis	no	Intravenous antibiotics for 2 weeks	20/25
Monshizadeh et al., 2003 [16]	female	14	On immunosuppressant post cardiac transplantation. Hypogammaglobulinemia Presence of indwelling catheter. History of <i>C. albicans</i> urosepsis 2 months before presentation	<i>Candida albicans</i>	negative	none	yes, with excision of involved iris	Intravenous amphotericin B and 5-flucytosine for 8 weeks	20/50
Fahey et al., 1999 [17]	male	32	IVDU hepatitis C	<i>Candida albicans</i>	negative	none	yes	Oral fluconazole 400 mg o.d., topical miconazole 1%	phthisical, eviscerated
Zeiter et al., 1989 [15]	male	72	one day after internal hemorrhoidal ligation	<i>Enterobacter agglomerans</i> (<i>Erwinia species</i>)	negative	none	yes	Intravenous gentamicin and cefoperazone	10/400
Current report	female	19	history of <i>C. albicans</i> sepsis 2 months before presentation	<i>Candida albicans</i>	negative	none	yes, with excision of involved iris	Oral fluconazole	20/60 with +10 correction

HIV – human immunodeficiency virus; IVDU – intravenous drug use.

before the presentation of EE. In the former case, the patient was treated with 10 days of intravenous amphotericin B for *C. albicans* urosepsis. Repeated cultures were negative. The patient in our case completed intravenous fluconazole for a week followed by oral fluconazole for a month. According

to the 2016 Infectious Diseases Society of America (IDSA) guideline, a 2-week duration of systemic therapy after documented clearance of *Candida* from the bloodstream was recommended in patients with candidemia without metastatic complications [23].

Despite the completion of systemic antifungal therapy, there is still a risk of hematogenous dissemination of *Candida* cells to deep-seated organs. *Candida* can form biofilms on medical devices such as vascular catheters, stents, and endotracheal tubes, which contributed to its prevalence in nosocomial infections [24]. This was evident in both the cases with a history of *C. albicans* infection, which the patient in Monshizadeh et al. case report had an indwelling catheter, and the patient in this current case report had a history of long hospitalization [16]. Biofilm formation was linked to the virulence traits of *Candida*, namely dimorphism and phenotypic switching, which are capable of reducing the susceptibility of the organism to the host immune system and antifungal therapy [24, 25]. This could lead to inadequate eradication of *Candida* and subsequently resulted in *Candida* endophthalmitis.

All of the patients had positive eye specimen cultures. There were 6 patients with yeast endophthalmitis, 3 with Gram-positive bacterial endophthalmitis, and 1 with Gram-negative bacterial endophthalmitis. Seven of the cases included in this review had negative systemic cultures [9, 10, 14–17]. As postulated in a previous study, transient bacteraemia and fungemia could be the cause of EE [26]. Although any organism found in the bloodstream can result in EE, certain organisms are more frequently isolated, including *Candida* spp., *Klebsiella* spp. and *S. aureus* [22]. Blood cultures obtained from patients with deep-seated infection often yield a negative result, as the causative organism has been cleared from the bloodstream at the time of culture collection [27]. It is important to search for additional infectious foci once the diagnosis of EE is established. In this review, 30% of the cases had other concurrent infections, i.e., axillary abscess, gluteal abscess, and bacterial endocarditis. These could be the primary foci of the EE. It is common to have no primary focus of infection identified, as a previous study by Binder et al. found that 42% of bacterial EE and 44% of *Candida* EE had no other foci of infection identified [26]. However, it is still important to look for the primary focus of infection, as the management and duration of treatment would be different based on the underlying source of infection.

All *Candida* endophthalmitis cases with iridolenticular involvement underwent vitrectomy with lensectomy, whereas Gram-positive endophthalmitis cases with iridolenticular involvement were treated with topical, intravitreal, and systemic antibiotics. *Candida* endophthalmitis typically has a subacute presentation and it may remain clinically silent until late in the disease. Transient candidemia might have been cleared from the bloodstream, but there is a risk of hematogenous, deep-seated infection, such as EE with abscess formation. Such cases would require surgical intervention [28]. A systematic review by Breazzano et al. found that *Candida* endophthalmitis responded well with systemic antibiotics, with a significant greater association found be-

tween medical management only and successful treatment [29]. However, our study found that vitrectomy with lensectomy was crucial in treating cases with iridolenticular involvement for a good outcome.

On the other hand, vitrectomy is often necessary in treating bacterial EE, as it frequently leads to severe endophthalmitis. A review of 342 cases of bacterial EE demonstrated that vitrectomy was associated with a better visual prognosis and a reduced occurrence of eviscerations or enucleations. In our study, 1 patient with bacterial EE with iridolenticular involvement underwent vitrectomy [15], and another patient had extraction of involved iris [13]. One of the patients successfully recovered without surgical vitrectomy [12]. Due to the limited number of reported cases of bacterial EE with iridolenticular involvement, it could not be concluded that medical management only would be sufficient. Further research is needed to address this matter.

The visual outcome of the cases included in this review was generally good, in which eight eyes had achieved a final visual acuity of better than 20/60. A case by Zeiter et al. had a final visual acuity of 10/400 [15]. It was found that anterior vitrectomy with intravitreal, subconjunctival, and systemic antibiotics had failed to control the infection [15]. Pars plana vitrectomy with additional intravitreal antibiotics was required to successfully suppress the infection [15]. The case reported by Fahey et al. demonstrated diagnostic difficulties of *Candida* endophthalmitis, in which the patient first presented with panuveitis with negative vitreous culture from diagnostic vitrectomy [17]. The patient recommenced heroin and defaulted follow-up [17]. Six weeks later, his condition had worsened and it was complicated with inoperable subtotal retinal detachment, which the affected eye became phthisical and was eviscerated [17]. Both cases demonstrated that early diagnosis and surgical debulking of the vitreous of virulent organisms were necessary in EE with iridolenticular involvement.

CONCLUSION

This systematic review is the first of its kind to elicit the risk factors, clinical presentations, microbiologic spectrum and treatment of EE with iridolenticular involvement. The available information from the current systematic review is limited since it depends on individual case reports. Despite the limitation, it is evident that in EE with iridolenticular involvement, early surgical removal of the infectious nidus via vitrectomy and lensectomy is recommended as the clearance of the causative organism would reduce the microbial load and improve the reach of antibiotics in the eye. A high level of suspicion is essential in diagnosing the condition as early aggressive therapy is important for a good visual outcome.

Figures: authors' own resources.

CORRESPONDENCE**dr. Ru Jian Jonathan Teoh**

Department of Ophthalmology, Hospital Kuala Lumpur,
50586, Kuala Lumpur, Malaysia
phone: +603-2615 6802 / 1455
fax: +603-2615 5511
e-mail: jonathan.teoh26@gmail.com

ORCID

Ru Jian Jonathan Teoh – ID – <http://orcid.org/0000-0001-7252-5429>

References

1. Sadiq MA, Hassan M, Agarwal A et al. Endogenous endophthalmitis: diagnosis, management, and prognosis. *J Ophthalm Inflamm Infect.* 2015; 5(1): 32.
2. Kernt M, Kampik A. Endophthalmitis: Pathogenesis, clinical presentation, management, and perspectives. *Clin Ophthalmol.* 2010; 4: 121-35.
3. Haseeb AA, Elhousseiny AM, Siddiqui MZ et al. Fungal Endophthalmitis: A Comprehensive Review. *JoF.* 2021; 7(11): 996.
4. Lim HW, Shin JW, Cho HY et al. Endogenous endophthalmitis in the Korean population: A Six-Year Retrospective Study. *Retina.* 2014; 34(3): 592-602.
5. Sharma S, Padhi TR, Basu S et al. Endophthalmitis patients seen in a tertiary eye care centre in Odisha: a clinico-microbiological analysis. *Indian J Med Res.* 2014; 139(1): 91-8.
6. Kaur K, Gurnani B. Lens Abscess. In: StatPearls [Internet]. Treasure Island (FL): StatPearls Publishing; 2022. Available from: <http://www.ncbi.nlm.nih.gov/books/NBK587445/>.
7. Page MJ, McKenzie JE, Bossuyt PM et al. The PRISMA 2020 statement: an updated guideline for reporting systematic reviews. *BMJ.* 2021; 372: n71.
8. Lingappan A, Wykoff CC, Albin TA et al. Endogenous Fungal Endophthalmitis: Causative Organisms, Management Strategies, and Visual Acuity Outcomes. *Am J Ophthalmol.* 2012; 153(1): 162-166.e1.
9. Budmann GA, Parisi FB, Ortiz GB et al. Anterior uveal fungal abscess in an HIV positive patient. *Arch Soc Esp Oftalmol (Engl Ed).* 2021; 96(7): 388-91.
10. Pierce J, Warriar N, Antonopoulos C et al. Iris abscess a rare presentation of intravenous drug abuse associated Candida endophthalmitis. *Am J Ophthalmol Case Rep.* 2016; 4: 27-9.
11. Cumurcu T, Demirel S, Doganay S. Iris abscess as an unusual presentation of endogenous endophthalmitis after intramuscular injection. *Ocul Immunol Inflamm.* 2010; 18(3): 190-1.
12. Ramonas KM, Freilich BD. Iris abscess as an unusual presentation of endogenous endophthalmitis in a patient with bacterial endocarditis. *Am J Ophthalmol.* 2003; 135(2): 228-9.
13. Mali JO, Falk NS, Mali YP et al. Endogenous endophthalmitis with iris abscess after routine dental cleaning. *JAMA Ophthalmol.* 2015; 133(5): 616-7.
14. Braich PS, Chang JS, Albin TA et al. Irido-lenticular abscess as the initial sign of Candida albicans endogenous endophthalmitis. *Ophthalmic Surg Lasers Imaging.* 2011; 42: e107-9.
15. Zeiter JH, Koch DD, Parke DW et al. Endogenous Endophthalmitis With Lenticular Abscess Caused by Enterobacter Agglomerans (Erwinia Species). *Ophthalmic Surg Lasers Imaging.* 1989; 20(1): 9-9.
16. Monshizadeh R. Isolated Anterior Uveitis as the Initial Sign of Systemic Candidemia. *Arch Ophthalmol.* 2003; 121(1): 137.
17. Fahey DK, Fenton S, Cahill M et al. Candida endophthalmitis: A diagnostic dilemma. *Eye.* 1999; 13(4): 596-8.
18. Mir TA, Papudesu C, Fang W et al. Incidence of Drug Use-Related Endogenous Endophthalmitis Hospitalizations in the United States, 2003 to 2016. *JAMA Ophthalmol.* 2021; 139(1): 18.
19. Patel SN, Rescigno RJ, Zarbin MA et al. Endogenous endophthalmitis associated with intravenous drug abuse. *Retina.* 2014; 34(7): 1460-5.
20. Ng KWP, Mukhopadhyay A. Streptococcus constellatus bacteremia causing septic shock following tooth extraction: a case report. *Cases J.* 2009; 2(1): 6493.
21. Taylor TA, Unakal CG. Staphylococcus aureus. In: StatPearls [Internet]. StatPearls Publishing; 2021.
22. Keynan Y, Finkelman Y, Lagacé-Wiens P. The microbiology of endophthalmitis: global trends and a local perspective. *Eur J Clin Microbiol Infect Dis.* 2012; 31(11): 2879-86.

23. Pappas PG, Kauffman CA, Andes DR et al. Clinical Practice Guideline for the Management of Candidiasis: 2016 Update by the Infectious Diseases Society of America. *Clinical Infectious Diseases*. 2016; 62(4): e1-50.
24. Khan MSA, Ahmad I, Aqil F et al. Virulence and Pathogenicity of Fungal Pathogens with Special Reference to *Candida albicans*. In: Ahmad I, Owais M, Shahid M et al. (ed). *Combating Fungal Infections*. [Internet]. Springer, Berlin, Heidelberg 2010: 21-45. Online: http://link.springer.com/10.1007/978-3-642-12173-9_2.
25. Tumbarello M, Posteraro B, Trecarichi EM et al. Biofilm Production by *Candida* Species and Inadequate Antifungal Therapy as Predictors of Mortality for Patients with Candidemia. *J Clin Microbiol*. 2007; 45(6): 1843-50.
26. Binder MI, Chua J, Kaiser PK et al. Endogenous Endophthalmitis: An 18-Year Review of Culture-Positive Cases at a Tertiary Care Center. *Medicine*. 2003; 82(2): 97-105.
27. Kullberg BJ, Arendrup MC. Invasive Candidiasis. *N Engl J Med*. 2015; 373(15): 1445-56.
28. Durand ML. Bacterial and Fungal Endophthalmitis. *Clin Microbiol Rev*. 2017; 30(3): 597-613.
29. Breazzano MP, Day HR, Bloch KC et al. Utility of Ophthalmologic Screening for Patients With *Candida* Bloodstream Infections: A Systematic Review. *JAMA Ophthalmol*. 2019; 137(6): 698.

Authors' contributions:

Conceptualization: Ru Jian Jonathan Teoh, Yin Peng Lai, Rohanah Alias.

Methodology: Ru Jian Jonathan Teoh, Yin Peng Lai.

Data Collection: Ru Jian Jonathan Teoh, Yin Peng Lai.

Statistical analysis: Ru Jian Jonathan Teoh.

Data interpretation: Ru Jian Jonathan Teoh.

Writing original draft preparation: Ru Jian Jonathan Teoh.

Writing – review and editing: Ru Jian Jonathan Teoh, Yin Peng Lai, Rohanah Alias, Nor Azita Ahmad Tarmidzi, Swee Ying Choo.

Conflict of interest:

None.

Financial support:

None.

Ethics:

This study was in line with the Declaration of Helsinki and was approved by the local bioethics committee with the signature: 6/PNDR/2021.