

Case report

## Adrenocortical carcinoma in the face of Li-Fraumeni syndrome

**Tomasz Maroszczuk<sup>1</sup>, Zuzanna Smuniewska<sup>1</sup>, Jan Kapala<sup>1</sup>, Krystian Golon<sup>2</sup>**

<sup>1</sup> Students' Scientific Circle of Pathomorphology, Medical Faculty, University of Warmia and Mazury in Olsztyn

<sup>2</sup> Department of Pathomorphology and Forensic Medicine, Collegium Medicum, University of Warmia and Mazury in Olsztyn

### **Correspondence:**

Tomasz Maroszczuk  
Students' Scientific Circle of  
Pathomorphology, Medical  
Faculty, University of Warmia  
and Mazury in Olsztyn  
10-561 Olsztyn, ul. Żołnierska 18  
e-mail: tomasz.maroszczuk@  
student.uwm.edu.pl

### **Received:**

30.04.2023

### **Accepted:**

22.07.2023

DOI: 10.24292/01.OR.132220723

Copyright © Medical Education.

All rights reserved.

### **ABSTRACT**

Adrenocortical carcinoma (ACC) is a rare malignancy with a dismal prognosis. ACCs are caused by a cumulation of sporadic mutations, however, some inherited mutations may predispose to ACC. This paper presents a case of a 12-year-old child diagnosed with TP53 mutation, preceded by ACC diagnosis.

**Key words:** adrenocortical carcinoma, Li-Fraumeni syndrome, TP53 mutation

## INTRODUCTION

Between three and ten percent of people worldwide have an adrenal tumor. The majority are tiny, benign, non-functioning adrenocortical adenomas [1]. Contrarily, adrenocortical carcinoma (ACC) is a fairly uncommon entity. The incidence is thought to be between one and two per million each year worldwide [2, 3]. Early adolescence and years between 40 and 50 are when people are at highest risk for developing ACC [4].

ACCs are caused by a cumulation of sporadic mutations over time, however some inherited mutations may predispose to this malignancy. Among 50–80% of instances of ACC, the germline mutations in the *TP53* tumor suppressor gene is observed [2]. This mutation is the cause of Li-Fraumeni syndrome (LFS). LFS is an autosomal dominant malignancy predisposing disorder [5]. During childhood, the most characteristic malignancy of LFS is ACC. Osteosarcomas, brain tumors (choroid plexus carcinoma, medulloblastoma, glioblastoma), soft-tissue sarcomas, early-onset breast cancers, and leukemias are also typical for *TP53* mutation [6]. ACCs make up between three and ten percent of LFS-related malignancies, indicating that germline *TP53* mutations are linked with an elevated relative risk [6]. *De novo* mutations account for up to 25% of LFS cases, and patients in these cases have little or no family history [7]. Because LFS-related malignancies are varied and impact the entire body, cancer surveillance “Toronto Protocol” was instituted. This protocol consists of whole-body MRI, brain MRI, breast MRI, ultrasonography and endoscopy all conducted in regular time intervals [8].

Hormone excess symptoms are the main existing complaints for 40% to 60% of ACC patients [9]. Cushing syndrome symptoms are frequent inconveniences in functional ACC which lead patients to seek medical attention [10]. Sex hormone levels disruption is an additional reason for repeated medical care need. Most afflicted women present with virilization, hirsutism and oligomenorrhea. Men who have estrogen-secreting ACC become more feminine, develop gynecomastia and lose their libido [11]. One-third of patients exhibit generalized symptoms brought on by local tumor development, such as flank or stomach discomfort, bloating or early satiety. About 20% to 30% of ACCs are unintentionally identified as a result of imaging tests for unrelated medical conditions [10]. Rarely do patients with ACC exhibit typical tumor symptoms such as cachexia or night sweats [12].

## CASE REPORT

A 12-year-old boy reported to the physician with complaints of stomach discomfort, abdominal fullness and loose stools. On

physical examination, attention was drawn to a palpable drag 6 cm below the rib arch on the right side. Tanner scale pubic hair development was inadequate for age – P IV. Patient was directed to the hospital where an abdominal ultrasound was performed.

Magnetic resonance imaging (MRI) preceded by ultrasound revealed a 14 × 13 × 21 cm tumor spanning a significant portion of the right side of the abdomen. The mass was well demarcated from the surrounding area, heterogeneous, with apparent non-rich vascularisation and no visible calcifications (fig. 1). Echocardiogram revealed an irregular nodular formation with a dimensions of 2.5 × 5 cm attached to the atrial septum and posterior wall of the right atrium. The tumor mass did not obstruct blood flow into the right ventricle. A second ballooning nodular formation of 0.5 × 1 cm was discovered in the entrance of inferior vena cava (IVC) to the right atrium. Hormonal tests revealed an increase in cortisol, androstenedione, and dehydroepiandrosterone levels (tab. 1).

**Table 1.** Biochemical testing results of a 12-year-old boy with stage III adrenocortical carcinoma (ACC).

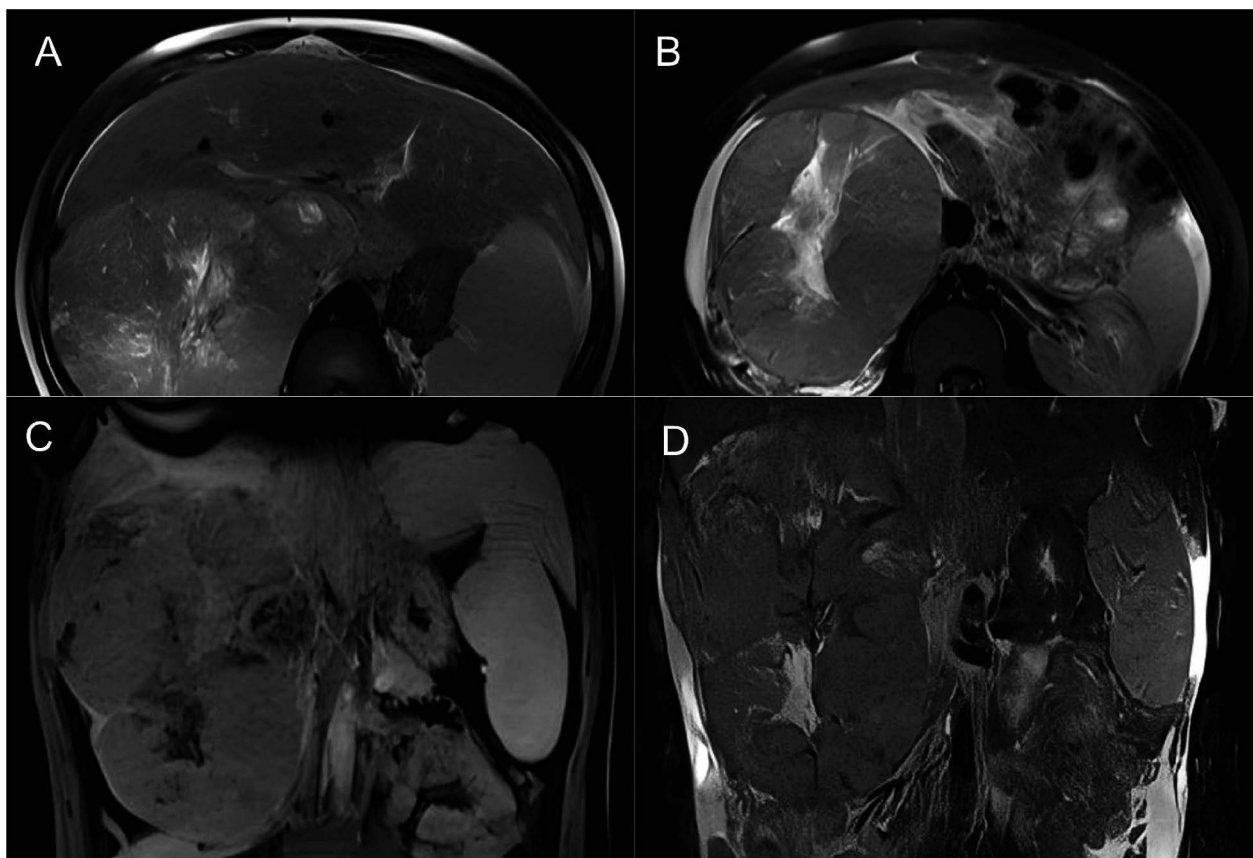
Biochemical test	Result	Reference range
Dexamethasone suppression test	negative	positive/negative
8:00 AM cortisol [ $\mu\text{g}/\text{dl}$ ]	54.3	5–25
Free cortisol in 24-h urine [ $\mu\text{g}/24\text{ h}$ ]	220.8	4–50
ACTH [ $\text{pg}/\text{ml}$ ]	15.4	10–60
Androstenedione [ $\text{ng}/\text{dl}$ ]	242.6	40–150
Dehydroepiandrosterone [ $\mu\text{g}/\text{dl}$ ]	603.3	89–457
Hydroxyprogesterone [ $\text{ng}/\text{ml}$ ]	> 20*	0.07–1.7
Metanephrine (to rule out pheochromocytoma) [ $\text{nmol}/\text{l}$ ]	0.2	< 0.5

\* Result above the measuring range.

A core needle biopsy of the lesion under ultrasonography guidance was performed. Pending the results of the histopathological examination, it was decided to start rescue chemotherapy. The patient received the first course of vincristine and cyclophosphamide. Histopathological examination of the tumor confirmed the ACC diagnosis and the collected clinical picture resulted in stage III classification for ACC (T3, N0, M0, S3) with unfavorable prognosis [13].

Currently the only curative approach for ACC is complete tumor resection. Complete tumor excision was impossible due to the presence of inoperable lesions in the right atrium. For patients with initially unresectable tumors, 2–4 courses of neoadjuvant chemotherapy with mitotane are recommended before surgery [14, 15]. Mitotane was included in the treatment in increasing doses, reaching a plasma level of 16–18 mg/l.

**Figure 1A, B, C, D.** Magnetic resonance imaging (MRI) with contrast. In the right mesogastrium, a pathological, heterogeneous, well-defined mass (14 × 13 × 21 cm) with irregular areas with a high T2W and a low T1W signal (probably necrosis). The mass compresses and shapes: the liver, the right kidney and the head of the pancreas. The inferior vena cava was dilated and filled with a heterogeneous mass.



Subsequently chemotherapy according to the GPOH-MET 97 treatment programme was started. Two cycles of NN-1 (vincristine 1.5 mg/m<sup>2</sup>, ifosfamide 1000 mg/m<sup>2</sup>, adriamycin 35 mg/m<sup>2</sup>) and two cycles of NN-2 (carboplatin 125 mg/m<sup>2</sup>, VP-16 100 mg/m<sup>2</sup>) were recommended [15]. After one cycle of NN-1 and one cycle of NN-2 with additional mitotane, lesions in the right atrium and IVC were reduced to 2 × 4 cm and 0,3 × 0,7 cm respectively.

Tumor resection was performed. The previously detected infiltrates in the right atrium and IVC were removed in a subsequent operation. After histopathological examination of the resected lesions, it was found that the mentioned lesions have been developing by continuity from ACC tumor. Following the surgeries, one more cycle of NN-1 and one more cycle of NN-2 were given to complete the treatment. The tolerance to all four cycles of chemotherapy was moderate. On further examination, the patient was diagnosed with a rare syndrome of increased predisposition to cancer – Li-Fraumeni syndrome. <sup>18</sup>F-FDG PET was performed 9 months following the end of the therapy and showed no signs of relapse.

## CONCLUSION

Diagnosing ACC at an early stage, when it can be surgically removed, significantly improves the prognosis, resulting in a 66–82% 5-year survival rate. If distant metastases occur, this rate drops to 0–17% [13]. Given the increased susceptibility of patients with LFS to rare cancers such as ACC, osteosarcomas, and brain tumors, a genetic examination of children with these cancers should be conducted. Also, physical, biochemical and genetic examinations of close family members should be considered if LFS is detected. To such individuals with detected Li-Fraumeni mutation, meticulous cancer surveillance with the “Toronto Protocol” should be instituted [8].

## ORCID

Tomasz Maroszczyk – ID – <http://orcid.org/0000-0002-2924-8646>

Zuzanna Smuniewska – ID – <http://orcid.org/0000-0002-3649-0617>

Jan Kapała – ID – <http://orcid.org/0000-0003-4019-851X>

Krystian Golon – ID – <http://orcid.org/0000-0001-6094-5215>

## References

1. Mansmann G, Lau J, Balk E et al. The clinically inapparent adrenal mass: update in diagnosis and management. *Endocr Rev.* 2004; 25(2): 309-40. <http://doi.org/10.1210/er.2002-0031>.
2. Fassnacht M, Kroiss M, Allolio B. Update in adrenocortical carcinoma. *J Clin Endocrinol Metab.* 2013; 98(12): 4551-64. <http://doi.org/10.1210/jc.2013-3020>.
3. McAteer JP, Huaco JA, Gow KW. Predictors of survival in pediatric adrenocortical carcinoma: a Surveillance, Epidemiology, and End Results (SEER) program study. *J Pediatr Surg.* 2013; 48(5): 1025-31. <http://doi.org/10.1016/j.jpedsurg.2013.02.017>.
4. Kerkhofs TM, Verhoeven RH, Van der Zwan JM et al. Adrenocortical carcinoma: a population-based study on incidence and survival in the Netherlands since 1993. *Eur J Cancer.* 2013; 49(11): 2579-86. <http://doi.org/10.1016/j.ejca.2013.02.034>.
5. Gargallo P, Yáñez Y, Segura V et al. Li-Fraumeni syndrome heterogeneity. *Clin Transl Oncol.* 2020; 22(7): 978-88. <http://doi.org/10.1007/s12094-019-02236-2>.
6. Jouinot A, Bertherat J. Diseases Predisposing to Adrenocortical Malignancy (Li-Fraumeni Syndrome, Beckwith-Wiedemann Syndrome, and Carney Complex). *Exp Suppl.* 2019; 111: 149-69. [http://doi.org/10.1007/978-3-030-25905-1\\_9](http://doi.org/10.1007/978-3-030-25905-1_9).
7. Chompret A, Brugières L, Ronsin M et al. P53 germline mutations in childhood cancers and cancer risk for carrier individuals. *Br J Cancer.* 2000; 82(12): 1932-7. <http://doi.org/10.1054/bjoc.2000.1167>.
8. Kumamoto T, Yamazaki F, Nakano Y et al. Medical guidelines for Li-Fraumeni syndrome 2019, version 1.1 [published correction appears in *Int J Clin Oncol.* 2022; 27(1): 262-3]. *Int J Clin Oncol.* 2021; 26(12): 2161-78. <http://doi.org/10.1007/s10147-021-02011-w>.
9. Fassnacht M, Allolio B. Clinical management of adrenocortical carcinoma. *Best Pract Res Clin Endocrinol Metab.* 2009; 23(2): 273-89. <http://doi.org/10.1016/j.beem.2008.10.008>.
10. Else T, Kim AC, Sabolch A et al. Adrenocortical carcinoma. *Endocr Rev.* 2014; 35(2): 282-326. <http://doi.org/10.1210/er.2013-1029>.
11. Fassnacht M, Libé R, Kroiss M et al. Adrenocortical carcinoma: a clinician's update. *Nat Rev Endocrinol.* 2011; 7(6): 323-35. <http://doi.org/10.1038/nrendo.2010.235>.
12. Ishikura K, Takamura T, Takeshita Y et al. Cushing's syndrome and big IGF-II associated hypoglycaemia in a patient with adrenocortical carcinoma. *BMJ Case Rep.* 2010; 2010: bcr07.2009.2100. <http://doi.org/10.1136/bcr.07.2009.2100>.
13. Libé R. Adrenocortical carcinoma (ACC): diagnosis, prognosis, and treatment. *Front Cell Dev Biol.* 2015; 3: 45. <http://doi.org/10.3389/fcell.2015.00045>.
14. Hubertus J, Boxberger N, Redlich A et al. Surgical aspects in the treatment of adrenocortical carcinomas in children: data of the GPOH-MET 97 trial. *Klin Padiatr.* 2012; 224(3): 143-7. <http://doi.org/10.1055/s-0032-1304627>.
15. Redlich A, Boxberger N, Strugala D et al. Systemic treatment of adrenocortical carcinoma in children: data from the German GPOH-MET 97 trial. *Klin Padiatr.* 2012; 224(6): 366-71. <http://doi.org/10.1055/s-0032-1327579>.

### Authors' contributions:

All authors should have made substantial contributions to all of the following: the conception and design of the article, drafting the article or revising it critically for important intellectual content, final approval of the version to be submitted.

### Conflict of interests:

Authors declare to have no conflict of interest.

### Financial support:

This research has not been funded by a third party.

### Ethics:

The authors had full access to the data and take full responsibility for its integrity. All authors have read and agreed with the content of the manuscript as written. The paper complies with the Helsinki Declaration, EU Directives and harmonized requirements for biomedical journals.