

Case report

Prostate cancer in clinical practice. First experiences with apalutamide within the context of therapeutic program B.56

Krzysztof Trzebiński

*Department of Urogenital Cancer, The Maria Skłodowska-Curie Department of Urogenital Cancer,
The Maria Skłodowska-Curie National Research Institute of Oncology in Warsaw*

Correspondence:

Krzysztof Trzebiński, MD
Department of Urogenital Cancer,
The Maria Skłodowska-Curie
Department of Urogenital Cancer,
The Maria Skłodowska-
-Curie National Research Institute
of Oncology in Warsaw
02-781 Warszawa, ul. Roentgena 5
e-mail: krzysztof.trzebinski@pib-nio.pl

Received:

23.03.2023

Accepted:

1.04.2023

DOI: 10.24292/01.OR.131316323

Copyright © Medical Education.

All rights reserved.

ABSTRACT

The article contains a case report of patient diagnosed with castration-resistant non-metastatic prostate cancer, treated with a novel androgen receptor inhibitor – apalutamide.

Key words: non-metastatic castration-resistant prostate cancer, apalutamide, androgen receptor inhibitor

INTRODUCTION

Recently, with society ageing in Poland and globally, the number of prostate cancer cases systematically increases [1, 2]. There is also a growing specific group of non-metastatic castration-resistant prostate cancer (nmCRPC) patients. Until recently, there was no possibility for adequate treatment of such patients in Poland but, in March 2022, the Ministry of Health (B.56) introduced updated drug programme (PL). Among the drugs made available under the programme, there is apalutamide – state-of-the-art androgen receptor inhibitor (ARI) which extend metastasis free survival (MFS) and overall survival (OS) of patients with nmCRPC [3].

CASE STUDY

In 2013, a patient aged 82 with concomitant hypertension, chronic renal failure stage 3, and optimally controlled asthma, was diagnosed with prostate adenocarcinoma in baseline stage cT2bN0M0, histopathologic tests assessed malignancy as Gleason 8 (3+5), with the highest PSA (prostate-specific antigen) level of 23 ng/mL. Imaging scans excluded metastases. Initial hormonotherapy was started with luteinising hormone releasing hormone (LHRH) analogue – leuporelin at the dose of 22.5 mg subcutaneously. As a result, PSA level was reduced to 3.58 ng/mL. The patient was qualified for radical treatment involving image-guided radiotherapy (IGRT) with 15 MV photons according to 3D CBCT (cone beam computed tomography) plan; dose administered: 6500 cGy/g in 25 fractions to the prostate area, and next supplementary hormonotherapy was continued with LHRH analogue every 3 months for the total period of 3 years (until 2016) due to the patient's classification into the high-risk group (Gleason 8 and PSA > 20 ng/mL) [4]. During hormonal therapy, osteoporosis prevention was applied using a preparation of calcium and vitamin D3, with PSA remaining within the limits < 0.3 ng/mL.

The patient remained under observation until 2018 when, due to increased PSA level to 1.8 ng/mL, imaging diagnostics was implemented (static bone scintigraphy), which did not reveal any metastases. The observation was continued but, due to dynamic increase in PSA to 5 ng/mL in 6 months, a decision was made to introduce treatment with LHRH analogue – triptorelin subcutaneously at the dose of 11.25 mg every 3 months. Temporary effect was achieved with PSA level reduced to 0.2 ng/mL but, in 2020, at PSA of 1.7 ng/mL, maximal androgen blockade (MAB) was started and the existing treatment was combined with androgen antagonist – flutamide at the dose of 250 mg orally 3 times per day, and next, due to poor tolerance, the drug was

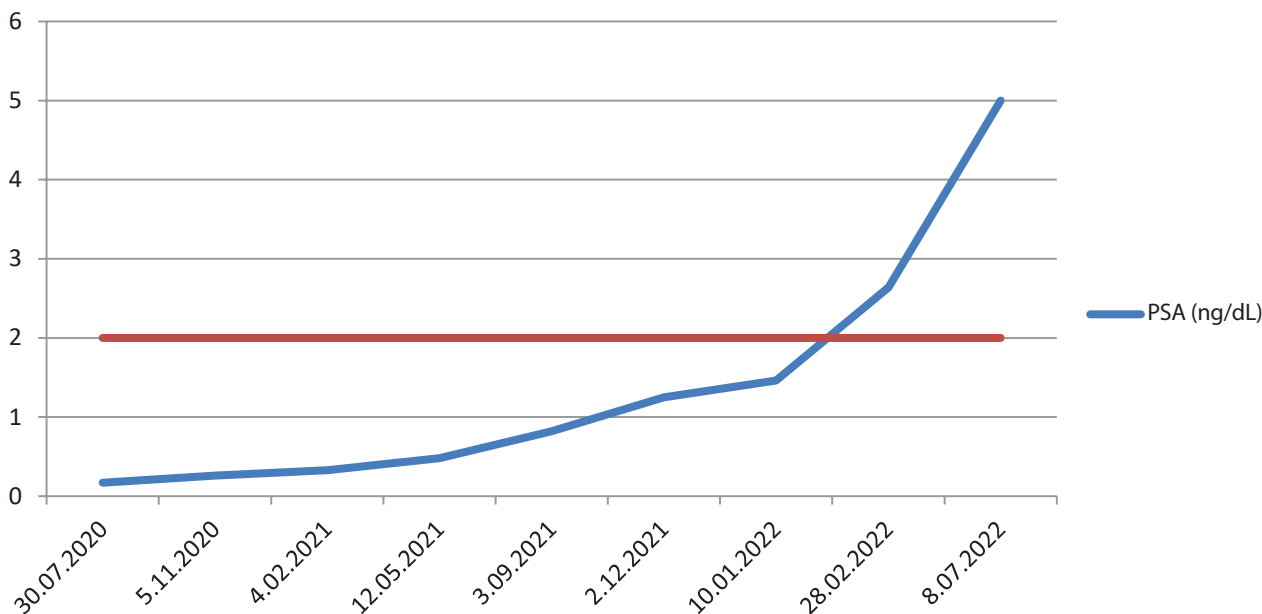
replaced with bicalutamide (50 mg orally once per day). Double hormonal therapy was conducted with good biochemical effect (PSA reduced to 0.17 ng/mL – nadir) and clinical effect for almost 2 years (until December 2021), when, with PSA of 1.25 ng/mL, bicalutamide was discontinued, which did not, however, bring the effect of reducing PSA levels. The patient was referred to imaging scans for assessment in the aspect of secondary lesions, which would allow implementation of a new treatment (at the time, applicable drug programme allowed state-of-the-art hormonotherapy exclusively in metastatic diseases). The CT of the chest, abdominal cavity, and true pelvis with IV contrast and bone scintigraphy did not reveal any metastatic lesions.

In March 2022 in Poland, a new tool was introduced for treatment of patients with nmCRPC in the form of a drug programme by the Ministry of Health. According to the requirements of the programme, the analysed patient had the aforementioned imaging scans repeated, and no metastases were found again. The patient was qualified for treatment with apalutamide at the dose of 240 mg once per day on 11 July 2022 with PSA of 5.0 ng/mL and castrate testosterone level (< 2.5 ng/dL); treatment with LHRH analogue was continued. It must be added that the patient met a number of criteria stated in the programme: apart from documenting the absence of secondary lesions, at least three consecutive increases to PSA levels occurred at the intervals of at least one week, including at least two by 50% vs. baseline (nadir), at nominal PSA > 2 ng/mL (patient's PSA levels and cut-off for onset of treatment have been presented in figure 1).

Another requirement of the programme involves PSA doubling time (PSADT) of under 10 months, which translates to high risk of metastases in the patient [5]; also this criterion was met, because patient's PSADT amounted to 4.1 months (there are generally available calculators allowing to calculate PSADT, including ONCOassist®). At the beginning of treatment, the patient was in good general condition (score 1 in the scale of ECOG, Eastern Cooperative Oncology Group), with chronic diseases well controlled, with no indications of heart failure or severe renal or liver failure.

Because of the advanced age of the patient and concomitant chronic diseases, it was decided to hold control visit at monthly intervals. During the first control visit, findings included PSA reduced to 0.48 ng/mL, very good tolerance of treatment and, apart from temporary feeling moderately weak for several days, no adverse events were recorded. Following 2 months of treatment, further reduction to PSA was observed to 0.31 ng/mL, but the patient reported burdensome side effects in the form

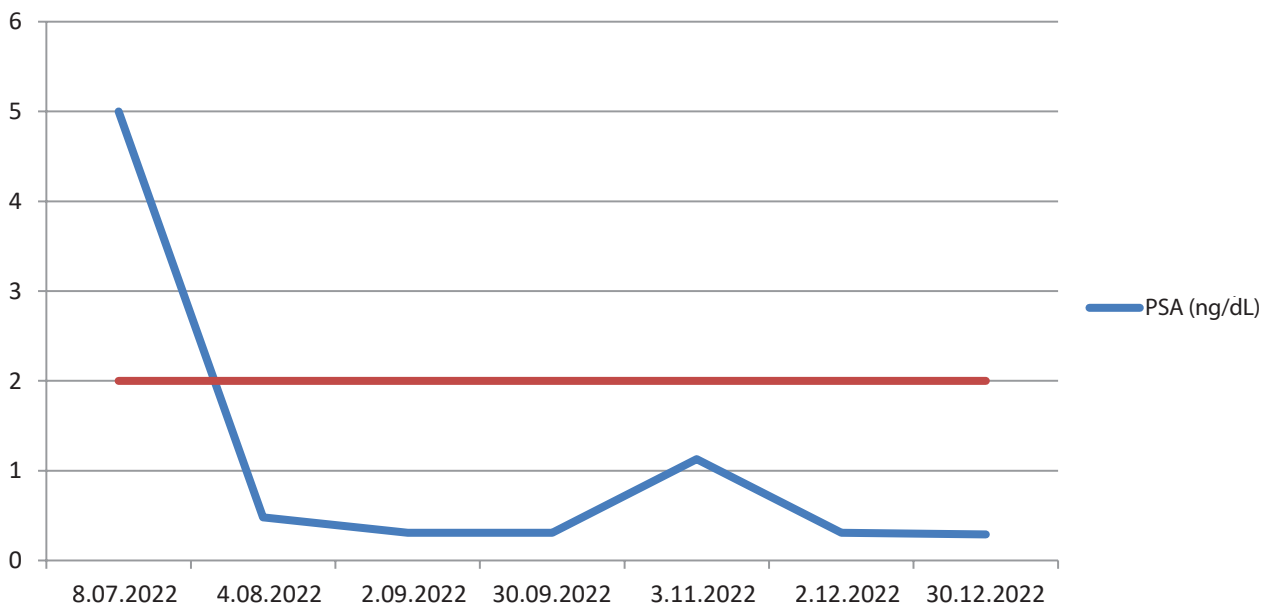
Figure 1. PSA level dynamics before treatment with apalutamide. Level 2 ng/mL – required for starting treatment under the drug programme – marked in red.



of chronic fatigue grade G2 acc. to CTCAE (Common Terminology Criteria for Adverse Events), maculopapular rash grade G3, headaches, vertigo grade G1/2 (neurological examination and laboratory tests did not reveal major irregularities). In line with the statement in medicinal product data sheet (ChPL), a decision was made to temporarily suspend the treatment, with recommended oral antihistamine drugs and local glucocorticoster-

oids, and accelerated control visit was appointed after 7 days. At the time, the patient's general condition improved, with general symptoms alleviated and reduced rash intensity to grade G1; therefore, in agreement with the patient (and again in line with ChPL), it was decided to continue treatment at a dose reduced by half (120 mg once per day). It is worth pointing out that skin rash at any degree of intensity and fatigue belong to the most

Figure 2. PSA level dynamics during treatment with apalutamide. Level 2 ng/mL – required for starting treatment under the drug programme – marked in red.



frequent adverse events related to apalutamide (occurring in > 25% patients) and in a large majority of cases (> 90%) do not lead to complete discontinuation of the treatment with the drug. After one month of treatment at a reduced dose, PSA remained at a stable level of 0.31 ng/mL, whereas upon the next measurement, progression to 1.1 ng/mL was recorded (PSA level dynamics has been presented in figure 2).

The patient admitted that due to the occurrence of an influenza-like infection, without consulting the doctor, he autonomously discontinued administration of the drug for almost 2 weeks.

Due to patient's wellbeing during the visit, it was decided to restore the full dose of apalutamide (240 mg/24 h), owing to which, in consecutive bimonthly control visits, the achieved PSA level was, respectively: 0.31 ng/mL and 0.29 ng/mL at acceptable adverse effects of the treatment. At the time of drafting this article, the treatment is continued at a full dose, and the patient awaits the description of control bone scintigraph after 6 months from enrolment in the programme.

It is worth mentioning that, according to the drug programme, treatment of nmCRPC patients can be conducted until PSA progression defined as three consecutive PSA increases titrated in

at least weekly intervals with proven increase by at least 50% vs. baseline (namely, in the case of the analysed patient this was 5 ng/mL), at nominal PSA level > 2 ng/mL. Another independent condition for treatment discontinuation is the occurrence of metastases to the bones, confirmed in scintigraphy scan, which is mandatory after 6 months. Furthermore, the programme allows the doctor to perform imaging scans at any time, depending on the clinical situation; the occurrence of metastases in the scans certainly constitutes an absolute exclusion criterion from the programme.

CONCLUSION

In the above clinical case of the patient with nmCRPC, state-of-the-art antiandrogen drug, apalutamide, was applied successfully. It is a treatment that offers patients an opportunity to extend their metastasis-free survival, principally with respect to metastasis to bones, and thus the related complications, including pain, pathological fractures, or spinal cord compression syndrome. State-of-the-art hormone therapy for this indication has been available in Poland rather recently, and currently observations are made as to efficacy of the treatment, which will constitute grounds for further knowledge exchange from the clinical point of view.

References

1. Sung H, Ferlay J, Siegel RL et al. Global Cancer Statistics 2020: GLOBOCAN Estimates of Incidence and Mortality Worldwide for 36 Cancers in 185 Countries. *CA Cancer J Clin.* 2021; 71: 209-49. <http://doi.org/10.3322/caac.21660>.
2. Didkowska J, Wojciechowska U, Olasek P et al. Nowotwory złośliwe w Polsce w 2019 roku. Warszawa 2021.
3. Smith MR, Saad F, Chowdhury S et al. Apalutamide treatment and metastasis-free survival in prostate cancer. *N Engl J Med.* 2018; 378: 1408-18. <http://doi.org/10.1056/NEJMoa1715546>.
4. Parker C, Castro E, Fizazi K et al. Prostate cancer: ESMO Clinical Practice Guidelines for diagnosis, treatment and follow-up. *Ann Oncol.* 2020; 31: 1119-34. <http://doi.org/10.1016/j.annonc.2020.06.011>.
5. Howard LE, Moreira DM, De Hoedt A et al. Thresholds for PSA doubling time in men with non-metastatic castration-resistant prostate cancer. *BJU Int.* 2017; 120(5B): E80-6. <http://doi.org/10.1111/bju.13856>.

Conflict of interests:

Author declare to have no conflict of interest.

Financial support:

This research has not been funded by a third party.

Ethics:

The authors had full access to the data and take full responsibility for its integrity. All authors have read and agreed with the content of the manuscript as written. The paper complies with the Helsinki Declaration, EU Directives and harmonized requirements for biomedical journals.