

# Application of NPWT in the surgical treatment of wounds and injuries of various locations - case series

Zarutskii Ya.L., Aslanyan S.A., Plis I.B., Kompaniets A.O., Goncharuk V.S.

## CASE SERIES

**Abstract**— In the modern world, local military conflicts are not uncommon. A feature of local wars is a dynamically changing tactical situation, which can lead to massive losses and more serious injuries. This creates new challenges related to the treatment of combat trauma victims. We analyzed our experience of application of NPWT in complex surgical treatment of combat wounds and injuries of various locations.

**Keywords**—npwt, gunshot wounds, VAC therapy, combat trauma

### I. INTRODUCTION

**T**HE military conflict in the East of Ukraine led to a significant increase in the number of explosive and gunshot wounds, both among the armed forces and the civilian population.<sup>1, 2</sup> In the structure of modern combat surgical trauma, the main part is shrapnel 61.6% and bullet 9.1% gunshot wounds, blast trauma and burns are 27% and 2.3% respectively.<sup>1, 3</sup>

During the Anti-terrorist operation in the east of Ukraine, the largest proportion was head injuries 31.9%, thorax 11.7% abdomen 7.3% and limbs 62.6% (Tab. I).<sup>4</sup>

The problem of the treatment of gunshot wounds and their consequences remains the main task of military field surgery, because of the complexity of diagnosis and treatment, with long hospitalisation terms, accompanied by a large number of complications (12-47%) with a high percentage of disability (4.9-7.3%).<sup>1, 5, 6</sup>

The main task of military surgery in the treatment of gunshot wounds of various locations is to shorten the terms of treatment, the early return of the wounded to duty.<sup>7</sup>

The main method of gunshot wounds treatment still remains primary, repeated and secondary surgical debridement with subsequent application of sterile dressing. The final stage of treatment is the closure of a wound defect by one of the plastic surgery methods according to the "reconstructive ladder".<sup>6, 8, 9</sup>

Large gunshot defects of tissues with complex forms of a wound channel, presence of important anatomical formations

Manuscript received 23.07.2018; revised 28.09.2018. This work did not receive any financial support. Authors declare no conflict of interest.

Author affiliations: Ukrainian military medical Academy, Kiyv, (YZ, SA, AK, VG) ; Mukachevo military hospital, Mukachevo, (IP)

\*Correspondence to: Zarutskii Ya.L.: zarutsky@ukr.net

on the bottom of wounds create significant difficulties with wound-dressing modeling, their superposition and ensuring adequate outflow of wound exudate.

Considering the foregoing, in the complex surgical treatment and preparation for the closure of the gunshot wounds of the soft tissues of the chest, abdomen and pelvis, the NPWT method rapidly spread.

The aim of the study was to study the results of treatment of victims with gunshot wounds of various localizations by applying NPWT techniques in complex surgical treatment.

Table I  
STRUCTURE OF COMBAT TRAUMA (COMBINED TRAUMA ACCOUNTED)

Localization	Total [%]	Soft tissues [%]
Head	31,9	26,3
Neck	1,9	0,9
Spine	1,1	-
Thorax	11,7	9,3
Abdomen	7,3	4,9
Pelvis	2,6	1,5
Limbs	62,6	48,9
Burns	2,7	2,7
Combined	22,7	22,7

### II. MATERIALS AND METHODS OF RESEARCH

We carried out the analysis of treatment results of 195 gunshot wounded, who were treated with NPWT method in the National Military Medical Center of the Ministry of Defense of Ukraine in the period from 2014 to 2017.

All the injured were male with an average age  $39.6 \pm 5.3$  years. In 37.8% there were wounds of soft tissues, in 62.2% of wounds were connected with open gunshot fractures of bones of upper and lower extremities, required immobilization with external fixation. All the wounded came from institutions II and III levels of medical care by air and land medical evacuation within a period of 3 to 20 days from injury.

NPWT was performed with a usage of KCI, HearCo, GomCo, and other VAC systems, in combination with irrigation with antiseptics and antibiotics, with oxygen insufflation, hyperbaric oxygenation, ultrasonic cavitation, NO therapy for additional stimulation of repair processes.

The NPWT technique is universal and has been used at various stages of wound healing:

- 1) Immediately after wound debridement to prevent infection.
- 2) In cases of infectious complications development.
- 3) As a stage of preparation of wound defects to plastic closure.
- 4) After reconstructive interventions, as a method of post-operative wound care.

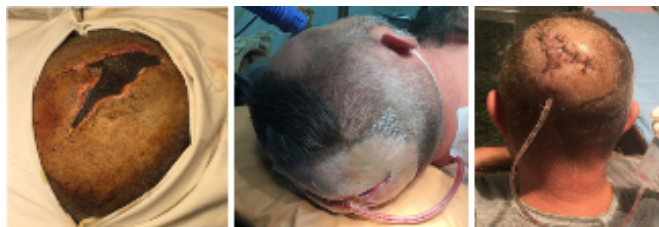

Figure 1. Shrapnel gunshot wound of the head. Surgical treatment of soft tissue defect.

Indications for the use of NPWT in cases with head injuries ( $n = 6$ ) were infected wounds, temporary closure of soft tissue defects. The purpose of NPWT was: cleansing infected wounds, reducing their size, stimulating granulation tissue and preparing for plastic closure (Fig. 1).

Contraindications to the use of NPWT were: the presence of wounds connected with the oral cavity, penetrating injuries of the ENT organs, osteomyelitis of subordinate bones, necrotic tissue, bleeding or liquorrhea in the wound area. When the bandages come into contact with the main vessels of the head, standard or improvised protectors were used. In the world literature there are reports of the successful use of NPWT in injuries with defects of the dura mater.<sup>1</sup>

NPWT of infected wounds in the neck ( $n = 3$ ) was used to temporarily close the wounds at the stage of preparation for their plastic closure (Fig. 2).

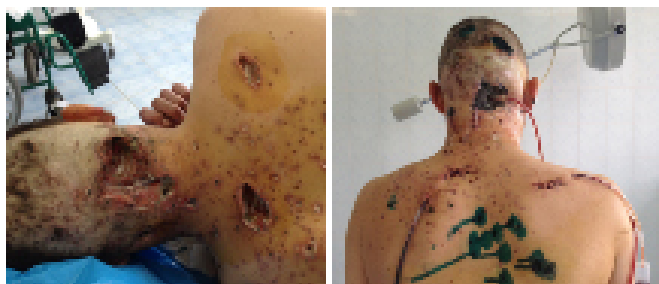

Figure 2. Multiple shrapnel wounds of the head, neck, thorax. NPWT of soft tissues of the neck.

Contraindications to the imposition of vacuum dressings were bleeding in the wound area, the main vessels of the neck in the bottom of wound defects, defects of the esophagus, trachea. The NPWT system was applied with  $-75$  Hg mm.

Indications for the use of NPWT in chest injuries ( $n = 7$ ) were infected wounds of the chest wall, defects of the chest wall with open pneumothorax, presence of a wound of the chest wall in combination with pleural empyema, temporary

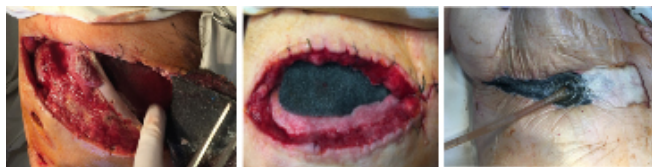

Figure 3. Treatment of pleural empyema after thorax combat injury: left – resection of the rib, thoracostomy; middle – closure of chest wall defect with a sponge; right – NPWT of the chest wall defect.

closure of the wound in preparation for thoracoplasty. Contraindications to the application of NPWT were osteomyelitis of the ribs or sternum, excessive necrotic tissue, bleeding in the wound area, unexplored fistula, bronchial fistulas (relative contraindication) (Fig. 3).

We have experience in applying a sponge to an intact pleura, and if the pleura was damaged polyvinyl-alcohol white sponge protectors have been used. In cases of doubt in the viability of the ribs, perforation was performed or, according to indications, the external cortical rib plate was removed and, after evaluation of the blood supply, the closure was completed with a polyurethane sponge. With pleural empyema or pericarditis, NPWT made it possible to accelerate the eradication of the inflammatory focus.

With penetrating wounds of the abdominal cavity ( $n = 25$ ), indications for NPWT usage were: open wounds of the abdominal cavity and abdominal wall defects (3), abdominal compartment syndrome (3), postoperative complications of the abdominal cavity organs (ischemic abdominal syndrome (2), progressive peritonitis (6), postoperative complications of the wound (10), burns of the abdominal wall (1). The purpose of the NPWT was adequate sanitation of the abdominal cavity, removal of the compartment syndrome, and the tactics of conducting the open abdomen (Fig. 4).

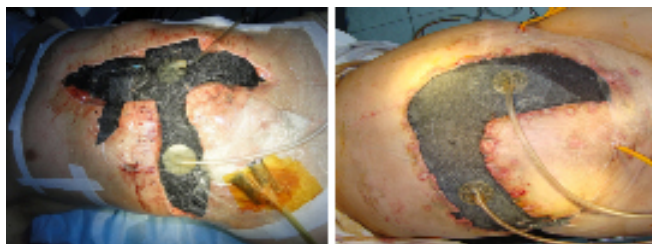


Figure 4. NPWT in abdominal combat wounds: gradual wound closure

Absolute contraindications to the use of NPWT with injuries of the abdomen were: active bleeding, unstable hemostasis, and not a sanitized septic focus; intestinal, bile, urinary fistulas, a large number of necrotic tissues or abdominal wall defects, that did not allow to create a closed space.

Relative contraindications were: violation of the blood clotting, a defect in the wall of hollow abdominal organs (enteroatmospheric fistula).

When forming a vacuum bandage, the sponge should not come into direct contact with the hollow organs. Standard (AV-Thera) or improvised protectors with a polyurethane sponge and an adhesive film were used to prevent complications.

In case of peritonitis, bandages were replaced after 24-48 hours. With abdominal compartment syndrome, IAP monitoring is mandatory 2-4 times a day (no more than 15 mm). In cases of enteroatmospheric fistulas, standard or improvised obturators were used (Fig. 5).

Indications for the NPWT usage in pelvic injuries were infected wounds, which were temporarily closed in the preparation for plastic closure. Contraindications: active foci of osteomyelitis, unexplored fistulas, rectum damage, unreliable hemostasis. With injuries to the pelvic organs (n = 6) and perineum, there were technical problems in achieving tightness of NPWT dressings due to the complex relief of the site.

We have experience of successful application of NPWT with bladder damage and thrombosis of the cavernous bodies of the penis (Fig. 6).

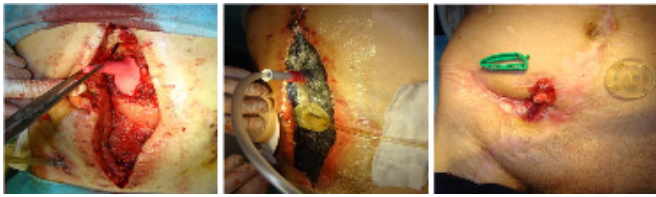

Figure 5. NPWT in cases of enteroatmospheric fistulas: left – placement of improvised obturator; middle – applying of NPWT; right – wound closure with functioning fistula.

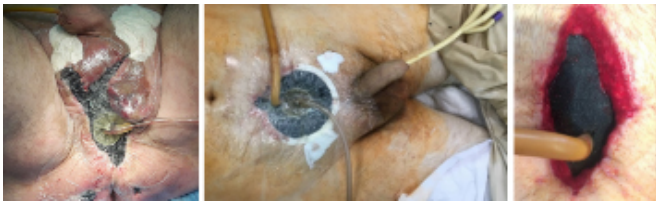


Figure 6. Left – NPWT of perineum wound; middle and right – NPWT of abdominal wall with functional suprapubic cystostomy.

Victims with limb injuries were the most numerous group of clinical observations (n = 147). NPWT was used in the presence of infected wounds and for temporary closure in preparation for plastic closure according to the "reconstructive ladder" introduced in the modern surgical treatment system. Contraindications: foci of osteomyelitis, unexplored fistula, necrotic tissue, active septic process (Fig. 7)(Fig. 8).

When forming NPWT dressings on limbs, the sponge should not be in contact with: large neural trunks (threat of necrosis of nervous tissue), large vessels (threat of hemorrhage). To prevent these complications, standard polyvinyl-alcohol sponge protectors from poly were used.

In cases of combined wounds with various anatomical and functional sites polyfocal NPWT were used with one or several vacuum devices. In this case, it became necessary to form external improvised or standard bridges for remote localization of injuries, as well as internal bridges, which densely contacted the main sponge with wound defects located nearby. Internal bridges should not be in contact with vessels and nerves.(Fig. 9)

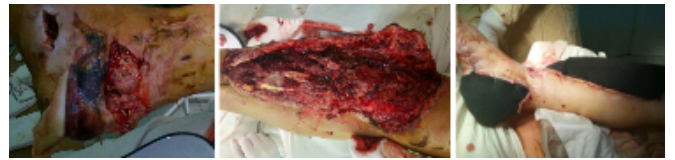

Figure 7. NPWT in treatment of injured lower limb: left - tissue defect in the foot area; middle - tissue defect in the shin area; right - forming closure.

The presence of external fixation devices made it difficult to achieve the tightness of the VAC bandage. When carrying out VAC therapy of large and extensive wounds, there is a threat of thrombosis of large main vessels - therefore, prior to the application of NPWT dressings, the condition of blood circulation by means (ultrasound, doppler, pulse oximeter, etc.) must be determined.

When combined wounds of various anatomical and functional sites were present, we used polyfocal NPWT using one or several vacuum devices. In this case, it became necessary to form external improvised or standard bridges for remote localization of injuries, as well as internal bridges, which densely contacted the main sponge with a number of wound defects located nearby. Internal bridges should not be in contact with vessels and nerves.

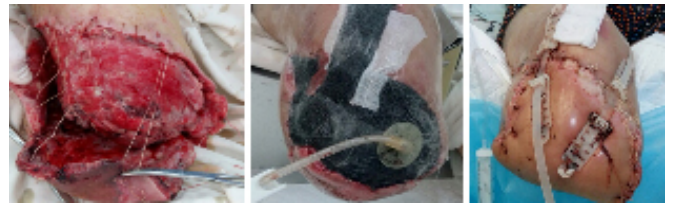

Figure 8. Blast injury with traumatic amputation of right lower limb at the level of the middle third of the shin: left – skin necrosis; middle – NPWT of right lower limb stump; right – closure of defect with tension system (TopClosure).

When closing the wound defects, rare stitches were applied, which were externally covered with a gauze cloth, and the skin was protected with a tread. The polyurethane sponge was fixated to the edges of the wound to prevent its displacement.

In cases of deep blind wounds with a narrow wound canal, deep pockets were plugged with separate sponges with close contact with the main sponge which filled the wound channel and had perforated drainage inside. In cases of presence of bones with signs of osteomyelitis, decortication of the bone was performed, followed by application of a polyurethane sponge to the destruction site. This accelerated the elimination of osteomyelitis foci, stimulated regional blood flow and growth of granulation tissue.

At deep extensive defects the sponge was stacked in several layers before the full execution of the wound. When performing NPWT instillation, good results were obtained when placing drainage through the counter aperture directly to the wound surface.

The application of polyvinylalcohol vacuum dressings at low negative pressures was used to manage wounds after autodermoplasty with significant wound exudation, to contain

the split autodermotransplant in the complex relief of the wound surface, to accelerate its integration, and to prevent the traumatization of the graft.

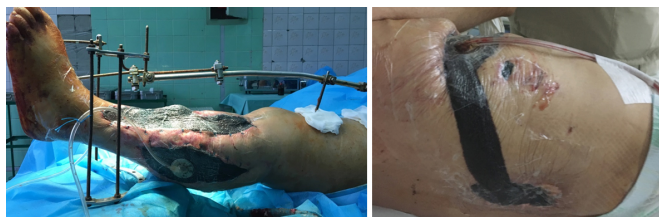

Figure 9. Blast injury with traumatic amputation of right lower limb at the level of the middle third of the shin: left – skin necrosis; middle – NPWT of right lower limb stump; right – closure of defect with tension system (TopClosure).

Features: when NPWT is used for all localizations, monitoring of its status is mandatory, since there is a threat of bleeding. There are six death cases described in the literature, and we have experienced three timely detected bleedings which were successfully ceased.

Indications for NPWT discontinuation were: a change in the phase of exudation to the proliferation phase, wound cleaning, the appearance of active granulations, marginal epithelization, decrease in microbial contamination to 10 or less CFU, a normalization of microcirculation indices.

### III. CONCLUSIONS

- 1) The use of NPWT in the complex treatment of gunshot and extensive wounds improves microcirculation, evacuation of exudate, leads to a reduction in the wound defect and its preparation for plastic closure

- 2) The use of NPWT for the closure of thoracic and abdominal traumatic and postoperative wounds has a curative effect not only on the wound itself, but also on the internal organs of this cavity
- 3) The NPWT method can be used in the complex surgical treatment of wounds of various locations in all phases of the wound process; The indications for its use are constantly expanding, methods are being developed to reduce contraindications.

### REFERENCES

- [1] Y. L. Zarutskii and O. O. Shudrak, "Vkazvki z voenno-polovo hrurgi: dlya medicnogo skladu zbrojnih sil ukraini ta nshih silovih vdomstv," *Kyiv*, pp. 351–373, 2018.
- [2] G. E. Samoylenko and O. V. Andreev, "The extensive battle wound features and there plastic closure," *Kharkivjska khirurgichna shkola*, vol. 78, no. 3, pp. 118–122, 2016.
- [3] M. A. Kashtalyan, S. V. Tertishniy, and K. L. Masunov, "Use of vac-therapy in comprehensive treatment of gunshot wounds," *Visnyk morskoji medycyny*, no. 2, pp. 187–192, 2016.
- [4] I. R. Trutyak, I. M. Hajda, G. A. Prohorenko, V. I. Medzyn, and R. I. Trutyak, "Complications characteristic of the modern combat surgical trauma," *Acta medica Leopoliensia*, vol. 22, no. 3, pp. 50–54, 2016.
- [5] R. N. Mikhayusov, "Experience of application of vacuum systems in the treatment of soft-tissue gunshot wounds," *Clinical Surgery*, no. 6, pp. 61–64, 2016.
- [6] V. R. Belenky, V. V. Negoduyko, and R. M. Mykhaylusov, "Errors in the primary surgical debridement of soft tissues gunshot wounds," *Surgery of Ukraine*, no. 1, pp. 7–13, 2015.
- [7] A. Laksha and D. Los, "The patients with soft tissue gunshot injuries managment," *Chronicle of traumatology and orthopedics*, no. 1-2, pp. 31–36, 2015.
- [8] R. Holmgaard, J. Duffy, and F. E. Warburg, "Danish experience with free flaps in war wounds," *Danish Medical Journal*, vol. 64, no. 1, pp. 1–4, 2016.
- [9] J. M. Sabino, J. Slater, and I. L. Valerio, "Plastic surgery challenges in war wounded i: Flap-based extremity reconstruction," *Advances in Wound Care*, vol. 9, no. 1, pp. 403–411, 2016.