

Novel Technique for Treating Multiple Wounds with Negative Pressure Wound Therapy

Dominik A. Walczak, MD*, Rajmund Jaguścik, MD, Karolina Ptasńska, MD, Michał Wojtyniak MD, Piotr W. Trzeciak, MD

TOOLS AND TECHNIQUES

Abstract—Treatment of separate wounds on the same patient with one NPWT device may be challenging. We present a novel, cost-effective technique for multiple wounds' management.

Keywords—Negative pressure wound therapy, dressing, multiple wounds, technical concept

I. INTRODUCTION

SOMETIMES we need to manage multiple wounds on the same patient. Both the y-connector technique and the bridging technique are well known and often used however they have some limitations.¹ Moreover, it is hard to treat more than two wounds using them. We present a novel, cost-effective technique for the management of multiple wounds.

II. DRESSING APPLICATION TECHNIQUE

- 1) Introduce the foam or the gauze into the wounds (Fig 1B).
- 2) Prepare the Nelaton catheters 18 French or larger.
- 3) The catheters should be cut to the length from the middle of the central wound to the middle of the peripheral wounds.
- 4) Create two holes in the both tips of the catheter. The hole on the peripheral end should be positioned on the 6 o'clock (facing the foam) and the hole above the central wound on the 12 o'clock (Fig. 1C, 1D).
- 5) Apply film dressing (Fig. 2A).
- 6) Cut a hole into the film, above the Nelaton catheters, where the suction tubing is to be applied (Fig. 2C).
- 7) The central holes in all Nelaton catheters must be placed directly below the suction tubing port (Fig. 2C).
- 8) Apply the port and switch on the negative pressure unit (Fig. 2D).

III. DISCUSSION

The advantage of our novel technique is the ability to join several wounds of alike origin with one negative pressure

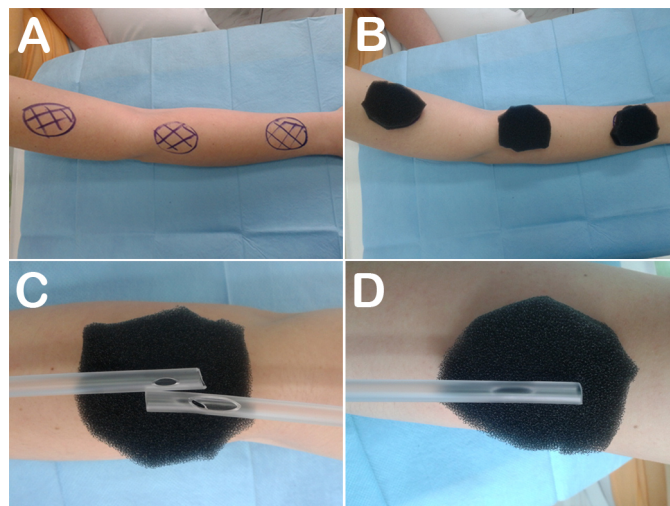


Figure 1. A) Three wounds on the upper limb; B) Foam introduced into the wounds; C) Two Nelaton catheters placed on a middle wound with holes on the 12 o'clock; D) The Nelaton catheters placed on a peripheral wound, the hole is facing the foam

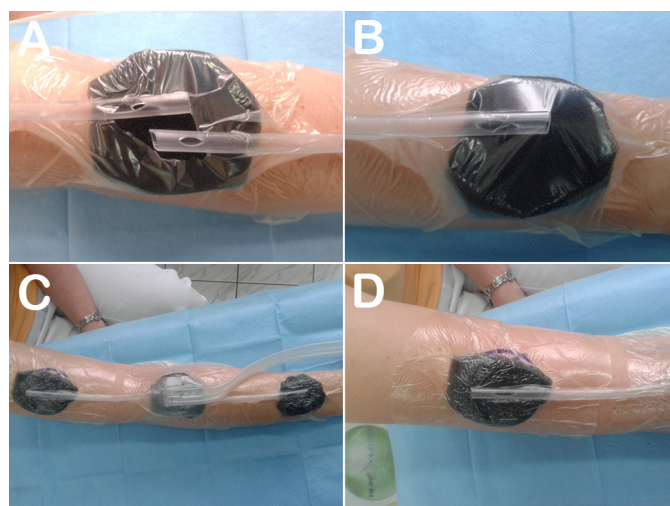


Figure 2. A) The film dressing applied to the foam and the catheter; B) The hole in the film dressing, above the Nelaton catheters; C) Finished dressing; D) Effective suction applied to the peripheral wound evident by wrinkles in film dressing

Manuscript received 2.4.2015; revised 11.10.2015. No conflict of interest.

Author affiliations: Department of General Surgery, John Paul II Memorial Hospital in Bełchatów, Poland, Address: Szpital Wojewódzki im Jana Pawła II w Bełchatowie, Oddział Chirurgiczny Ogólny, ul. Czapliniecka 123, 97-400 Bełchatów, (DAW, RJ, KP, MW, PWT)

*Correspondence to: Dominik Walczak (dr.dominikwalczak@gmail.com).

therapy unit. Due to Nelaton catheters the distance between wounds could be from few to even 20 centimeters.

In comparison with the y-connector technique, it requires only one piece of tubing which is cost-effective and might be more convenient for the patient. The holes in Nelaton catheters placed directly below the suction tubing ensure that exudates from the peripheral wound are not drawn across the central wound. The Nelaton catheters are situated on the wound filler (foam or gauze) so even when we turn on the suction there is still small space between catheters and the skin (they don't exert pressure on the skin).

Let us consider options that we have if we want to manage three wounds situated on the upper limb like on the figure 1A.

- We could use y-connector technique, take three suction ports, two y-connectors and link them. However, so many tubes might be inconvenient for the patient. Moreover, this solution might create a financial burden, especially during long treatment. Furthermore, KCI does not recommend to use more than one y-connector per therapy unit.¹
- We could use the bridging technique. However, we need to remember that the suction port should be placed between two wounds to ensure that exudate from the one wound is not drawn across the second. In that case, we hypothetically could place suction port beyond the wounds and create three foam bridges to all wounds although this dressing will be extremely hard to do.
- The third way is to combine both techniques. Bridge two wounds together and link them using y-connector with the third one.
- Finally, we could use our technique with Nelaton catheters which seems to be the easiest and the most cost-effective way to manage these wounds.

IV. CONCLUSIONS

Our technique is another therapy option which could be combined with y-connector technique and the bridging tech-

nique to provide effective management of multiple wounds with one NPWT device.

REFERENCES

- [1] KCI Licensing Inc., "V.A.C. therapy. clinical guidelines manual," San Antonio, Texas 2014.



Rajmund Jaguściak is currently working in the Department of General Surgery of the John Paul II Memorial Hospital in Bełchatów. He graduated from the Medical University of Łódź in 2004 and specialized in general surgery in 2012. Member of Polish Surgical Society. Current medical interests: negative pressure wound therapy, chronic wounds, open abdomen treatment, laparoscopic surgery.



Karolina Ptasieńska graduated from the Medical University of Łódź in 2012. She started a residency at the Department of General Surgery in Bełchatów in 2013. Current medical interests: laparoscopic surgery, chronic wounds.



Michał Wojtyniak is working in the Department of General Surgery in Bełchatów. He received the MD degree from the Medical University of Łódź in 2013. In January 2015 he started his surgical residency. Current medical interests include laparoscopic surgery and chronic wounds.



Dominik A. Walczak, MD received the MD degree from the Medical University of Łódź in 2008. In 2009, he started a surgical residency at the Department of General Surgery, John Paul II Memorial Hospital in Bełchatów. Since 2013, he has been working as a volunteer at Department of Experimental Surgery, Medical University of Łódź.

He is preparing a Ph.D. thesis on micro-vascular prosthesis from novel biomaterials. He is an author or coauthor of more than 30 scientific publications. His current medical and research interests include:

experimental surgery, microsurgery, reconstructive surgery, open abdomen, negative pressure wound therapy, chronic wounds, laparoscopic surgery, endoscopy.



Piotr W. Trzeciak is the Head of the Department of General Surgery, John Paul II Memorial Hospital in Bełchatów. He graduated from the Medical University of Łódź in 1996, specialized in general surgery in 2006. Member of Polish Surgical Society and Polish Wound Management Association. His current medical interests include negative pressure wound therapy, chronic wounds and laparoscopic surgery.