POLSKI
PRZEGLĄD CHIRURGICZNY
2015, 87, 12, 641–643

10.1515/pjs-2016-0017

DE GRUYTER OPEN

BLEEDING LIVER TUMOR IN A PATIENT ON ANTICOAGULATION THERAPY – CASE REPORT

ŁUKASZ MIGDALSKI[1], *KRZYSZTOF KUZDAK*[2]

Department of General and Vascular Surgery, Pirogow`s Regional Hospital in Łódź[1]
Kierownik: dr med. *J. Okraszewski*
Department of Endocrine and General Surgery, Medical University in Łódź[2]
Kierownik: dr hab. *K. Kuzdak*

Intraabdominal bleeding is a serious surgical problem, particularly in elderly patients following an anticoagulant therapy. It occurs, that abdominal haemorrhage is the first symptom of *hepatocellular carcinoma*, mostly in Asians and Africans, occasionally in Europeans. The article's author shows a case of an elderly man, treated by Acenocumarolum, in a haemorrhagic shock. During an operation a bleeding liver tumor was revealed. The surgical team performed an effectual tumor resection and stoped the bleeding.
Key words: liver tumor, intraabdominal bleeding, hepatocellular carcinoma (HCC), acenocumarolum, anticoagulant therapy

Intraabdominal bleeding always constitutes a significant surgical problem. Especially, in the era of the more and more commonly used anticoagulation therapy, particularly in elderly patients. Bleeding might be a complication of surgical procedures, as well as the consequence of different pathological disorders, such as peptic ulcer disease. Bleeding might also be the first symptom of a hepatic tumor, especially in Far East countries, amounting to 10-26% of cases (1, 2, 3). Hepatocellular carcinoma is the most common, primary malignant tumor of the liver. Approximately 75% of all tumor cases are diagnosed in Asia and Africa (Mongolia, Laos, Gambia, Egypt, Vietnam, Korea) (4). The incidence of hepatocellular carcinoma in Poland is two times lower, as compared to that in Europe (<5/100,000 patients). In 2010, 1416 patients in Poland were diagnosed with the above-mentioned tumor, including 829 men (5). HCC usually develops in case of a cirrhotic liver. Considering the presented study case the liver was macroscopically free of cirrhosis, including abdominal CT. The mechanism of rupture remains to be understood. One theory considers frequent perforations of tumors infiltrating Glisson's capsule (6). In the described case the tumor did not cover the capsule.

CASE REPORT

An 87-year old male patient was admitted to the ER in the early morning hours with severe abdominal pain, that had awakened the patient. He denied nausea and vomiting. The patient denied a history of peptic ulcer disease, myocardial infarction, previous trauma and abdominal pain. He was on anticoagulation therapy (Acenokumarolum), due to permanent atrial fibrillation. Clinically, the patient was conscious, in limited logical and verbal contact, with symptoms of oligovolemic shock – RR 60/40 mm Hg, hear rate – 110/min. Board-hard abdomen with peritoneal signs, without peristalsis. *Per rectum* – no signs of tumor presence or bleeding. Laboratory parameters were as follows: HgB – 9.7mg%, RBC – 3.19 mln/µl, Hct – 28.9%, INR – 2.78, PT – 39.5 sek. The ECG showed no

signs of ischemia. Abdominal ultrasound showed the presence of free fluid, surrounding the spleen, liver, interloop, and in the pelvis. Intensive fluid therapy was initiated and 20 mg of vitamin K administered. After obtaining the patients' written consent he was transferred to the operating room. Explorative laparotomy was performed by means of the median incision, below and above the navel. Intraoperatively, 2400 ml of blood and clots was aspirated. Peritoneal cavity organs were checked, demonstrating that the cause of bleeding was attributed to a ruptured tumor of the right hepatic lobe, 6 cm in diameter (fig. 1, 2). Macroscopically, the tumor was well-demarcated from the liver parenchyma, the surface being smooth. The remaining abdominal cavity organs showed no signs of pathology. The retroperitoneal space was free of hematoma. Enucleation of the tumor within healthy tissue margins was decided upon. After excision, the hepatic surface was subject to coagulation, covered with a sponge containing fibrinogen and thrombin, closed using two layers of mattress sutures (fig. 3). The operated area was subject to drainage. After surgery the patient was intubated and transferred to the ICU. During the initial 24 hours after surgery the patient received 4 units of blood and 2 units of fresh frozen plasma. Diuresis amounted to 2600 ml. The drain showed trace amounts of bloody content. The patient was extubated on the second postoperative day. Control morphology was as follows: HgB – 11.1 g%, RBC – 3.7 mln/µl, Hct – 31.6%, dieresis – 1800 ml. The patient was transferred to the postoperative Surgery Department. The drain was removed on the fourth postoperative day, the patient required blood transfusions, due to anemization (HgB – 7.6 g%, RBC – 2.5 mln/µl, Hct – 22.2%). Further hospitalization was uneventful. Sutures were removed 14 days after surgery the

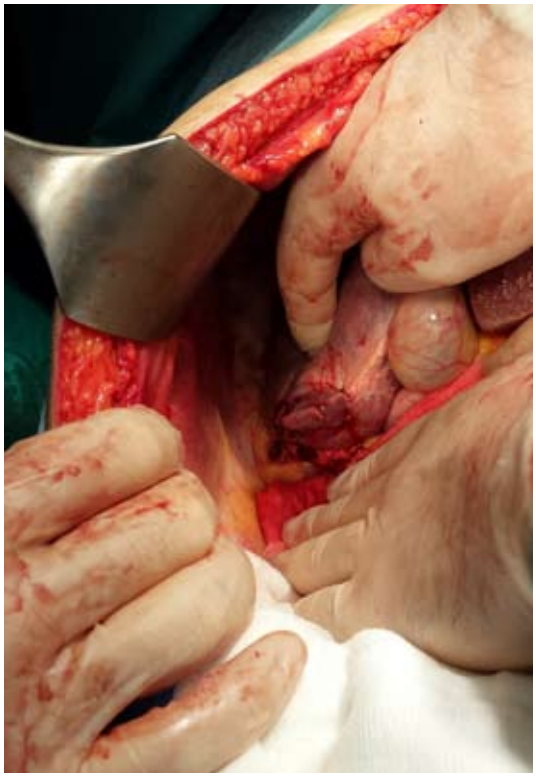

Ryc. 1. Stan po zaopatrzeniu loży po wyciętym guzie
Fig. 1. Supplied site after tumor excision

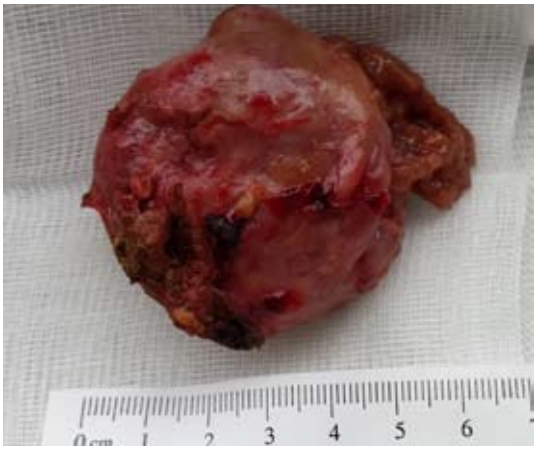

Ryc. 2. Wycięty guz – widok od strony wątroby
Fig. 2. Excised tumor – view from the liver

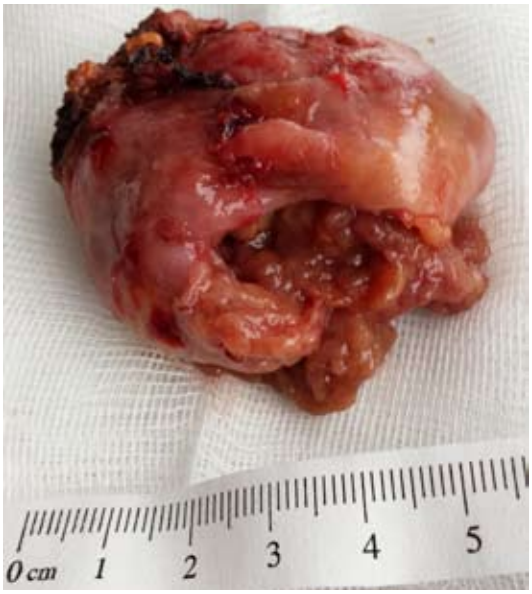

Ryc. 3. Guz wątroby – widok pękniętej torebki guza
Fig. 3. Liver tumor – view of a ruptured capsule

wound healing by first intention. The patient was discharged from the hospital in good general condition 17 days after the operation. The histopathological result was as follows: *„hepatocellular carcinoma G2, lobular and pseudo-adenoma type, not infiltrating the liver capsule"*. Neoplastic markers were within normal limits: AFP – 1.36 ng/ml, CEA – 1.2 ng/ml. Abdominal CT was free of cancer. The patient was subject to oncological consultation, being under observation and periodic control examinations.

DISCUSSION

Most literature data refer to Far East countries. An interesting study was presented by reasearchers from Taiwan. They compared two patient groups, those with ruptured and non-ruptured HCC. They observed statistically significant differences in the size of the tumor – in case of a ruptured HCC the diameter amounted to 9.8 vs 7.6 cm. Furthermore, they discovered that tumors of the left lobe are more likely subject to rupture, and that portal hypertension has no influence on the frequency of rupture (2, 4). Their results differ from that of European authors. The latter showed no statistical difference in the size of the tumor, in comparison to the severity of bleeding (7). The average age of a patient with HCC amounts to 67 years (ranging between 42-84 years) (7). Analysed literature data showed one case of a 62-year old male patient with bleeding, as a consequence of a ruptured liver tumor, with decreased coagulation (INR 2.8) subject to effective setonage (8). The second case concerned a 46-year old female patient on anticoagulation therapy (acenokumarol) subjected to hematoma rupture, successfully removed (9). The description was from Hungary, dating back to 1993, being the first effective resection of a hematoma performed in an adult patient in hemorrhagic shock. Surgeons from Kuwait, used isoamyl 2-cyanoacrylate, a tissue glue, to control bleeding from a ruptured hepatocellular carcinoma, obtaining hemostasis (10).

REFERENCES

1. *Mukesh R, Anupam L, Radha K:* Dhiman Spontaneous Rupture of Hepatocellular Carcinoma. *J Clin Exp Hepatol* 2014 Jun; 4(2): 188–189.
2. *Chen CY, Lin XZ, Shin JS* et al.: Spontaneous rupture of hepatocellular carcinoma. A review of 141 Taiwanese cases and comparison with nonrupture cases. *J Clin Gastroenterol* 1995 Oct; 21(3): 238-42.
3. *Miyamoto M, Sudo T, Kuyama T:* Spontaneous rupture of hepatocellular carcinoma: a review of 172 Japanese cases. *Am J Gastroenterol* 1991 Jan; 86(1): 67-71.
4. http: //www.wcrf.org/int/cancer-facts-figures/data-specific-cancers/liver-cancer-statistics
5. http: //onkologia.org.pl/nowotwory-watroby-przewodow-zolciowych-wewnatrzwatrobowych-c22/
6. *Yoshida H, Mamada Y, Taniai N, Uchida E:* Spontaneous ruptured hepatocellular carcinoma. *Hepatol Res* 2015 Jan 29.
7. *Recordare A, Bonariol L, Caratozzolo E* et al.: Management of spontaneous bleeding due to hepatocellular carcinoma. *Minerva Chir* 2002; 57: 347-56.
8. *Onur OO, Guneysel O, Saritemur M, Denizbasi A:* Spontaneous rupture of hepatocellular carcinoma presented as low back pain to an emergency department: a case report. *BMJ Case Rep.* Epub 2009 Feb; 26.
9. *Oláh A, Acs M, Mátrai T:* Rupture of a giant hematoma of the liver as a complication of anticoagulant therapy. *Orv Hetil* 1993 Feb 14; 134(7): 359-62.
10. *Al-Fraij AK, Dhar PM, Al-Khalejy A, Abu Najem F:* Massive hemorrhage from spontaneous ruptured hepatocellular carcinoma controlled by isoamyl 2-cyanoacrylate: a case report. *Med Princ Pract* 2011; 20(3): 297-99.

Received: 20.08.2015 r.
Adress correspondence: 91-537 Łódź, ul. Wólczańska 191/195
e-mail: drmigdalski@gmail.com