INDEX COPERNICUS INTERNATIONAL

ORIGINAL ARTICLE

Microvascular nose reconstruction after extended tumor resection

Authors' Contribution:
A – Study Design
B – Data Collection
C – Statistical Analysis
D – Manuscript Preparation
E – Literature Search
F – Funds Collection

Łukasz Krakowczyk[ABEF], Cezary Szymczyk[AD], Janusz Wierzgoń[DF], Krzysztof Oleś[B], Dominika Smyczek[E], Rafał Ulczok[E], Karolina Donocik[AF], Grzegorz Hadasik[BF], Agnieszka Piotrowska[A], Adam Maciejewski[AE]

Department of Oncological and Reconstructive Surgery, National Oncology Institute Maria Skłodowskiej-Curie, National Research Institute, Gliwice Branch, Poland

Article history: Received: 04.03.2020 Accepted: 25.05.2020 Published: 26.05.2020

ABSTRACT:

Introduction: The nose is the central and probably the most important organ of the face. In view of the three-dimensional shape and variety of tissues, reconstructive surgery after tumor resection in this anatomical region requires the surgeon's knowledge of anatomy.

Materials and Method: In the years 2010–2019, 48 patients were treated in the Oncological and Reconstructive Surgery Clinic for extended nasal tumors, which required the use of free microvascular flaps after resection for functional and aesthetic supply of anatomical structures of the nose.

Results: In 48 patients, a total of 92 free microvascular flaps were used for nasal reconstruction including: radial forearm free flap in 24 patients, radial forearm free flap with radial bone in 14 patients, auricular free flap in 16 patients, radial forearm free flap in combination with auricle free flap in 7 patients, double auricular free flap in 6 patients, radial forearm free flap in combination with double auricular free flap in 4 patients. Total necrosis of the free flap was noted in 4 cases, partial in 6 patients.

Conclusions: The presented surgical techniques using microvascular free flaps constitute a recognized method of treatment and should be used in everyday surgeon practice. The results demonstrated in this article allow to obtain optimal functional and aesthetic effects.

KEYWORDS: free flaps, head and neck, nasal cancer, nasal reconstruction

ABBREVIATIONS

HNCG – Head and Neck Cancer Group
VAC – Vacuum Assisted Closure

INTRODUCTION

The history of nasal tissue reconstruction goes back several thousand years. The first reconstructions were most likely made during the fourth Egyptian dynasty (2575–2467 BCE). Back then, people believed in the purposefulness of using nose prostheses in the deceased as: "only those without physical handicaps could enter the kingdom of Osiris". Pedicled flaps of skin in the vicinity were supposedly used in India as early as 3–4 thousand years BCE, which resulted from the custom of cutting off the noses of convicts and prisoners of war. The first record of tissue flaps appears as a description of the anterior medial flap in the treatise "Ayuer Veda" by Sushrut Samhit (Indian text of the Vedic period 1000–600 BC). According to this manuscript, the basis for the formation of an appropriate shape of the frontal flap was a leaf placed on the forehead, reproducing the shape of the nasal defect [1]. The external nose is made up of three layers: (1) the outer portion, made up of skin, muscles and fascia, (2) the middle portion, i.e. nasal scaffolding (bony and cartilaginous elements) and (3) internal portion, which is the skin in the nasal vestibule, and behind the nasal vestibule – the mucosa (separated from the skin by the so-called threshold of nose). The following are distinguished in the nasal scaffolding: (1) a fixed bony portion that is formed by the nasal bones and the frontal processes of maxilla, and (2) a movable cartilage portion that consists of a cartilaginous portion of the nasal septum, alar and lateral cartilages. The bony portion of the nasal septum is located deep inside the skull and does not belong to the outer nose. Currently, surgical techniques used in nasal reconstruction for resection of cancerous tumors involve a wide range of options for covering the postoperative defect, of which one of the two main groups of reconstructive methods is most often used: locoregional techniques or free flaps, which have become the gold standard in the treatment of extensive defects of this organ [2]. In some particularly advanced clinical cases, combinations of both techniques are used. The main indication for reconstructive procedures in the nose are defects after radical nasal cancer resection, the most common of which are: basal and squamous cell carcinomas (including spinocellular carcinoma), accounting for 75% of all types of skin cancers, and melanoma, the latter being a tumor derived from melanocytes (pigment cells) which can grow in all sites where these cells are present. The most common of the discussed neoplasms – basal cell carcinoma – occurs within the scalp and neck in over 80% of cases, while 25% involve the nose [3]. Despite attempts to use treatments other than surgery, radical excision of the lesion remains the treatment of choice in almost every case. The width of the healthy tissue margin, as an effect of radical excision of the lesion, is still a subject of lively debate among many authors, whereby almost all agree that it should depend on the extent of neoplastic infiltration and histological type. Therefore, the width will vary for basal cell carcinoma, squamous cell carcinoma, or melanoma. Unfortunately, to date no specific guidelines and strict dimensions of the margin of healthy tissue for

INDEX COPERNICUS INTERNATIONAL

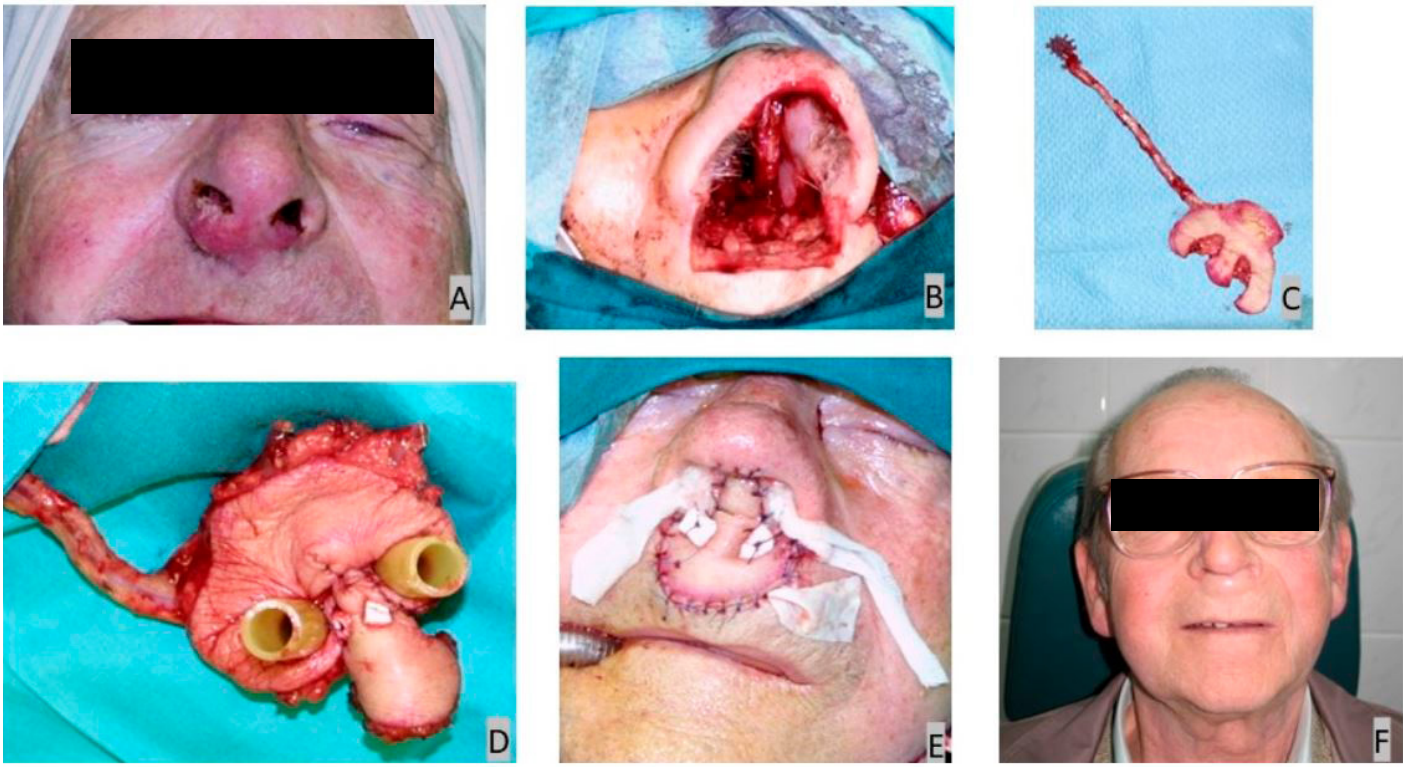

Fig. 1. (A) Patient with squamous cell carcinoma, extending to: upper lip, nasal columella and septum, and the bottom of nasal fundus; (B) status after radical nasal resection; (C, D) formed and shaped radial flap; (E) status after reconstruction with radial flap; (F) patient 6 months after surgery.

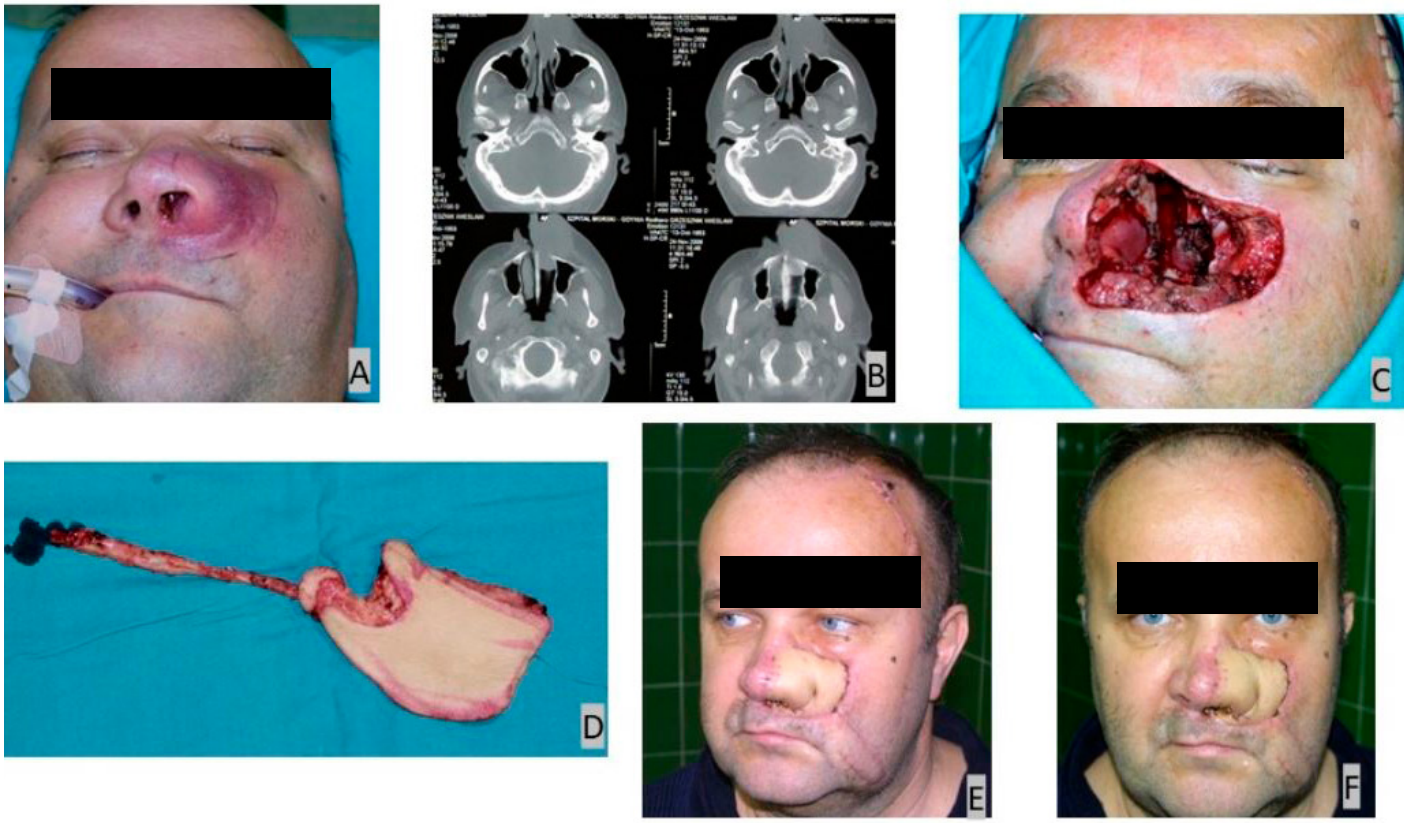

Fig. 2. (A) Patient with squamous cell carcinoma, extending to: cheek, upper lip and left half of nose; (B) computed tomography imaging of tumor; (C) status after radical tumor resection; (D) free radial flap generated using allogeneic cartilage; (E, F) early postoperative effect.

DOI: 10.5604/01.3001.0014.1543

individual types of skin cancer have been established, and even several authors laconically state that the tumor should be removed within the broadly understood limits of healthy tissues. Simply put, the healthy tissue margin recommended by many authors, certainly depending on the size of the neoplastic infiltrate and penetration into the surroundings and "deep" into the tissues, is: in basal cell carcinoma – 2–10 mm, in squamous cell carcinoma – 4–6 mm; however in melanoma, maintaining the recommended margin (1 cm per 1 mm of the infiltration depth) within the face seems rather unlikely [4].

PURPOSE OF PAPER

The aim of the study is to present the methods of reconstructive surgery using microvascular free flap as an effective treatment after extensive resection of nasal tumors.

METHODS AND MATERIAL

In the years 2010–2019, there were 48 patients treated in the Department of Oncological and Reconstructive Surgery due to extensive nasal neoplasms, which required the use of microvascular free flaps following resections for the purpose of functional and aesthetic supply of the anatomical structures of the nose. Histopathological diagnosis of the tumor was obtained in each patient qualified for surgery by the Head and Neck Cancer Group (HNCG), where the scope of tumor resection was determined, followed by the Reconstructive Team, which planned the type of free flap. Four weeks after release from the clinic, the patients had another consultation at the HNCG, where a strategy for further treatment was established. In this group of patients, simultaneous surgery was performed by two two-man surgical teams, i.e. one team performed the resection, while the other collected a free flap for reconstruction. In cases which involved the collection of a free flap from the auricle, this tactic was impossible due to the proximity of the operating fields. The radial flap was always based on the radial vessels that were prepared towards the cubital fossa. In 14 patients, $^{1}/_{3}$ of the circumference of the radial bone from 5–8 cm was also collected to obtain the dorsal frame and the columella. In the remaining cases which required the formation of a soft tissue flap, a frame was used with the application of costal cartilage or a cartilage allograft sourced from a cadaver. The auricular flap was based on superficial temporal vessels, and its size and component depended on the postresective defect. This flap was used to recreate the ala of nose and the columella. The main vessels used for anastomoses are the facial vessels or their branches. The arterial vessels were anastomosed with a 10.0 manual suture, and the venous vessels with a vascular stapler with a diameter of 1 mm to 3 mm.

RESULTS

In 48 patients operated in our clinic who required the application of microvascular techniques, a total of 92 free flaps were used, including: a radial flap in 24 patients (Fig. 1.), radial flap with a fragment of the radius or with costal cartilage in 14 patients (Fig. 2.), auricular flap in 16 patients (Fig. 3.), combination of radial flap and auricular flap in 7 patients (Fig. 4.), combination of radial flap and two auricular flaps in 4 patients (Fig. 5.), double auricular flap in 6 patients (Fig. 6.). The donor sites following auricular flap were managed primarily. The forearm donor sites required a split-thickness thigh graft and the application of vacuum therapy dressings (VAC). Histopathological diagnosis revealed basal cell carcinoma in 54% of cases, squamous cell carcinoma in 39%, skin appendage carcinoma in 4%, and melanoma in 2%. Despite the intraoperative histopathological examination of tumor bed margins and negative results of intraoperative examination of tumor margins by histopathologists (intry), macroscopic radicality of surgery was achieved in all patients, and microscopic radicality in 42 patients. In 6 patients, in whom the procedure was not radical and involved the diagnosis of basal cell carcinoma, adjuvant brachytherapy was used. Each patient diagnosed with squamous cell carcinoma was subsequently treated with radiotherapy. Eight patients had venostasis in the free flap in the postoperative course and required revision surgery. Despite revision and obtaining venous outflow, complete necrosis of the free flap was observed in 4 cases, and partial necrosis was present in 6 individuals, who required revision surgery with the use of local plastics or pedicled flaps. The final satisfactory functional and aesthetic effect was obtained in all persons, as shown in the figures.

DISCUSSION

The scope of nasal reconstruction with the use of free microvascular flaps depends on the extent and complexity of resection. It should be individually and precisely planned each time before starting surgery. In the case of extensive defects involving the entire external nose (i.e. skin, subcutaneous tissue, nasal bones and nasal cartilage), multi-stage techniques based on the use of free flaps with the use of costal cartilage grafts or allografts, a fragment of the radius, and also prelamination of artificial materials should be used.

The most frequently used free flap in the complex reconstruction of both the outer and inner nose is radial free flap with own costal cartilage or such sourced from a cadaver. With a large number of skin perforators along the entire radial artery pedicle, it is possible to create several independent islands for isolated reconstruction of the septum, nasal vestibule and internal nose, whereby their size, shape and number depend on the characteristics of its analogous parts [5].

The authors of many papers present the most refined operating techniques with their detailed description [6]. Reconstruction of the entire nose, including the internal and external portions, involves typical preparation of the vascular pedicle together with three cutaneous islands, and the quantity and quality of cutaneous perforators in the radial flap allow for such division of the cutaneous islands that their subsequent rotation and displacement relative to each other allows for three-dimensional reconstruction of both the nasal vault, the septum and the bottom of nasal fundus. The next stage of the procedure consists in combining "slimmed" skin islands with a cartilage frame (from own ribs or allogeneic cartilages sourced from deceased donors). The outer surfaces of the skin islands are temporarily covered with split-thickness skin grafts, taken mostly from the thigh area. Vascular anastomosis of the radial flap pedicle is performed with the facial or temporal vessels, with the vascular anastomosis moving in the tunnel of the subcutaneous tissue. The final stage of the first part of the

Fig. 3. (A) Patient with basal cell carcinoma of the right ala of nose; (B) status after tumor resection and preparation of donor vessels; (C) planning of free auricular flap based on the superficial temporal vessels; (D) free flap collected from auricle; (E) status after microvascular anastomosis; (F) status after reconstruction of postresective defect; (G, H). patient 3 months after surgery with visible donor site.

Fig. 4. Patient with basal cell carcinoma of the nose and cheek. (A) status after tumor resection of the left nasal ala, part of the cheek and upper lip; (B) serial connection of radial flap to auricular flap; (C) status after reconstruction; (D, E) patient 6 months after surgery; (F, G) one year after resection and reconstruction surgery.

Fig. 5. (A, B) Infiltration of squamous cell carcinoma involving the entire nose; (C, D) reconstruction of the entire nose with three free flaps: one radial and two auricular flaps; (E, F) patient three months after surgery; (G) use of glabellar flap to recreate the correct texture and shape of outer nose; (H, I) patient after another nose correction.

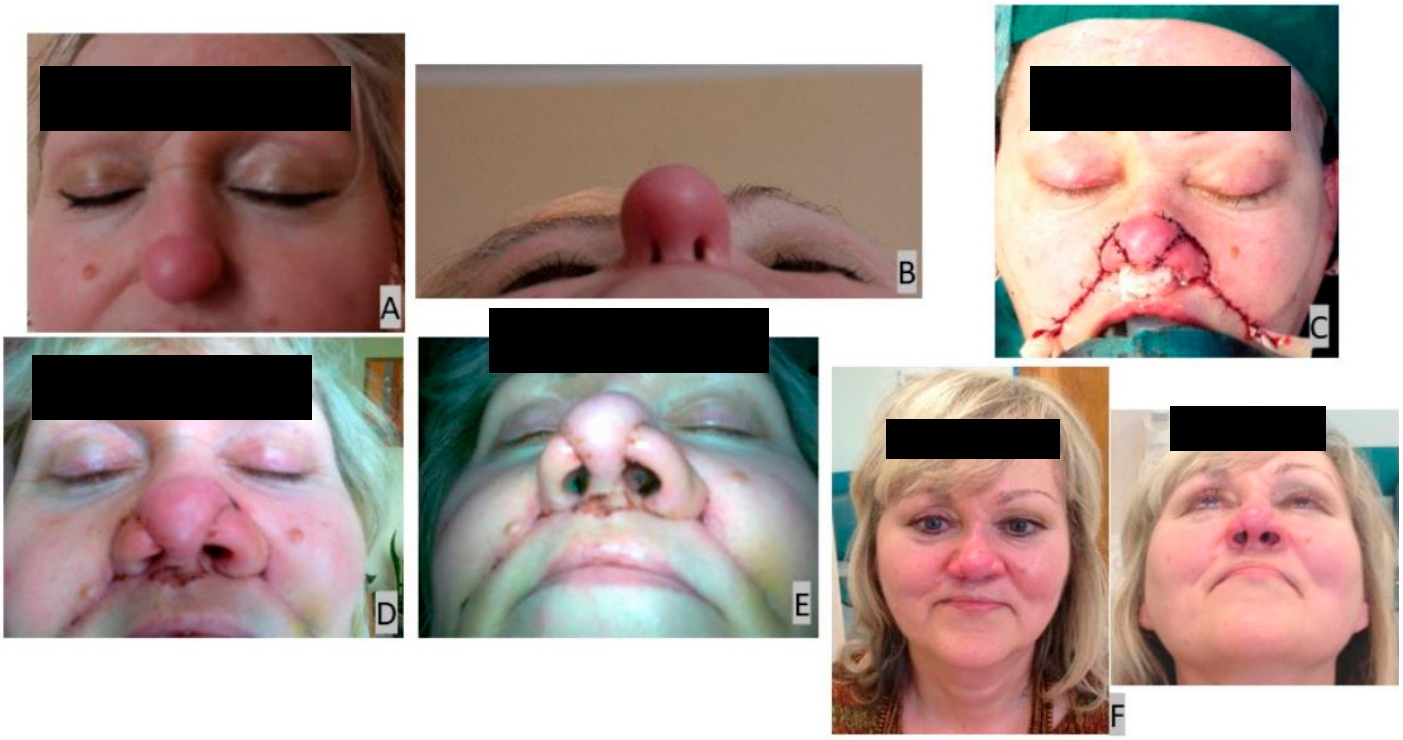

Fig. 6. (A, B) Patient after numerous nose reconstructions outside our center, with closure of nasal passages; (C) status after nasal reconstruction using two free auricular flaps; (D, E) early postoperative effect; (F) patient six months after surgery.

procedure is to insert silastic tubes into the nasal passages and fill them with setons with neomycin. The above-described first stage of nasal reconstruction is the most important to obtain the optimal aesthetic and functional effect. Further steps are only aimed at correcting the previous version and improving the appearance of the outer nose. Approximately 8 weeks after the primary surgery we plan the next stage of external nasal reconstruction, which consists in creating and implanting a frontal pedicled flap based on supratrochlear vessels; this is to ensure correct skin color and symmetrical shape of the nose. Sometimes an expander is implanted in this area in order to obtain a larger surface of skin during the first stage. In practice, after removing the previously used skin grafts, the frontal flap moves to the previously formed complex, further improving the arrangement and shape of the cartilages, as well as modeling the tip and the ala of nose. After another 4 weeks, in the next stage of reconstruction the patient is readmitted for incision of the pedicle of the frontal flap and widening of the nasal passages. Sometimes, in order to achieve an optimal aesthetic effect, the patient requires further corrections and improvement of the shape and symmetry of the nasal ala by means of local plastics, slimming and shaping of the frontal flap. The above-described method of total nasal reconstruction is just one example of a multi-step technique based on the use of a free skin flap to recreate the inner nose in combination with cartilage and frontal flap. The shape and size of cutaneous islands of the radial flap have evolved over the last 25 years from a single bat-shaped island through double islands planned in the form of regular polygons to the three-island version proposed above [6]. This complicated path shows the complexity of reconstruction of the whole nose and difficulty in obtaining an excellent result. In the case of limiting defects involving only the soft tissues of the outer nose with partial preservation of the cartilage frame, single-step techniques using a radial flap or other thin skin flap are preferred. After the radial flap has been removed, the donor site is usually provided with split-thickness skin grafts.

In defects involving the ala of nose together with the cutaneous septum and nasal cartilage (nasal columella), the method of choice is a free flap of the auricle based on the superficial temporal artery. An asset of this flap is its perfect resemblance to the curvature of the nasal ala (the left ear lobe reproduces the right ala of nose and vice versa). In patients who require reconstruction of both nasal ala together with the nasal bridge, two free flaps from both auricles can be used. If the postresective defect extends to the surrounding tissues of the upper lip and/or the cheek, this flap can also be taken with an element of the skin in the preauricular and postauricular area. In justified cases (loss of a large part of the lateral wall of the nasal cavity and cheek), the auricle connects with the radial flap, creating an artificial chimera structure (serial connection of the proximal end of the ear lobe with the distal segment of the radial flap) [7]. Cases of particularly extensive resections of the entire nose may involve the use of a combination of three free flaps: a radial flap with two auricular flaps. Here, the main drawback is the short vascular pedicle, approx. 3–4 cm long, which therefore requires microvascular anastomosis with recipient vessels in the nasobuccal fold [8].

CONCLUSIONS

The results presented in the study confirm the possibility of efficient microvascular free flaps in nasal reconstruction, which enabled obtaining satisfactory functional and aesthetic effects. The introduction of microvascular free flaps permitted resection of the tumor with normal and sufficient margins of healthy tissues, while obtaining appropriate macroscopic and microscopic margins without fear of the lack of possibilities of treatment and causing injury to the patient. Due to the lack of homogenous standards and algorithms in nasal reconstruction, the surgeon is often left to his own knowledge, skills and creative thinking. The above-described surgical techniques should be applied in everyday medical practice of surgeons.cular flaps depends on the extent and complexity of resection. It should be individually and precisely planned each time before starting surgery. In the case of extensive defects involving the entire external nose (i.e. skin, subcutaneous tissue, nasal bones and nasal cartilage), multi-stage techniques based on the use of free flaps with the use of costal cartilage grafts or allografts, a fragment of the radius, and also prelamination of artificial materials should be used.

REFERENCES

1. Menick F.J.: Nasal Reconstruction. Plast. Reconstr. Surg., 2010; 125: 1–9.
2. Pabla R., Gilhooly M., Visavadia B.: Total nasal reconstruction using composite radial forearm free flap and forehead flap as a one-stage procedure with minor revision. Br. J. Oral and Maxillofacial Surg., 2013; 662–664.
3. Menick F.J., Salibian A.: Microvascular Repair of Heminasal, Subtotal, and Total Nasal Defects with a Folded Radial Forearm Flap and a Full-Thickness Forehead Flap Plast. Reconstr. Surg., 2011; 127: 637.
4. Mathy J., Pribaz J.: Prefabrication and Prelamination Applications in Current Aesthetic Facial Reconstruction. Clin. Plastic Surg., 2009; 493–505.
5. Burget G.C., Walton R.L., Môle B.: Complete aesthetic reconstruction of nose and adjacent facial units with optimized use of free flaps, cartilaginous grafts and forehead flap combinations. Ann. Chir. Plast. Esthet., 2009; 54(6): 497–522.
6. Burget G.C., Walton R.L.: Optimal use of microvascular free flaps, cartilage grafts, and a paramedian forehead flap for aesthetic reconstruction of the nose and adjacent facial units. Plast Reconstr. Surg., 2007; 120(5): 1171–1207.
7. Walton R.L., Burget G.C., Beahm E.K.: Microsurgical reconstruction of the nasal lining. Plast. Reconstr. Surg., 2005; 115(7): 1813–1829.
8. Degner D.A.: Facial reconstructive surgery. Clin.Tech. Small. Anim. Pract., 2007; 22(2): 82–87.

Word count: 2 732 Page count: 7 Tables: – Figures: 6 References: 8

DOI: 10.5604/01.3001.0014.1543 Table of content: https://ppch.pl/issue/13341

Competing interests: The authors declare that they have no competing interests.

Corresponding author: Łukasz Krakowczyk MD PhD, prof. COI; Department of Oncological and Reconstructive Surgery, National Oncology Institute Maria Skłodowskiej-Curie, National Research Institute, Gliwice Branch; Wybrzeże Armii Krajowej street 15, 44-100 Gliwice, Poland; Phone: +48 606 729 785; E-mail: lukaszkrakowczyk@wp.pl

Cite this article as: Krakowczyk L., Szymczyk C., Wierzgon J., Oles K., Smyczek D., Ulczok R., Donocik K., Hadasik G., Piotrowska A., Maciejewski A.: Microvascular nose reconstruction after extended tumor resection; Pol Przegl Chir 2020: 92 (5): 1-7