ORIGINAL ARTICLE

INDEX COPERNICUS INTERNATIONAL

The results of the treatment of hand – Outcomes of the treatment of hand degloving injuries with greater omentum flaps

Andrzej Żyluk

Department of General and Hand Surgery, Pomeranian Medical University in Szczecin; Head of the Clinic: Prof. Andrzej Żyluk

Article history: Received: 16.10.2017 Accepted: 30.10.2019 Published: 31.10.2019

ABSTRACT: Degloving injury involves stripping away the soft-tissue integument covering the skeleton of the hand: skin and subcutaneous tissues as well as accompanying nerves and blood vessels. Degloving of the entire hand is one of the injuries associated with the poorest prognosis, even worse than total hand amputation. There is a limited range of possible salvage procedures in such cases and their outcomes are unsatisfactory. One of such methods involves wrapping of the skinned hand with a pedicled or free greater omentum flap retrieved from the abdominal cavity. In this publication we report the outcomes of treatment in 5 patients 8 years on average after total hand degloving and repair using omental flaps. All flaps healed uneventfully, but the whole length of the fingers could not be preserved in any of our patients. Stumps of 3 fingers were separated in one patient, three-digit hands were formed in two others and the thumb alone was isolated in the remaining two patients. Dexterity of injured hands was limited with a mean DASH questionnaire score of 43 points. Quality of life as measured by the SF-36 questionnaire was poor (58 and 53 points in physical and mental domain, respectively). Nevertheless, all patients were satisfied with the achieved outcomes and all returned to work, which corroborated the effectiveness of the used treatment method.

KEYWORDS: degloving injury, hand reconstruction, omental flap, soft tissue loss

INTRODUCTION

With regard to the extent of tissue damage, degloving can only be compared to widespread crushing injury to the hand. It involves tearing of hand's soft tissues: skin and subcutaneous tissues, including nerves and blood vessels, off the bone skeleton. The most commonly separated tissue complex has the appearance of an old glove (hence, the name of the injury – degloving), may remain attached to the skeleton at the mid- or distal-phalangeal level in an incomplete degloving or be completely separated (Fig. 1., 2.). Separation usually occurs at the level of the wrist, and only muscles and tendons remain attached to the osseous skeleton. The natural behavior of any surgeon in such a situation is to slip the separated soft tissues back into the bones and to suture them at the site of laceration – at the wrist. Unfortunately, after 2–3 days the skin and subcutaneous tissue inevitably die, and after dissecting necrosis, only the finger bones, metacarpal tendons and muscles remain, returning to the state before the injury (Fig. 3., 4., 5.).

In this situation, there are few rational solutions to choose from: surgeon can amputate the hand at the wrist level or to sew it into the abdominal wall, hoping to excise it later together with the skin of the abdomen. However, both of those solutions are bad. Techniques of tissue complex replantation and coverage of hand bones with a combination of several free and pedicle flaps described in the literature require knowledge of very difficult microsurgical techniques and the skills to transfer tissue complexes, which are virtually inaccessible in our country [1, 2, 3]. Omental flap is a compromise that could offer a chance of rescuing at least a part of the hand. Size is its greatest advantage: greater omentum is the size of a medium format newspaper, allowing wrapping of the whole hand. A greater omentum flap does not require microsurgical skills, as is dissected in the abdomen. Indications for the flap include extensive soft tissue loss involving the upper limbs, which are difficult to cover with standard techniques. The aim of this study was to assess the long-term results of the treatment of hand degloving injuries by covering them with pedicled greater omentum flaps.

MATERIAL AND METHODS

Twelve patients (13 hands) with complete (n = 7) or partial (n = 6) hand degloving have been treated in our clinic with the use of greater omentum flaps to cover the hand between 1998 and 2012. The group consisted of 11 men and 1 woman (mean age 34 years; range: 18–48). One patient (the youngest) suffered an injury to both hands. In all cases, the injury was caused by entrapment of the hand by a fast rotating (swirling) rollers of a crushing machine or a press (for metal, cardboard or other materials). All of those accidents were work-related. Patients were brought into the hospital within a few hours of trauma and operated on the same day.

The first surgery was an attempt to cover the hand bones with skin and subcutaneous tissue – pulling it over the hand and sewing it to the skin at the wrist. Three patients had associated fractures of the metacarpal bones and phalanges, which were stabilized using K-wires. In all cases, the originally transferred soft tissues became necrotic and required debridement, which produced the same result as was observed immediately after the trauma. Therefore, tissue debridement with covering of the hand skeleton with a flap from the greater omentum was performed after 3 to 5 days.

DESCRIPTION OF SURGICAL TECHNIQUE AND POSTOPERATIVE MANAGEMENT

The procedure is carried out under general anesthesia, without limb ischemia. The first stage of the surgery consisted of debride-

DOI: 10.5604/01.3001.0013.5495

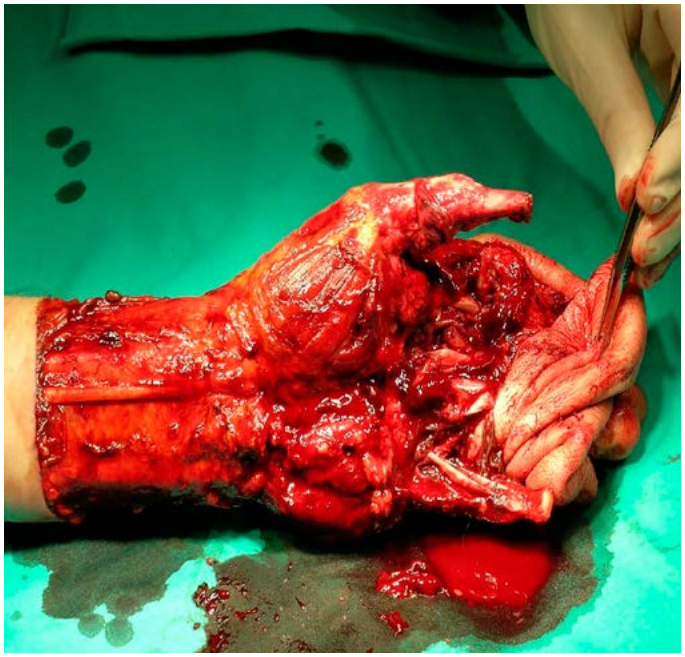

Fig. 1. Total degloving.

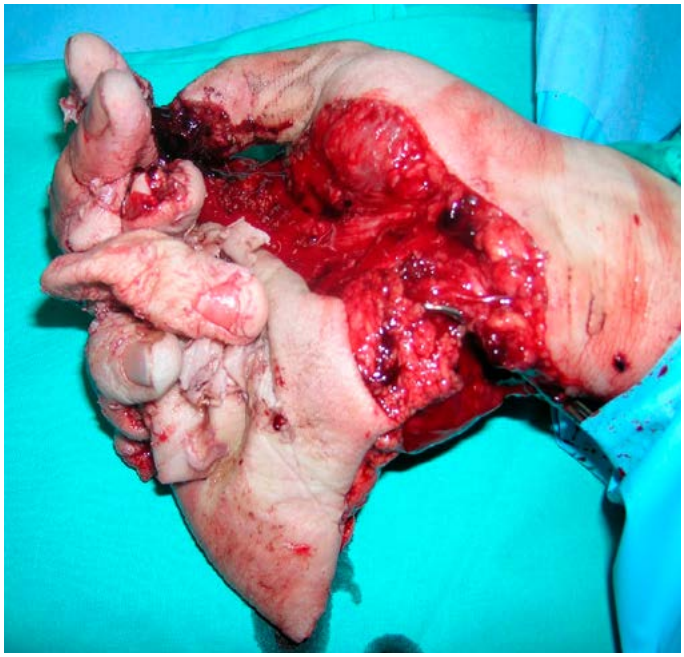

Fig. 2. Partial degloving and crushing of the hand.

Fig. 3. Necrosis of the repositioned skin.

Fig. 4. Image of „degloved" hand after the excision of necrotic tissues.

ment, which is an excision of dead tissues of the hand. Usually, it exposes the skeleton and tendons (Fig. 4., 5.). Subsequently, a 4 to 5 cm laparotomy incision is performed in the midline, above the umbilicus. Transverse colon is identified in the abdomen together with the greater omentum, which is then pulled out through the wound. A single artery is selected within the greater omentum, usually the right gastroepiploic, which will become the supplying vessel of the flap. The greater omentum is dissected around it and separated from the lower edge of the transverse colon. After dissection, the flap should be pedicled on a fragment of omentum the thickness of a finger (Fig. 6.). The wound is closed with layered sutures, taking care not to put too much pressure on the stalk. The bones of the hand are wrapped over with an omental flap, which is sewn into the residual tissues to ensure proper anchoring. After covering the entire hand with the omentum, the fingers II–V are separated from the thumb (Fig. 7.). Following surgery, the flap is covered with an anti-adhesive dressing. Particular attention should be paid to the flap stalk, which must not bend under the weight of the limb in supine position or stretch excessively when the patient is standing. At the Department of General and Hand Surgery at the Pomeranian Medical University in Szczecin, we support the wrist with a gauze padding to ensure straightening of the flap. Also, a fitting strap of adhesive tape is placed under the wrist, so that the limb does not fall in an upright position.

POSTOPERATIVE MANAGEMENT

Dressings must be changed every day, because the greater omentum produces serous fluid. After approximately one week, if the

Fig. 5. Image of the hand after excision of necrotic tissues and removal of a "glove".

Fig. 6. Greater omentum flap prepared for wrapping of the degloved hand.

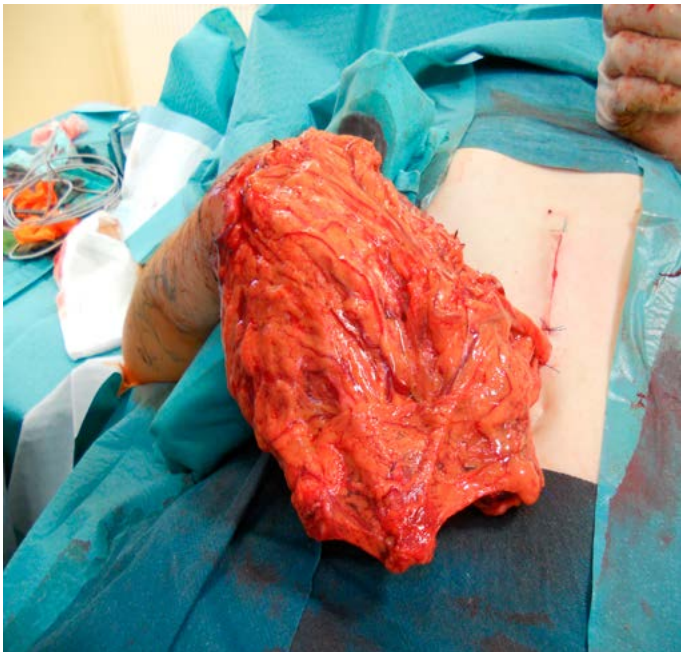

Fig. 7. Hand skeleton wrapped in a pedicled flap.

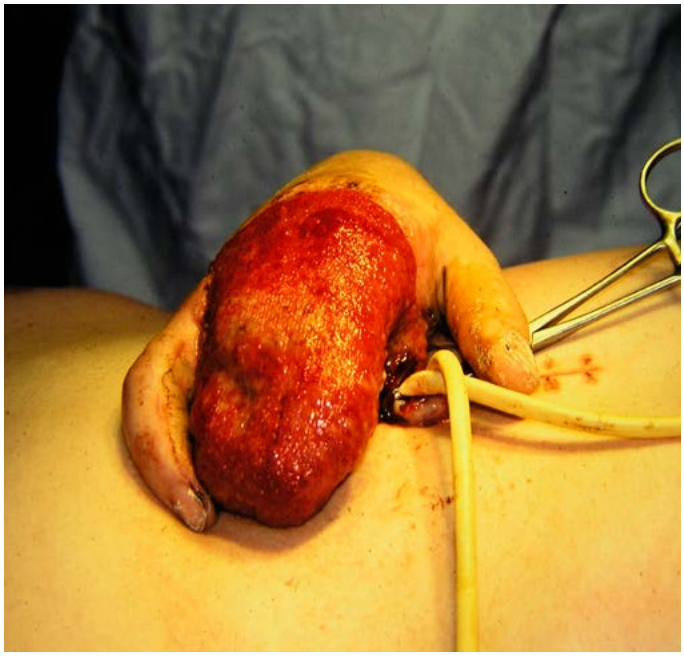

Fig. 8. A healed omental flap covering the degloved fingers prepared for being cut off.

healing proceeds without complications, patient becomes accustomed to the new situation and can be safely discharged home to ambulatory care at the place of residence. Majority of patients manage the changes of dressings well and protect the flap from external damage.

FLAP EXCISION AND COVERAGE OF GRANULATION TISSUE WITH A SKIN GRAFT

After approximately 3 weeks the patient is readmitted to hospital, where the stalk is cut off from the healed flap, covered with pink granulation tissue (Fig. 8.). Surgery is performed under general anesthesia, because a skin graft must be placed on the granulation tissue. The flap is cut off with an electric knife, vessels are ligated, and the stalk is buried under the skin of the abdomen. Using a dermatome, a relatively large amount of split-thickness skin is collected (usually 2–3 strips, 15 cm in length), which is "reticulated" with a perforator. Such a reticulated graft is placed over the granulation tissue covering the hand (Fig. 9.). Often, the distal phalanges (including the thumb) stick out of the granulation tissue and protrude over it. In such a case, they should be amputated. A transplant-covered hand should be managed the same way as after conventional skin transplantation. After the skin is healed and therapy is finished, the hand rarely looks good, although patients are usually satisfied with the effect. When the omentum shrinks, which usually takes place after about 3 months, one may consider separation of fingers II–V, but it is rarely successful. Some patients recover at least partial dexterity of their hand, but for most it is merely a stump.

Fig. 9. After cutting off the flap, granulation tissue is covered with skin grafts.

Fig. 10. A good grip in the patient after successful splitting of the stumps of 3 fingers.

Fig. 11. Poor outcome in a patient with a "three-finger" hand.

Fig. 12. Hand after separation of the thumb only.

Only 5 of 12 patients after hand degloving treated with omental flaps presented to follow-up. The remaining 7 did not respond to the letters. Mean time from surgery to follow-up was 8 years (range: 5–12). Study group consisted of 4 men and one woman aged 41 years on average (range: 33–54). Patients were examined with regard to the range of mobility of finger stumps, grip strength, hand dexterity acc. to the DASH questionnaire and the quality of life as measured by the SF-36 questionnaire.

DESCRIPTION OF QUESTIONNAIRES USED IN THE STUDY

The DASH (Disability of Arm, Shoulder and Hand) Questionnaire is a 30-point test for self-assessment of upper limb function used to determine limb dexterity. Each question is evaluated on a scale of 1 to 5, with 1 being the absence of symptoms or performing tasks without difficulty, and 5 meaning persistence of symptoms or failure to perform a task. The scoring range is between 0 and 100, with fewer points corresponding to the overall better dexterity and higher number of points linked to poorer upper limb performance. The range 0–20 means full dexterity, range of 21–40 to mild impairment, 41–60 – moderate impairment, and >60 – significant limb disability.

The SF-36 (36-Item Short-Form Health Survey) Questionnaire is an instrument designed to assess the quality of life. It consists of 36 questions grouped into 8 categories that enable evaluation of 8 dimensions of the quality of life. The results are usually presented as scores in 2 domains: physical (4 categories) and mental (4 categories). Answers to each question are assigned weights that as-

sume values from 0 to 100. Then, the result on a 100-point scale is obtained in each of the 8 categories. The higher the score in the SF-36 questionnaire, the better the quality of life. Range 84–100 corresponds to very good, 61–83 to good, 25–60 to moderate, and <25 to poor quality of life.

RESULTS

Healing of the flap and covering of the degloved hand with omental flap with subsequent skin grafting was successful in all cases (12 patients, 13 hands). Medical records show that, in addition to the 2 primary surgeries (covering with omental flap and skin grafting), all patients had 3 to 6 surgeries to improve the appearance and/or function of the hand. Among the 5 people who showed up to the follow-up, 3 underwent surgery on the left and 2 on the right hand. In one patient with degloving injury of fingers II–IV and subsequent coverage with omental flap and skin grafting, the stumps of all operated fingers were successfully separated (Fig. 8., 10.). A three-fingered hand was formed in two cases (Fig. 11.), and in other cases the thumb was separated from finger stumps, which remained fused, resulting in an appearance of a boxing glove (Fig. 12.).

The range of motion of fingers II–IV was 70° in one patient, and 45° in two patients with a three-fingered hand; The other two, with only a thumb separated from the metacarpus, had no finger mobility, but could grasp some objects (Fig. 12.). Grip strength was measured using a Jamar dynamometer; it was 15 kg (34% of healthy hand strength) in one patient, and in two with three-fingered hands – 5 and 8 kg, respectively. Average DASH questionnaire score amounted to 43 (range 23–86), corresponding to moderately impaired hand function. The best hand dexterity was achieved in a patient after separation of 3 finger stumps (23 points), and the worst in the two patients who only had a thumb separated from the metacarpus – 78 and 80 points. In both cases, amputation involved the dominant limb. Average SF-36 questionnaire score in the physical domain was 58 points (moderate, bordering on good quality of life), and in the mental domain – 53 points (moderate quality of life). The two patients with the worst hand dexterity also judged the quality of their lives the worst: in the physical domain – 22 and 31 points (poor and moderate, bordering on poor), and in the mental domain – 16 and 20 points (poor quality of life). All patients returned to work, but none to the previously performed vocations. In 3 cases their employers offered them work in the same organization, but at another, less demanding position.

All patients underwent at least 3 surgeries to improve the function or the appearance of the reconstituted hand. They usually involved separation of the fused fingers, which required the use of split-thickness skin grafting. Another type of surgery was the "slimming" of fingers and the hand (debulking), by excision of excess fat tissue. These procedures were performed in patients with relatively thick, fatty omentum, but not earlier than one year after the injury, because during this time an innate contraction of the transferred tissues takes place.

In any case, no intraperitoneal infection associated with the presence of the pedicled flap was observed. Some patients reported an unpleasant cramping abdominal pain during treatment, which was easily resolved by muscle relaxant drugs. In 2 of 12 people, a small hernia developed within a year from surgery at the place where pedicle passed through the abdominal wall, but it was resolved using a low-tension technique.

DISCUSSION

Covering a completely or partly degloved hand poses a major challenge for a surgeon. In contrast to scalping or a so-called ring finger amputation, which can be approached in many ways, from reimplantation to simple dressing of the stump, in case of an injury to the whole hand the possibilities are scarce and very demanding. Literature contains single reports of the following techniques used to rescue the degloved arm:

- revascularization of the degloved complex by anastomosing an artery, usually a branch of radial or ulnar artery, with a vein (arteriovenous shunting) [1, 2]. Both experimental and clinical studies have shown that such a non-anatomical anastomosis provides sufficient perfusion to nourish the revascularized tissue complex. This method is effective only in case of moderate trauma to the degloved part. However, in most cases the mechanism of injury is crushing with thrombosis and necrosis occurring in the damaged vessels even after flap revascularization;
- revascularization of the complex by the standard method, by anastomosing arteries and veins of the scalp to those of the stump [3]. This is technically very difficult and rarely possible to perform, and its effectiveness depends on the aforementioned trauma of detached tissues;
- covering of the hand skeleton (including the fingers) with pedicled and free flaps. Simultaneous application of free flaps from the anterolateral surface of the thigh, the dorsal surface of the foot and the pedicled inguinal flap ("chimeric" and multi-pedunculated flaps) [4 – 8] is described. This treatment technique is very challenging and requires high proficiency in transferring of vascularized tissue complexes, but gives hope for rescuing the hand, although with limited function;
- implantation of the hand in the abdominal cavity for 4 weeks. After this time, the skeleton of the hand is cut out of the abdominal subcutaneous tissue, obtaining coverage of the tendons and finger bones on the dorsal side and granulation tissue on the palmar side, to which skin grafts are applied in subsequent stages and then separated (Nazerani et al.). The method is currently rarely used due to poor functional results and significant cosmetic defects of abdominal skin;
- covering the hand with a skin graft formed from the skinned complex [9]. This method can only be used to treat the parts of limbs that contain muscles (from the metacarpus upwards), but it cannot be used for degloved fingers;
- wrapping the hand skeleton with the greater omentum, as in the cases described in this publication [10]. It can also be transferred as a free flap: in our department, a flap from the greater omentum was once used to cover the scalped head [11].

The flap heals into the degloved hand relatively easily, but then some serious problems are encountered:

- the thick, fatty-granulomatous complex is difficult to divide into separate fingers after covering with a skin graft; it is often possible to create two "double" fingers, as in the cases described in this work;

- for unknown reasons, distal and middle phalanges covered by the omentum undergo resorption in such a way that only the proximal phalanges remain. This phenomenon occurred in all of the presented cases from our material. It cannot be rationally explained why resorption does not involve proximal phalanges;
- if the omentum is thin (which is favorable), the stakes pierce it continuously during the healing process and need to be amputated.

LITERATURE REVIEW

Lo et al. proposed a classification of degloving injuries depending on the severity of vascular damage and involvement of the skin of the palmar hand. This classification also takes into account prognosis depending on the type and severity of tissue damage [1].

- criterion I concerns injuries, in which arterial inflow to detached skin and subcutaneous tissue is sufficient or insufficient for its survival. If it is sufficient (criterion I +), repositioning of separated soft tissues onto the bone and suturing them at the site of rupture is sufficient and the "scalp" usually heals;
- criterion II concerns injuries, in which arterial inflow to detached tissues is interrupted and tissues are ischemic (criterion I –). If the degloved complex has not been crushed and has patent venous outflow, formation of an AV shunt will ensure survival of most of the separated skin (criterion II +). If crushing is significant and the venous system is incompetent, the chances of survival, even after revascularization, are minimal (criterion II –);
- criterion III pertains to the involvement of the skin on the palmar or only the dorsal part of the hand and fingers as well as the forearm. In the first case (criterion III –), when injury affects the palmar side of metacarpus only, revascularization using an arteriovenous shunt is sufficient. If the skin is also detached from the fingers, additional anastomoses of phalangeal arteries offer a chance of their survival. If injury involves the dorsal skin of the hand and/or forearm (criterion III +) with preserved arterial inflow (criterion I +), it is enough to suture the separated tissues, while an AV shunt is necessary if skin ischemia is present.

The same authors presented the results of revascularization of degloved tissues by anastomosing an artery from the stump with a vein from the detached flap, which was performed in 14 patients. In 9 of them degloving involved the skin of the forearm and authors succeeded in healing of half of the affected skin surface, on average. In 3 cases involving degloved metacarpus, 70% of the tissue was healed, but in 2 cases of whole hand degloving, the revascularized part became necrotic. The majority of patients required additional surgery to facilitate wound healing. Most frequently, surgeries involved inguinal flaps and skin grafting, and functional outcomes were moderate. The authors emphasize that in cases of full degloving, arteriovenous shunt alone does not provide sufficient blood supply to the detached skin of the fingers and additional anastomoses of phalangeal arteries are necessary [1]. Similar techniques have been used effectively by other authors in 3 patients with partial hand degloving [2]. Zhang et al. described good outcomes after standard revascularization (artery-to-artery and vein-to-vein anastomoses) of the degloved tissue complex in 10 patients, most of whom had soft tissues of the metacarpus and phalanges torn off from the wrist to the fingers. In addition to the vessels, torn phalangeal nerves were sutured together as well. Most of the replanted scalp has healed in all patients, although amputation of one or more fingers was required in 9 subjects (mean, 4 phalanges per patient). All patients required successive surgeries to improve the hand function. In a follow-up after 3 years from injury, average MHQ (Michigan Hand Questionnaire) questionnaire score amounted to 69 points (range 29–96), which corresponds to a fairly significant disability of the hand (scoring 0 means full hand dexterity, and 100 complete disability) [3]. This method of reconstruction of degloved parts is the most technically demanding and exceptionally rarely used but probably produces the best functional outcomes.

Tang et al. presented the results of treatment of 39 patients with extensive skin and subcutaneous tissue loss with bone exposure as a result of scalping-crushing injury. Secondary reconstructions were performed in all patients following excision of necrotic tissues. A combination of two free flaps was used: the anterolateral thigh flap (usually to cover the dorsal side of the hand and fingers) and a ternary "chimeric" flap from the dorsal surface of the foot (anterior tibial artery propeller flap), to cover the palmar defect. This flap consisted of 3 separate parts, each supplied by a separate branch of the dorsalis pedis artery. The primary supplying vessel was the anterior tibial artery. This way, each one of the 3 degloved fingers was covered separately. At the follow-up one year after surgery, all the flaps were healed and, following secondary surgery, moderately satisfactory hand function was obtained [4]. Lin (2016) presented the results of covering 15 degloved hands with a combination of flaps: free flap from the anterolateral thigh surface (full or fascial only) with a pedicled inguinal flap. The inguinal flap was cut off after 2 weeks from being attached and the fused fingers were separated, which accelerated initiation of physiotherapy. In follow-up after a year after surgery all flaps were healed, and most patients achieved satisfactory mobility of the fingers (range 30 to 50% of normal mobility) as well as protective sensation [5]. Zelken et al. used a combination of pedicled flaps from the groin and anterolateral surface of the thigh to cover the degloved hands in 5 patients. All flaps healed properly and functional outcomes following separation and "slimming" surgeries were moderately satisfactory [6]. Similar techniques using different flaps have been effectively used and described by other authors [7, 8]. Nazerani et al. rescued the degloved hands in 6 patients by sewing them into a "pocket" formed in the abdominal wall (pocketing). This is a relatively old technique, the effectiveness of which in restoring hand function and independent movement of the fingers is similar to that of flaps from the greater omentum. The authors, however, made tunnels in the abdominal walls for each finger separately, allowing partial separation of fingers at the start. After extracting the hand from the abdomen, the dorsal side of the hand was covered by skin and the palmar side was covered with granulation tissue, which was later covered with a skin graft. In all cases, it was possible to separate the fingers, but the pictures presented in the work suggest that it only pertained to the proximal phalanges. Authors considered the outcomes satisfactory [9].

Seitz et al. presented the results of treatment of 7 patients with partial degloving of hands and forearms with the use of greater omentum free flaps. They collected appropriate fragments of the omentum according to the size of the hand defect and covered the injured areas. Average area of a defect was 300 cm2. The supply-

ing vessel of the flap was the right gastroepiploic artery, which was anastomosed end-to-side with the radial artery of the recipient. The accompanying vein was usually anastomosed end-to-end with the recipient's cephalic vein. After confirming good blood supply to the transferred flap, it was covered with a skin graft during the same operation. All flaps healed and no serious complications were reported. Functional outcomes after an average of 6 months were satisfactory. The images shown in the publication indicate that most of the degloving concerned the forearm and dorsal surface of the hand, while none of them involved the entire hand. In such cases, when the skin is preserved on the palmar side, there are more possibilities for reconstruction and functional outcomes are better than in full hand degloving [10].

Greater omentum flap can also be used in less extreme situations, e.g. in partial hand degloving, post-crushing necrosis or electrical burns. In such situations, surgical outcomes may be better. As already mentioned, free omental flap has been applied in our department to cover a scalped head with a very good end effect [11].

In conclusion, the described technique allowed for avoiding hand amputation in our patients. Nevertheless, the dexterity of preserved limbs was not satisfactory in most cases and functional outcomes were moderate at most. However, all patients were satisfied with the result and the efficacy of the applied method was evidenced by their return to work.

REFERENCES:

1. Lo S., Lin Y.T., Lin C.H., Wei F.C.: A new classification to aid the selection of revascularization techniques in major degloving injuries of the upper limb. Injury 2013; 44: 331–5.
2. Slattery P., Leung M., Slattery D.: Microsurgical arterialization of degloving injuries of the upper limb. J Hand Surg 2012; 37A: 825–31.
3. Zhang G., Ju J., Jin G., Tang L., Fu Y., Hou R.: Replantation or revascularization for the treatment of hand degloving injuries. J Plast Reconstr Aesthet Surg. 2016; 69: 1669–1675.
4. Tang L., Pafitanis G., Yang P., Li Z., Jia M., Koshima I., Song D., Chi Z.: Combined multi-lobed flaps: A series of 39 extensive hand and multi-digit injuries one-staged reconstructions using modified designs of ALT, DPA and chimeric linking flaps. Injury 2017; 48: 1527–1535.
5. Lin T. S.: One-stage debulking procedure after flap reconstruction for degloving injury of the hand. J Plast Reconstr Aesthet Surg. 2016; 69: 646–51.
6. Zelken J.A., Chang N.J., Wei F.C., Lin C.H.: The combined ALT-groin flap for the mutilated and degloved hand. Injury 2015; 46: 1591–6.
7. Senda H., Muro H., Terada S., Okamoto H.: A case of degloving injury of the whole hand reconstructed by a combination of distant flaps comprising an anterolateral thigh flap and a groin flap. J Reconstr Microsurg 2011; 27: 299–302.
8. Deal D.N., Barnwell J., Li Z.: Soft-tissue coverage of complex dorsal hand and finger defects using the turnover adipofascial flap. J Reconstr Microsurg. 2011; 27: 133–8.
9. Nazerani S., Motamedi M.H., Nazerani T., Bidarmaghz B.: Treatment of traumatic degloving injuries of the fingers and hand: introducing the „compartmented abdominal flap".Tech Hand Up Extrem Surg. 2011; 15: 151–5.
10. Seitz I.A., Williams C.S., Wiedrich T.A., Henry G., Seiler J.G., Schechter L.S.: Omental free-tissue transfer for coverage of complex upper extremity and hand defects – the forgotten flap. Hand (NY). 2009; 4: 397–405.
11. Prowans P., Kowalczyk R., Żyluk A.: Urazowe oskalpowanie głowy zaopatrzone wolnym płatem z sieci większej. Pol Przegl Chir 2001; 73: 378–382.

Liczba słów: 4490 Liczba stron: 8 Tabele: – Ryciny: 12 Piśmiennictwo: 11

DOI: 10.5604/01.3001.0013.5495 Table of content: https://ppch.pl/resources/html/articlesList?issueId=12160

Competing interests: The authors declare that they have no competing interests.

Corresponding author: Prof. Andrzej Żyluk, Department of General and Hand Surgery, Pomeranian Medical University in Szczecin, 71-252 Szczecin, Unii Lubelskiej Str. 1; tel.: 091 425 3196; e-mail: azyluk@hotmail.com

Cite this article as: Zyluk A., Szlosser Z., Puchalski P.: The results of the treatment of hand – Outcomes of the treatment of hand degloving injuries with greater omentum flaps; Pol Pol Przegl Chir 2019: 91 (6): 20–27