INDEX COPERNICUS INTERNATIONAL

What does a (general and abdominal) surgeon need to know on plastic surgery?

Armin Kraus[1], Manfred Infanger[1], Frank Meyer[2]

[1]Dept. of Plastic, Aesthetic and Hand Surgery, University Hospital of the Otto-von-Guericke University at Magdeburg, Germany
[2]Dept. of General, Abdominal, Vascular & Transplant Surgery, University Hospital, Otto-von-Guericke University at Magdeburg, Germany

Article history: Received: 11.02.2019 Accepted: 06.06.2019 Published: 06.06.2019

ABSTRACT:

Background: Plastic surgery was first introduced as a sub-specialty of general surgery in Germany in 1978. Since then, this surgical subspecialty/discipline has evolved enormous potential, e.g. in collaboration with other disciplines such as general and-abdominal surgery.

Aim: To highlight and summarize the basic potential, technical options and novel aspects of plastic surgery, which are relevant for the common interdisciplinary surgical strategies of plastic and general as well as abdominal surgery in clinical practice.

Method: Short and compact narrative review based on
1) a selection of relevant references from the medical scientific literature and
2) surgical experiences obtained in daily practice.

Results (selected corner points):

1) Biological protection procedures in vascular surgery by flap coverage after meticulous debridement with or without autogenic vascular reconstruction are used to overcome infection of a vascular prosthesis, a serious problem, associated with the risk of anastomotic rupture and bleeding by transfer of immunological competence due to tissue coverage and finally to induce healing in the area of an infected vascular prosthesis.

2) Fistula treatment for aorto-tracheal or aorto-duodenal fistulas, a big challenge for the referring general surgeon, can be treated by flap coverage, i.e. interposition of the pectoralis-major flap and the omentum-majus flap, respectively.

3) With regard to nerve surgery, encouraging results have been reported after early microsurgical recurrent laryngeal nerve repair, i.e. improved subjective voice quality or reconstitution of respiratory capacity in diaphragmatic.

4) Lymphatic surgery for lymphedema occurring either primarily due to an absence or lack of lymphatic vessels or secondarily due to infection, trauma, radiation therapy or surgery can be indicated in specialized microsurgical centers, e.g. for surgical repair of the lymphatic pathway: I) the interrupted lymphatic system can be reconstructed by an interposition, or II) the lymphatic fluid can be drained extraanatomically (e.g. by a lymphatic-venous anastomosis). Further techniques are the following: free lymph node transplantation included in a free vascularized groin flap or autologous lymphatic vessel transfer or vein graft interposition (used for lymphatic vessel interposition).

5) Mass reduction such as dermolipectomy with subsequent split-thickness is a valuable option, which provides excellent volume reduction.

6) Defect coverage: A. Split- or full-thickness skin grafts are a common method of defect coverage (in cases of clean and well-vascularized wound bed and lacking donor skin, or if the graft bed is of questionable quality) using various allogenic or xenogenic skin substitute materials. B. Further methods offer a wide-range armamentarium of local and free fasciocutaneous and musculocutaneous flaps, e.g. after abdomino-perineal rectum extirpation using the vertical rectus-abdominis myocutaneous flap (VRAM) or propeller flaps according to the "angiosome".

7) Abdominal wall hernia closure with instable skin coverage, flap closure, either alone or in combination with mesh is superior to mesh closure only.

8) Free flaps: If there is no option for a local or pedicled flap available, free flaps can be well used for abdominal wall defect closure (complication rate in experienced hands is low).

Conclusion: Plastic surgery is an indispensable partner for specific surgical problems and clinical situations of general and abdominal surgery, which indicates that each general and abdominal surgeon should be well notified on great options and surgical techniques offered by modern plastic surgery to achieve best outcomes and quality of life for patients and should combine the expertise of these two surgical disciplines.

KEYWORDS: abdominal surgery, general surgery, plastic surgery

LIST OF ABBREVIATIONS

ADSC – adipose-derived mesenchymal stem cell
ALT – anterolateralthigh flap
BCC – basal cell carcinoma
BMP-2 – bone morphogenetic protein 2
BMSC – bone marrow-derived mesenchymal stem cell
CAL – cell-assisted lipotransfer
Cas9 – CRISPR-associated endonuclease 9
CRISPR – clustered regularly interspaced short palindromic repeats
EC – embryonal stem cell

DOI: 10.5604/01.3001.0013.2365

RLN – recurrent laryngeal nerve
sgRNA – single-guided ribonucleic acid
TGF-β – transforming growth factor β
TRAM – transverse rectus abdominis myocutaneous flap
VRAM – vertical rectus abdominis myocutaneous flap

INTRODUCTION

Plastic surgery was first introduced as a sub-specialty of general surgery in Germany in 1978. Although existent as an independent board certification since 1992, there are still several overlappings of this young and emerging field with its "bigger brother", general surgery. Although plastic surgery is often associated with cosmetic procedures among the general public, and even among medical students [1], plastic surgery consists of its four columns:

- hand surgery,
- reconstructive surgery,
- burn surgery (and),
- aesthetic surgery.

Therefore, it is easy to conceive that there are several intersections with general surgery for interdisciplinary cooperation. Until the year 1992, plastic surgery was a sub-specialty of general surgery, such as trauma, vascular or abdominal surgery. In 1992, plastic surgery received its own board certification in Germany. It is a fast-evolving field, with many milestones, particularly in microsurgery, within the last decades. A free groin flap used by Daniel and Taylor in 1973 is regarded as the first clinically performed free tissue transfer [2]. The first free latissimus dorsi transfer, today´s "workhorse" in defect coverage, was performed by Baudet in 1976 [3].

This short and compact narrative review was based on a selection of relevant topic-related references from the medical scientific literature, and surgical experiences obtained in daily practice to highlight and summarize the basic potential, technical options and novel aspects of plastic surgery, which are relevant for the common interdisciplinary surgical strategies of plastic and general as well as abdominal surgery in daily clinical practice.

METHOD

Narrative review with references searched using the terms plastic surgery, general surgery, abdominal surgery, free groin flap, free latissimus dorsi transfer, vastus lateralis or rectus femoris flap, rectus-abdominis flap, pedicled omentum majus flap, partially combined.

CORNER POINTS

Biological protection procedures in vascular surgery

Infection of a vascular prosthesis is a serious problem, due to the risk of anastomotic rupture and bleeding. Biological protection procedures intend to induce healing in the area of an infected vascular prosthesis by flap coverage after meticulous debridement with or without autogenic vascular reconstruction. This is pursued to transfer immunological competence, normally provided by a muscle flap, to the area of the infected vascular prosthesis, which may induce healing. For this purpose, a vast amount of muscular and musculocutaneous flaps is available. If the vascular supply of the lower extremity is still patent, a muscular flap of the upper leg, such as the vastus lateralis or rectus femoris flap can be recommended (Fig. 1a.–c.). In case of impaired vascular inflow to the lower extremity, flaps from the more proximal part of the body must be chosen, as the rectus abdominis flap [4] or the pedicled omentum majus flap [5].

Fistula treatment

Entities such as aorto-tracheal or aorto-duodenal fistulas represent a big challenge for the referring general surgeon. Aorto-duodenal fistulas can successfully be treated by flap coverage, such as the omentum majus flap [6]. Accordingly, an aorto-tracheal fistula has been successfully covered by interposition of a pectoralis major flap [7]. Recto-vaginal fistulas, either due to obstetric, inflammatory or iatrogenic reasons, such as surgery or radiation treatment, represent a distressing pathology for the affected patients [8]. The classic surgical approach consists of a two-layer closure of the anterior rectal wall including possible coverage by the rectus abdominis flap [4] or the pedicled omentum majus flap [5].

Nerve surgery

Peripheral nerve surgery is a major component of plastic reconstructive surgery with its pioneers being Hanno Milesi or Julia Terzis. Although intraoperative nerve stimulation has significantly decreased the incidence of recurrent laryngeal nerve (RLN) injury, i.e. from 3.01% to 1.46 % in thyroid gland surgery according to a recent meta-analysis [9], vocal cord immobility is a debilitating problem for the patients to face. However, encouraging results after early microsurgical RLN repair with improved subjective voice quality have been reported [10, 11]. After microsurgical repair of the phrenic nerve, encouraging results concerning reconstitution of respiratory capacity in diaphragmatic palsy have been reported [12] too.

Lymphatic surgery

Lymphedema may be either primary due to absent or lacking lymphatic vessels or secondary due to infection, trauma, radiation therapy or surgery [13]. The severity of lymphedema can be divided into four stages [13]:

1 (subclinical): no visible swelling, but heaviness and discomfort;

2 (spontaneously reversible): swelling improved by limb elevation, pitting edema;

3 (not spontaneously reversible): swelling not relieved by limb elevation, edema may be pitting or not (and);

4 (elephantiasis): skin hardening, verrucous changes, recurrent infections.

Particularly after breast cancer surgery with concomitant radiation or iliac lymph node dissection, secondary lymphedema of the respective extremity may occur. After axillary dissection, the incidence of lymphedema ranges from 3 to 14% [14, 15]. Depending on the degree of radicality, lymph edema of the lower extremity occurs with an incidence ranging from 10 to 20% [16, 17] af-

Fig. 1. Infected arterial reconstruction: a: Exposed femoral artery prosthesis in the left groin. b: Defect coverage by rectus femoris muscle flap and split-thickness skin graft. c: Another example of coverage of a femoral artery prosthesis after inguinal tumor resection by a vertical rectus abdominis flap (VRAM) from the right side – left wound margin was covered with a split-thickness skin graft, donor site could be closed directly.

ter inguinal lymph node dissection. In cases of light to moderate severity, conservative therapy with lymphatic drainage and compression garments might be sufficient. In specialized microsurgical centers, a causal surgical therapy for stages 2 and 3 can be attempted. For surgical repair of the lymphatic pathway, two general methods can be used:

- the interrupted lymph system can be reconstructed by an interposition, or
- the lymphatic fluid can be drained extraanatomically.

In 1979, O´Brien et al. first described the creation of an artificial lymphatic drainage over a lymphatic-venous anastomosis in 40 patients [18]. The authors described a significant volume reduction in the affected limbs in two thirds of their patients.

Free lymph node transplantation

For lymphedema of the arm after mastectomy, lymph node transfer included in a free vascularized groin flap has been described [19]. After a follow-up period of 56 months, a volume reduction of 51% could be achieved compared to the condition before surgery. The incidence of cellulitis was decreased in 11 of 13 patients.

The lymph nodes may also be embedded in a vascularized omental or submental flap. The vascularized omental flap can either be performed with microsurgical angiography at a distant site, as it has been shown by O´Brien in a dog model [20]. Authors reported a significant reduction of an artificially created lymphedema in the hind limb after free tissue transfer of the omentum. If the source of the lymphedema is more adjacent to the abdominal area, such as the inguinal region, the procedure can be performed even more easily by a pedicled omentum flap. Benoit et al. performed this procedure in seven patients undergoing inguinal lymph node dissection, with three of them undergoing an additional postoperative radiotherapy [21]. Authors reported a complete absence of lymphocele, asymptomatic decrease in limb diameter compared to the contralateral limb in four patients and decrease in limb circumference compared to the preoperative condition in three patients. Cheng et al. transferred a free vascularized submental flap to the ankles of six patients with chronic lymphedema of the lower limb. After 9 months, authors observed a reduction in the circumference of the respective limb of over 60% on average [22].

Autologous lymph vessel transfer

For lymph edema of the upper and lower extremity, free lymph vessel transfer has been reported [23]. The procedure can be performed either on the ipsilateral limb, as a bridge crossing the blockage, or drainage can be guided to the contralateral limb. Two years (106 weeks) after surgery, arm volumes could be reduced by 28% hereby. Despite incomplete resolution of edema in the upper extremity, this method can be considered an option in case of pressure difference of blood and lymphatic fluid or blood hypercoagulability.

Vein graft interposition

Instead of lymphatic vessel transfer, a vein graft may also be used for lymphatic interposition [24] as described by Campisi et al. This method is suitable when a lymphovenous shunt cannot be performed due to venous congestion and increased venous pressure in the respective extremity. Some advantages of venous grafts over lymphatic grafts have been described: due to a larger diameter of veins compared to lymphatic vessels, several lymphatic vessels can be anastomosed to one vein both proximally and distally. As veins contain valves, this may help to prevent backflow of lymphatic fluid. Furthermore, vein collaterals may be used to anastomose additional lymphatic vessels. Average reduction of excess volume was over 75% in 47% of the patients evaluated in this study.

Mass reduction

In case of higher lymphedema stage (III and IV), plastic surgery can offer a variety of mass reduction procedures. In grade III lymphedema, liposuction can be successfully applied. In stage IV lymphedema, subcutaneous tissue is often hardened to an extent that it cannot be removed by liposuction anymore. In these cases, dermolipectomy with subsequent split-thickness skin grafting is a valuable option. It provides excellent volume reduction, however at the potential cost of increased swelling distal to the reduction site (Fig. 2a., 2b.). Patient satisfaction and compliance, however, is usually high in such procedures.

Fig. 2. Grade IV lymphedema of the lower extremities: a: Dermolipectomy and split-thickness skin grafting has already been performed on the distal right lower leg. b: Stepwise dermolipectomy and skin grafting is performed - superficial infection has occurred that resolved under local antiseptic treatment.

Robotics in plastic surgery

In microsurgery, the demand for faster anastomoses, lowest possible failure rate, and lower vessel diameter is increasing. As the exactness of human movement, vision and tactility is limited, utilization of a robotic device is an option to overcome these limitations. Factors such as human fatigue can be ruled out by robotic surgery, so this approach seems to be promising in many aspects. In abdominal surgery, robotics is already in widespread use, such as for gastrectomy [25], colectomy [26] or aortocaval lymph node dissection [27]. Although not routinely implemented in plastic surgery, microsurgical anastomoses can be performed significantly faster, at least on silicone tubes [28]. Lymphatic anastomosis, particularly in the scale of supermicrosurgery, seems highly appropriate to be performed with the help of a robotic device, but no systematic literature exists to date, describing its benefits or drawbacks. We may look forward to the first systematic studies in this field, and be optimistic that a new valuable tool is on the horizon particularly in this special field.

Skin grafts and skin substitutes

Split- or full-thickness skin grafts are a common method of defect coverage if the wound bed is clean and well vascularized. Recent scientific advances have offered options in situations of lacking donor skin, or of the graft bed being of questionable quality. In case of lacking donor skin, the graft can either be extended in size by mesh, or meek technique [29], or there are various allogenic or xenogenic skin substitute materials available, such as:

- TransCytec (newborn human fibroblasts grown on a nylon mesh; Advanced Tissue Sciences, La Jolla/CA, U.S.A.) [30],
- Integrac (combination of bovine collagen and silicone layer; Integra life sciences, Plainsboro MA, USA) [31],
- AlloDermc (decellularized cadaver skin; Allergan, Dublin, Ireland) [32],
- Dermagraftc (neonatal fibroblasts seeded on a polylactic matrix; Organogenesis Inc, Canton MA, USA) (33),
- Apligrafc (type-I collagen matrix seeded with neonatal fibroblasts, with a superficial layer of keratinocytes; Organogenesis Inc, Canton MA, USA) [34].

Such materials improve the chances of graft take or serve as temporary coverage in case of lacking donor skin.

Defect coverage

Several situations can be conceived where immediate or delayed coverage of abdominal or pelvic defects is required. Full-thickness abdominal wall defects may be created by tumor resection such as aggressive neurofibromatosis. For these situations, plastic surgery offers a wide range of armamentarium of local and free fasciocutaneous and musculocutaneous flaps. In cases after abdominoperineal rectum extirpation, closure of the remnant intrapelvic cavities by muscle flaps has helped in avoiding complications such as chronic wound healing disorders or secretion [35]. In our personal experience, the vertical rectus abdominis myocutaneous flap (VRAM) is highly suitable for this purpose. It is relatively quick and easy to harvest, has a reliable vascular pedicle over the inferior epigastric artery, allows good occlusion of the intrapelvic cavity and coverage of skin defects owing to its musculocutaneous composition (Fig. 3a.-b.). For preoperative workup, Doppler ultrasonographic flow detection of the inferior part of the epigastric artery seems sufficient in our opinion. According to a recent meta-analysis, defect coverage with a VRAM flap is superior to its alternatives such as gracilis flap or gluteus flap [36].

In particular, VRAM flap is suitable for coverage of the excised perianal region after Holm's procedure (extralevatory rectum extirpation) for rectal cancer. The VRAM flap is also suitable for coverage of laterally located abdominal wall defects, with various valuable alternatives. In a defect located more cranially, either the pedicled latissimus dorsi flap (Fig. 4.) or the transverse rectus abdominis flap (TRAM) with a cranial pedicle is another choice (Fig. 5.). For the latter, patency of the internal mammary artery must be ensured preoperatively. A previous mammary artery coronary bypass for example is a contraindication. If a thinner coverage is required, there is a vast choice of fasciocutaneous flaps available. Particularly, the concept of perforator flaps has greatly expanded the versatility of fasciocutaneous flaps, as they are thin, flexible and can be harvested with minimal donor morbidity [37]. The body surface is crisscrossed by a vascular network extending parallel to this surface. This network is nourished by so-called perforator vessels protruding from deeper layers perpendicular to the surface network. A skin area sufficiently supplied with blood by one perforator is called an „angiosome ".

If a perforator can be isolated, a corresponding angiosome can be harvested as a flap, and either transferred locally, as described in the concept of "propeller flaps" [38–40], or harvested as a free flap, with the recipient vessels anastomosed directly to the perforators in special cases, or the perforators being dissected proximally until the vessel caliber has increased sufficiently for safe anastomosis. A common example is the anterolateral thigh flap (ALT), first described by Song et al. in 1984 [41] as a free flap. It can be well used either as a free or as a pedicled flap for coverage of large full-thickness defects of the abdominal wall [42].

Abdominal wall hernia closure

Large or recurrent abdominal wall hernias represent a great challenge to the referring surgeon. According to the prevailing opinion, these cases should be treated by insertion of an artificial mesh (e.g. prolene; Ethicon, Norderstedt, Germany, or Gore©, G.L. Gore GmbH, Putzbrunn, Germany). Despite its stability, artificial material has an inherent risk of infection. Especially in areas where

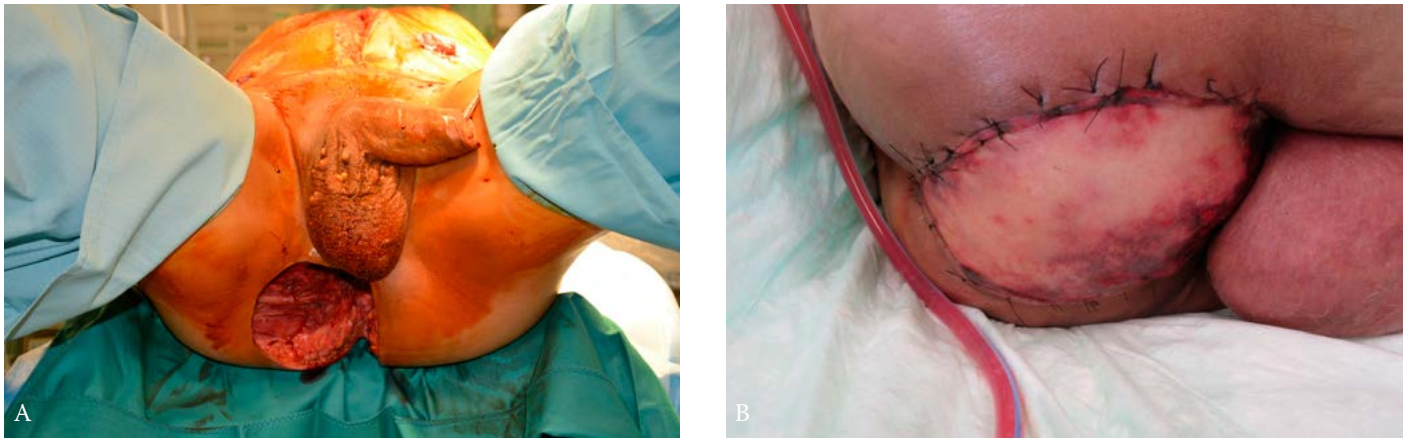

Fig. 3. Soft tissue defect: a: After abdominoperineal rectum extirpation. b: Defect coverage with a vertical rectus abdominis myocutaneous flap (VRAM).

complete clean debridement cannot be achieved, or an infected mesh had to be removed before, the referring surgeon may seek an alternative. Plastic surgery can offer a wide range of treatment options with local flaps, which have been in use for several decades already, with their efficacy being already well proven. Common flaps such as the tensor fasciae latae flap [43], rectus abdominis turnover flap [44], external oblique muscle flap [45], rectus femoris muscle flap [46], omentum flap or pedicled latissimus dorsi flap can be utilized [47]. A recent study showed that especially in hernias with unstable skin coverage, flap closure, either alone or in combination with mesh, is superior to mesh closure only [48].

Free flaps

If a local or pedicled flap is unavailable, free flaps can be well used for abdominal wall defect closure. Several of the flaps cited above can also be applied as free flaps, such as tensor fasciae latae flap, free anterolateral thigh flap, or free latissimus dorsi flap. Usually, the complication rate of the procedure is low [49].

FUTURE PERSPECTIVES

Abandoned fields in plastic surgery

Plastic surgery is a quickly developing field that has opened up several new fields in the recent decades and years. On the other hand, some areas have been left or handed over to other specialties. In case of advanced-stage esophageal cancer, resection and interposition of the jejunum has been partially abandoned in favour of radiochemotherapy [50, 51]. The same tendency has been noticed for advanced oropharyngeal squamous cell carcinoma. Radiochemotherapy alone has been advocated more and more frequently as equally effective to surgery [52], so that extensive resections and subsequent flap coverage is becoming less common. Basal cell carcinomas (BCC), either occurring in the head and neck region or on the trunk, have undergone resection and flap coverage if necessary, as a standard treatment.

Recent studies, however, have shown impressive response of advanced BCCs to vismodegib [53]. The substance is an inhibitor of the hedgehog pathway, inhibiting SMO, one of the downstream targets thereby blocking gene transcription. Despite these developments, treatment options for plastic surgeons, including local or free flaps after excision, are still huge.

Post-bariatric plastic surgery

After massive weight loss, cosmetically unpleasing skin laxity often remains. While bariatric surgery intended to induce weight loss, including procedures such as gastric banding, gastric sleeve resection, gastric bypass, biliopancreatic diversion and others [54], are the domain of abdominal surgery, plastic surgery can offer a variety of options to correct the shape of the body surface after weight loss has taken place. There are various good papers dealing with post-bariatric plastic surgery [55–57] but a concise review on this topic is beyond the scope of this article. Briefly, body contouring procedures comprise brachioplasty, thighplasty, abdominoplasty, fully body lifts and mastopexies in various modifications. For details, we refer to the literature cited above.

"Emergency plastic surgery"

Although most operations in reconstructive surgery are elective, there are still more than enough plastic surgery emergency procedures. All vital structures such as nerves of blood vessels require immediate coverage to avoid major damage. Skilled plastic surgeons are trained to perform a variety of local and free flaps for emergency defect coverage. If there is no option for a local flap, emergency free flaps may also be performed. If possible, preoperative informed patient consent should invlove expansion in the surgical course, to provide legal safety for the parties involved.

New trends and fields in plastic surgery

The concept of the "reconstructive ladder", according to which a defect should be covered by a method as simple as possible, and the next reconstructive step should only be undertaken if the easier one fails, has been widespread and widely accepted. In the mid-90s, however, the concept of the reconstructive elevator was first advocated as an alternative [58]. According to this concept, defects should be covered by the best, not by the easiest method, with overleaping the lower steps of the ladder and sending the elevator to the best possible option. With new options in tissue engineering and genetic editing, both the ladder could be extended by additional steps, and the elevator could stop at additional higher or lower floors.

Attracting residents to plastic surgery

It is becoming more and more difficult to obtain young talented staff in the field of surgery. It is well known that surgical training

Fig 4. Presternal defect coverage with right-sided latissimus dorsi myocutaneous flap and split-thickness skin graft

Fig. 5. Secondary presternal defect coverage in the same patient after flap failure by transverse myocutaneous rectus abdominis flap (TRAM) – donor site is closed in the fashion of abdominoplasty with umbilical re-insertion.

is time-consuming and exhausting for residents, and several publications have dealt with its negative aspects such as residents´ dissatisfaction and burnout [59, 60]. However, awareness of these issues has increased, and a lot has already changed for the better. In the view of the authors, plastic surgery residency is still a good choice for young doctors and the beginning of their career for various reasons: plastic surgery itself is a young, fast-evolving field, both clinically and scientifically. Many of its clinical advances, such as perforator flaps, limb transplantations or stem cell application, and its development seem to be far away from an end. Microsurgery is still in its development phase, with the use of robotics or without, and it is a fascinating field to deal with. It is still a competitive field, but with a general lack of applicants in surgery, job opportunities in plastic surgery have become better. Research in the field of stem cell therapies and tissue engineering [61–63] is fast evolving, offering additional career chances and satisfaction in plastic surgery.

Stem cells in plastic surgery

Stem cells have been increasingly advocated in various sub-fields of plastic surgery, both reconstructive and aesthetic, during the recent years [64]. There are various types of stem cells, either adult mesenchymal ones, taken from the bone marrow (BMSCs) or fat (ADSCs), or embryonal stem cells (ECs), however with limited application due to ethical reasons. Fat grafting is a widely performed procedure with the rationale to bring ADSCs to a certain site and to bring them into action there. First, fat is a nearly ideal filling material, causing no problems with biocompatibility. The containing fraction of ADSCs, optionally enriched by cell-assisted lipotransfer (CAL), is in use more and more actively for low-invasive breast augmentation [65]. Promising initial attempts have also been made in the field of bone [66] and cartilage reconstruction [67]. Growth factors such as BMP-2 and TGF-β have been shown to be essential to drive the ADSCs into the respective lineage. Thorough further research is still required in this fast-developing field to selectively turn ASCs into the desired lineage. Ischemic limb ulcerations make the plastic surgeon face a serious challenge, as most surgical options such as local or free flaps fail in this situation. In addition to skin grafts as the usual last option, fat transfer has been shown to be beneficial in these situations, both with respect to local wound healing and improved limb perfusion [68, 69].

Cutting-edge research topics in plastic surgery

In addition to stem cell therapy and tissue engineering, there are countless more cutting-edge scientific attempts in plastic surgery. Application of nanotechnology, to create nerve sensing in a myoelectric prosthesis, e.g. [70], is one of them, while machine learning and artificial intelligence is another. Details would exceed the scope of this review here, but stunning results may be expected in the future. The clustered regularly interspaced short palindromic repeats (CRISPR) system, first described in 2013 [71], has been found as a breakthrough in genome editing ex vivo and in vivo. By custom-designed single guide RNA (sgRNA), any sequence of the genome can be targeted and then cut and edited by Cas9, the genomic scissor [72]. This can either be used for gene knockout or sequence re-writing. Furthermore, this system can also serve for transcriptional activation or inhibition. Although still in the experimental state, various applications of CRISPR can be conceived both in abdominal and plastic surgery. For example, xenografts from the pig could be depleted of porcine viruses or immunogenic epitopes [73]. Autogenic tissue grafts, such as local or free flaps, could be genetically modified to improve wound healing or bone consolidation [74]. Wound healing, an issue that concerns both abdominal and plastic surgery, is influenced by various cytokines and mediators. Transcription of genes that accelerate wound healing, such as vascular endothelial growth factor and platelet-derived growth factor could be enhanced, and studies investigating this issue are already ongoing [75].

SUMMARY

Plastic surgery is a fast-evolving field, overlapping general and abdominal surgery in many points, such as hernia repair, defect coverage, lymphatic surgery and peripheral nerve repair. Plastic surgeons are further active in basic research, involving stem cell therapy, tumor biology, besides many other fields, and cooperation between these two specialties will bring fruitful results for patient care and scientific progress.

REFERENCES:

1. Kling R.E., Nayar H.S., Harhay M.O., Emelife P.O., Manders E.K., Ahuja N.K. et al.: The scope of plastic surgery according to 2434 allopathic medical students in the United States. Plast Reconstr Surg., 2014; 133(4): 947–956.
2. Daniel R.K., Taylor G.I.: Distant transfer of an island flap by microvascular anastomoses. A clinical technique. Plast Reconstr Surg., 1973; 52(2): 111–117.
3. Baudet J., Guimberteau J.C., Nascimento E.: Successful clinical transfer of two free thoraco-dorsal axillary flaps. Plast Reconstr Surg., 1976; 58(6): 680–688.
4. De Santis F., Chaves Brait C.M., Caravelli G., Pompei S., Di Cintio V.: Salvage of infected vascular graft via ‚perivascular venous banding' technique coupled with rectus abdominis myocutaneous muscle flap transposition. Vascular., 2013; 21(1): 17–22.
5. Van Krunckelsven L., Marichal P., Hubens A.: Use of a pedicled omental flap in the treatment of an infected vascular prosthetic graft. Eur J Vasc Endovasc Surg., 1995; 10(2): 256–257.
6. Friedrich J., Erhard J., Eigler F.W.: [Aorto-duodenal fistula--direct suture and pedicled omentum flap-plasty]. Zentralbl Chir., 1997; 122(7): 565–568; discussion 8.
7. Sakatoku Y., Fukaya M., Fujieda H., Kamei Y., Hirata A., Itatsu K. et al.: Tracheoesophageal fistula after total resection of gastric conduit for gastro-aortic fistula due to gastric ulcer. Surg Case Rep., 2017; 3(1): 90.
8. Knuttinen M.G., Yi J., Magtibay P., Miller C.T., Alzubaidi S., Naidu S. et al.: Colorectal-Vaginal Fistulas: Imaging and Novel Interventional Treatment Modalities. J Clin Med., 2018; 7(4).
9. Bai B., Chen W.: Protective Effects of Intraoperative Nerve Monitoring (IONM) for Recurrent Laryngeal Nerve Injury in Thyroidectomy: Meta-analysis. Sci Rep., 2018; 8(1): 7761.
10. Mattsson P., Frostell A., Bjorck G., Persson J.K.E., Hakim R., Zedenius J. et al.: Recovery of Voice After Reconstruction of the Recurrent Laryngeal Nerve and Adjuvant Nimodipine. World J Surg., 2018; 42(3): 632–638.
11. Dzodic R., Markovic I., Santrac N., Buta M., Djurisic I., Lukic S.: Recurrent Laryngeal Nerve Liberations and Reconstructions: A Single Institution Experience. World J Surg., 2016; 40(3): 644–651.
12. Kaufman M.R., Elkwood A.I., Colicchio A.R., CeCe J., Jarrahy R., Willekes L.J. et al.: Functional restoration of diaphragmatic paralysis: an evaluation of phrenic nerve reconstruction. Ann Thorac Surg., 2014; 97(1): 260–266.
13. Grada A.A., Phillips T.J.: Lymphedema: Diagnostic workup and management. J Am Acad Dermatol., 2017; 77(6): 995–1006.
14. Cowher M.S., Grobmyer S.R., Lyons J., O'Rourke C., Baynes D., Crowe J.P.: Conservative axillary surgery in breast cancer patients undergoing mastectomy: long-term results. J Am Coll Surg., 2014; 218(4): 819–824.
15. Rao R., Euhus D., Mayo H.G., Balch C.: Axillary node interventions in breast cancer: a systematic review. JAMA., 2013; 310(13): 1385–1394.
16. Spillane A.J., Saw R.P., Tucker M., Byth K., Thompson J.F.: Defining lower limb lymphedema after inguinal or ilio-inguinal dissection in patients with melanoma using classification and regression tree analysis. Ann Surg., 2008; 248(2): 286–293.
17. Theodore J.E., Frankel A.J., Thomas J.M., Barbour A.P., Bayley G.J., Allan C.P. et al.: Assessment of morbidity following regional nodal dissection in the axilla and groin for metastatic melanoma. ANZ J Surg., 2017; 87(1–2): 44–48.
18. O'Brien B.M., Shafiroff B.B.: Microlymphaticovenous and resectional surgery in obstructive lymphedema. World J Surg., 1979; 3(1): 3–15, 121–123.
19. Lin C.H., Ali R., Chen S.C., Wallace C., Chang Y.C., Chen H.C. et al.: Vascularized groin lymph node transfer using the wrist as a recipient site for management of postmastectomy upper extremity lymphedema. Plast Reconstr Surg., 2009; 123(4): 1265–1275.
20. O'Brien B.M., Hickey M.J., Hurley J.V., Dvir E., Khazanchi R.K., Pederson W.C. et al.: Microsurgical transfer of the greater omentum in the treatment of canine obstructive lymphoedema. Br J Plast Surg., 1990; 43(4): 440–446.
21. Benoit L., Boichot C., Cheynel N., Arnould L., Chauffert B., Cuisenier J. et al.: Preventing lymphedema and morbidity with an omentum flap after ilioinguinal lymph node dissection. Ann Surg Oncol., 2005; 12(10): 793–799.
22. Cheng M.H., Huang J.J., Nguyen D.H., Saint-Cyr M., Zenn M.R., Tan B.K. et al.: A novel approach to the treatment of lower extremity lymphedema by transferring a vascularized submental lymph node flap to the ankle. Gynecol Oncol., 2012; 126(1): 93–98.
23. Baumeister R.G., Siuda S., Bohmert H., Moser E.: A microsurgical method for reconstruction of interrupted lymphatic pathways: autologous lymph-vessel transplantation for treatment of lymphedemas. Scand J Plast Reconstr Surg., 1986; 20(1): 141–146.
24. Campisi C., Boccardo F.: Vein graft interposition in treating peripheral lymphoedemas. Handchirurgie, Mikrochirurgie, plastische Chirurgie: Organ der Deutschsprachigen Arbeitsgemeinschaft fur Handchirurgie: Organ der Deutschsprachigen Arbeitsgemeinschaft fur Mikrochirurgie der Peripheren Nerven und Gefasse: Organ der Vereinigung der Deutschen Plastischen Chirurgen., 2003; 35(4): 221–224.
25. Patriti A., Ceccarelli G., Bellochi R., Bartoli A., Spaziani A., Di Zitti L. et al.: Robot-assisted laparoscopic total and partial gastric resection with D2 lymph node dissection for adenocarcinoma. Surg Endosc., 2008; 22(12): 2753–2760.
26. Baek S.J., Al-Asari S., Jeong D.H., Hur H., Min B.S., Baik S.H. et al.: Robotic versus laparoscopic coloanal anastomosis with or without intersphincteric resection for rectal cancer. Surg Endosc., 2013; 27(11): 4157–4163.
27. Roviello F., Piagnerelli R., Ferrara F., Caputo E., Scheiterle M., Marrelli D.: Assessing the feasibility of full robotic interaortocaval nodal dissection for locally advanced gastric cancer. Int J Med Robot., 2015; 11(2): 218–222.
28. van Mulken T.J.M., Boymans C., Schols R.M., Cau R., Schoenmakers F.B.F., Hoekstra L.T. et al.: Preclinical Experience Using a New Robotic System Created for Microsurgery. Plast Reconstr Surg., 2018; 142(5): 1367–1376.
29. Medina A., Riegel T., Nystad D., Tredget E.E.: Modified Meek Micrografting Technique for Wound Coverage in Extensive Burn Injuries. J Burn Care Res., 2016; 37(5): 305–313.
30. Noordenbos J., Dore C., Hansbrough J.F.: Safety and efficacy of TransCyte for the treatment of partial-thickness burns. J Burn Care Rehabil., 1999; 20(4): 275–281.
31. Johnson M.B., Wong A.K.: Integra-based Reconstruction of Large Scalp Wounds: A Case Report and Systematic Review of the Literature. Plast Reconstr Surg Glob Open., 2016; 4(10): e1074.
32. Jansen L.A., De Caigny P., Guay N.A., Lineaweaver W.C., Shokrollahi K.: The evidence base for the acellular dermal matrix AlloDerm: a systematic review. Ann Plast Surg., 2013; 70(5): 587–594.
33. Hart C.E., Loewen-Rodriguez A., Lessem J.: Dermagraft: Use in the Treatment of Chronic Wounds. Adv Wound Care (New Rochelle), 2012; 1(3): 138–141.
34. Zelen C.M., Gould L., Serena T.E., Carter M.J., Keller J., Li W.W.: A prospective, randomised, controlled, multi-centre comparative effectiveness study of healing using dehydrated human amnion/chorion membrane allograft, bioengineered skin substitute or standard of care for treatment of chronic lower extremity diabetic ulcers. Int Wound J., 2015; 12(6): 724–732.
35. Brodbeck R., Horch R.E., Arkudas A., Beier J.P.: Plastic and Reconstructive Surgery in the Treatment of Oncological Perineal and Genital Defects. Front Oncol., 2015; 5: 212.
36. Johnstone M.S.: Vertical Rectus Abdominis Myocutaneous Versus Alternative Flaps for Perineal Repair After Abdominoperineal Excision of the Rectum in the Era of Laparoscopic Surgery. Ann Plast Surg., 2017; 79(1): 101–106.
37. Wei F.C., Celik N.: Perforator flap entity. Clin Plast Surg., 2003; 30(3): 325–329.
38. Mohan A.T., Sur Y.J., Zhu L., Morsy M., Wu P.S., Moran S.L. et al.: The Concepts of Propeller, Perforator, Keystone, and Other Local Flaps and Their Role in the Evolution of Reconstruction. Plast Reconstr Surg., 2016; 138(4): 710e–729e.
39. Sisti A., D'Aniello C., Fortezza L., Tassinari J., Cuomo R., Grimaldi L. et al.: Propeller Flaps: A Literature Review. In Vivo, 2016; 30(4): 351–373.
40. Wei J.W., Ni J.D., Dong Z.G., Liu L.H., Liu X., Peng P.: A Systematic Review and Meta-Analysis of Perforator-Pedicled Propeller Flaps in Lower Extremity Defects: Identification of Risk Factors for Complications. Plast Reconstr Surg., 2016; 138(2): 382e–383e.
41. Song Y.G., Chen G.Z., Song Y.L.: The free thigh flap: a new free flap concept based on the septocutaneous artery. Br J Plast Surg., 1984; 37(2): 149–159.
42. Kim D.Y., Lee J., Kim J.T., Chang H.K., Moon S.H.: Reconstruction of a large full-thickness abdominal wall defect with flow-through-based alt flaps: A case report. Microsurgery. 2017.
43. Williams J.K., Carlson G.W., deChalain T., Howell R., Coleman J.J.: Role of tensor fasciae latae in abdominal wall reconstruction. Plast Reconstr Surg., 1998; 101(3): 713–718.
44. DeFranzo A.J., Kingman G.J., Sterchi J.M., Marks M.W., Thorne M.T.: Rectus turnover flaps for the reconstruction of large midline abdominal wall defects. Ann Plast Surg., 1996; 37(1): 18–23.
45. Ramirez O.M., Ruas E., Dellon A.L.: „Components separation" method for closure of abdominal-wall defects: an anatomic and clinical study. Plast Reconstr Surg., 1990; 86(3): 519–526.
46. Daigeler A., Fansa H., Altmann S., Awiszus F., Schneider W.: The pedicled rectus femoris muscle flap for reconstruction of complicated abdominal wall defects. Rozhl Chir., 2005; 84(5): 238–243.

47. Bath A.S., Patnaik P.K., Bhandari P.S.: Reconstruction of Complex Abdominal Wall Defects. Med J Armed Forces India., 2007; 63(2): 123–126.
48. Mathes S.J., Steinwald P.M., Foster R.D., Hoffman W.Y., Anthony J.P.: Complex abdominal wall reconstruction: a comparison of flap and mesh closure. Ann Surg., 2000; 232(4): 586–596.
49. Wong C.H., Lin C.H., Fu B., Fang J.F.: Reconstruction of complex abdominal wall defects with free flaps: indications and clinical outcome. Plast Reconstr Surg., 2009; 124(2): 500–509.
50. Ma M.W., Gao X.S., Gu X.B., Xie M., Cui M., Zhang M. et al.: The role of definitive chemoradiotherapy versus surgery as initial treatments for potentially resectable esophageal carcinoma. World J Surg Oncol., 2018; 16(1): 172.
51. Vellayappan B.A., Soon Y.Y., Ku G.Y., Leong C.N., Lu J.J., Tey J.C.: Chemoradiotherapy versus chemoradiotherapy plus surgery for esophageal cancer. Cochrane Database Syst Rev., 2017; 8: CD010511.
52. Kelly J.R., Park H.S., An Y., Contessa J.N., Yarbrough W.G., Burtness B.A. et al.: Comparison of Survival Outcomes Among Human Papillomavirus-Negative cT1-2 N1-2b Patients with Oropharyngeal Squamous Cell Cancer Treated with Upfront Surgery vs Definitive Chemoradiation Therapy: An Observational Study. JAMA Oncol., 2017; 3(8): 1107–1111.
53. Sekulic A., Migden M.R., Oro A.E., Dirix L., Lewis K.D., Hainsworth J.D. et al.: Efficacy and safety of vismodegib in advanced basal-cell carcinoma. N Engl J Med., 2012; 366(23): 2171–2179.
54. Malczak P., Pisarska M., Piotr M., Wysocki M., Budzynski A., Pedziwiatr M.: Enhanced Recovery after Bariatric Surgery: Systematic Review and Meta-Analysis. Obes Surg., 2017; 27(1): 226–235.
55. Gunnarson G.L., Froyen J.K., Sandbu R., Thomsen J.B., Hjelmesaeth J.: Plastic surgery after bariatric surgery. Tidsskr Nor Laegeforen., 2015; 135(11): 1044–1049.
56. Garcia Botero A., Garcia Wenninger M., Fernandez Loaiza D.: Complications After Body Contouring Surgery in Postbariatric Patients. Ann Plast Surg., 2017; 79(3): 293–297.
57. Maia M., Costa Santos D.: Body Contouring After Massive Weight Loss: A Personal Integrated Approach. Aesthetic Plast Surg., 2017; 41(5): 1132–1145.
58. Gottlieb L.J., Krieger L.M.: From the reconstructive ladder to the reconstructive elevator. Plast Reconstr Surg., 1994; 93(7): 1503–1504.
59. Appelbaum N.P., Lee N., Amendola M., Dodson K., Kaplan B.: Surgical Resident Burnout and Job Satisfaction: The Role of Workplace Climate and Perceived Support. J Surg Res., 2019; 234: 20–25.
60. Zubair M.H., Hussain L.R., Williams K.N., Grannan K.J.: Work-Related Quality of Life of US General Surgery Residents: Is It Really So Bad? J Surg Educ., 2017; 74(6): e138–e46.
61. Golas A.R., Hernandez K.A., Spector J.A.: Tissue engineering for plastic surgeons: a primer. Aesthetic Plast Surg., 2014; 38(1): 207–221.
62. Woon C.Y., Kraus A., Raghavan S.S., Pridgen B.C., Megerle K., Pham H. et al.: Three-dimensional-construct bioreactor conditioning in human tendon tissue engineering. Tissue Eng Part A., 2011; 17(19–20): 2561–2572.
63. Wong V.W., Rustad K.C., Longaker M.T., Gurtner G.C.: Tissue engineering in plastic surgery: a review. Plast Reconstr Surg., 2010; 126(3): 858–868.
64. Salibian A.A., Widgerow A.D., Abrouk M., Evans G.R.: Stem cells in plastic surgery: a review of current clinical and translational applications. Arch Plast Surg., 2013; 40(6): 666–675.
65. Yoshimura K., Sato K., Aoi N., Kurita M., Hirohi T., Harii K.: Cell-assisted lipotransfer for cosmetic breast augmentation: supportive use of adipose-derived stem/stromal cells. Aesthetic Plast Surg., 2008; 32(1): 48–55; discussion 6–7.
66. Mesimaki K., Lindroos B., Tornwall J., Mauno J., Lindqvist C., Kontio R. et al.: Novel maxillary reconstruction with ectopic bone formation by GMP adipose stem cells. Int J Oral Maxillofac Surg., 2009; 38(3): 201–209.
67. Wakitani S., Mitsuoka T., Nakamura N., Toritsuka Y., Nakamura Y., Horibe S.: Autologous bone marrow stromal cell transplantation for repair of full-thickness articular cartilage defects in human patellae: two case reports. Cell Transplant., 2004; 13(5): 595–600.
68. Amann B., Ludemann C., Ratei R., Schmidt-Lucke J.A.: [Autologous bone-marrow stem-cell transplantation for induction of arteriogenesis for limb salvage in critical limb ischaemia]. Zentralbl Chir., 2009; 134(4): 298–304.
69. Bura A., Planat-Benard V., Bourin P., Silvestre J.S., Gross F., Grolleau J.L. et al.: Phase I trial: the use of autologous cultured adipose-derived stroma/stem cells to treat patients with non-revascularizable critical limb ischemia. Cytotherapy., 2014; 16(2): 245–257.
70. Ibrahim A.M., Gerstle T.L., Rabie A.N., Song Y.A., Melik R., Han J. et al.: Nanotechnology in plastic surgery. Plast Reconstr Surg., 2012; 130(6): 879e–887e.
71. Cong L., Ran F.A., Cox D., Lin S., Barretto R., Habib N. et al.: Multiplex genome engineering using CRISPR/Cas systems. Science., 2013; 339(6121): 819–823.
72. Roh D.S., Li E.B., Liao E.C.: CRISPR Craft: DNA Editing the Reconstructive Ladder. Plast Reconstr Surg., 2018; 142(5): 1355–1364.
73. Cowan P.J., Tector A.J.: The Resurgence of Xenotransplantation. Am J Transplant., 2017; 17(10): 2531–2536.
74. Lampert F.M., Momeni A., Filev F., Torio-Padron N., Finkenzeller G., Stark G.B. et al.: Utilization of a genetically modified muscle flap for local BMP-2 production and its effects on bone healing: a histomorphometric and radiological study in a rat model. J Orthop Surg Res., 2015; 10: 55.
75. Sessions J.W., Armstrong D.G., Hope S., Jensen B.D.: A review of genetic engineering biotechnologies for enhanced chronic wound healing. Exp Dermatol., 2017; 26(2): 179–185.

Liczba słów: 6570 Liczba stron: 9 Tabele: – Ryciny: 5 Piśmiennictwo: 75

DOI: 10.5604/01.3001.0013.2365 Table of content: https://ppch.pl/issue/12160

Competing interests: The authors declare that they have no competing interests.

Corresponding author: Dr Armin Kraus; Dept. of Plastic, Aesthetic and Hand Surgery, University Hospital of the Otto-von-Guericke University at Magdeburg, Leipziger Str. 44, 39120 Magdeburg, Germany; Phone: +49 391 67 15599; E-mail: armin.kraus@med.ovgu.de

Cite this article as: Kraus A., Infanger M., Meyer F.: What does a (general and abdominal) surgeon need to know on plastic surgery?; Pol Przegl Chir 2019: 91 (5): 42–51