

Is Ozone (O₃) Treatment Effective in Atrophic Rhinitis? Experimental Animal Study

Bengül Altaş¹, Hasan Emre Koçak², Serdar Altınay³, Kadir Yücebaş¹, Ümit Taşkın¹, Mehmet Faruk Oktay¹

¹Bağcılar Training and Research Hospital, Department of Otorhinolaryngology - Head and Neck Surgery, Istanbul, Turkey

²Bakırköy dr Sadi Konuk Training and Research Hospital, Department of Otorhinolaryngology – Head and Neck Surgery, Istanbul, Turkey

³Bakırköy dr Sadi Konuk Training and Research Hospital, Department of Pathology, Istanbul, Turkey

Article history: Received: 26.05.2018 Accepted: 19.06.2018 Published: 30.10.2018

ABSTRACT:

Introduction: Atrophic rhinitis (AR) is a disease characterized by atrophy of the mucosa, submucosa, bone tissue due to an unknown cause and excessive nasal cavity enlargement. The disease still has no complete treatment, and the treatment of functional loss of atrophic cells in AR is still a matter to be investigated. Ozone (O₃) therapy has been shown to enhance cell metabolism, angiogenesis, fibroblast activity and collagen synthesis.

Aim: To determine whether ozone treatment affects the disease histopathologically, in experimentally created AR.

Material - Method: Twelve Wistar Hanover strain albino male rats were included in the study. Atrophic rhinitis was induced in animals by administering Pasteurella multocida toxin diluted with saline for 21 days to both nasal cavities. A total of 12 animals included in the study were divided into 2 groups as control and study. Ozone gas (60 µg/mL) was administered rectally to the study group for 21 days. After 2 weeks, the rats were decapitated, the nasal cavities were removed as a block, and atrophic rhinitis parameters (epithelial hyperplasia, goblet cell loss, cilia loss, inflammatory infiltration and vascular ectasia) were evaluated under light microscopy by histopathological examination and statistically interpreted.

Result: The incidence of vascular ectasia was significantly lower in the ozone group compared to the control group (p<0.05). There was no significant difference between the groups regarding other histopathologic findings.

Conclusion: Ozone treatment was moderate at the histopathological level. We concluded that ozone therapy has no or very limited effect on atrophic rhinitis.

KEYWORDS:

atrophic, rhinitis, ozone, treatment, rat

INTRODUCTION

Atrophic rhinitis is a chronic rhinitis characterized by the progressive atrophy of the nasal mucosa and conchae, the presence of viscous secretion rapidly turning to crusts and foul smell. First, in 1876, Fraenkel described atrophic rhinitis as crust formation, nasal mucosal atrophy and foul smell triad (1). Atrophy and dryness of the nasal mucosa are accompanied by symptoms such as halitosis, nasal obstruction, anosmia and create the ground for secondary infections. Worldwide, the prevalence varies, and it is observed more in tropical regions. It is frequently seen in middle-aged young women and of Asian, Spanish descent, and Afro-American descent, as getting close to the equator, the prevalence decreases. (2). In the last century, there has been a decrease in the incidence of the disease. This is

thought to be due to the fact that infections may be effectively treated with antibiotics (3). The diagnosis may be made by taking the patient's anamnesis, examining the internal structures of the nose, performing computerized tomography (CT) with endoscopic nasal and nasopharyngeal examination, as well as culturing of nasal secretions. Treatment is aimed at eliminating predisposing factors and moistening the nasal cavity, clearing crusts, making the mucosa functional (4).

Atrophic rhinitis is a progressive inflammatory process characterized by the development of atrophic and fibrotic changes of all parts of the nose (5). It has been seen that the nasal mucosa limited to respiratory epithelium shows metaplastic changes ranging from ciliated stratified columnar epithelium to squamous epithelium. Partial or severe meta-

plasia may be seen with keratinization or without keratinization (6). Lamina propria and submucosa may show chronic cellular infiltration granulation and fibrosis. The flattened squamous epithelium loses its mucociliary clearance ability, thus causing secondary crusting. Also, glandular atrophy occurs. Glands disappear in the lamina propria, submucosa. Seromucous glands cannot fulfill their functions and lose their moisturizing properties (7). At the electron microscope, the cilia are observed either damaged or missing, which makes the mucus movement ineffective. Vascular structures are also affected in the disease (8).

In order to understand the pathophysiology of the disease and to develop more effective treatments, toxigenic *Bordetella bronchiseptica* or *Pasteurella multocida* bacteria are generally inoculated after chemical irritation of the nasal mucosa or by injecting bacterial toxin to establish disease models to create atrophic rhinitis models in animals (9).

Bordetella bronchiseptica and *Pasteurella multocida* or their toxins are known to cause AR in pigs and some other herd animals (10). *Bordetella bronchiseptica* and *Pasteurella multocida* toxins have destructive effects on tissues by changing cellular events by affecting intracellular second messenger proteins (11).

Ozone was discovered in 1840 for the first time by chemist Christian Friedrich Schönbein (12). Ozone forms one of the most important gases in the stratosphere that surrounds the earth and absorbs harmful UV rays from the Sun. Thus, it plays an important role in the continuation of the biological equilibrium of the Earth. (13)

Ozone has a strong anti-oxidation ability. For this reason, it acts as bactericide, virucide, and fungicide. Due to these properties, it is used to correct nearly 260 pathological conditions. (12,14) It is stated that after ozone administration, there are 12 different effects occurring in the organism. These are mainly showed as: activation of cell metabolism, stimulation of erythrocyte metabolism to increase oxygen uptake capacity of hemoglobin and thus increasing the amount of oxygen in tissues, strengthening the immune system, lowering free radical levels, angiogenesis, increasing fibroblast activity and collagen synthesis. This provides activation of the endothelial, parenchymal and blood cells that enable an organism to respond therapeutically and biologically to diseases. (12,13,15)

In this study, we aimed to determine histopathologically whether or not this antioxidant, cell renewal, angiogenesis actions of ozone have any positive effect on atrophic rhinitis which is created by *Pasteurella multocida* toxin.

MATERIAL-METHOD

Ethics Committee

This study was carried out at Bağcılar Training, and Research Hospital Experimental Research and Skills Development Center with the approval of ethics committee numbered 2013/8.

Healthy, adult, Wistar Hanover strain, 12 albino male rats weighing 250-350 grams were included in the study. The animals in the experiment were housed in polyethylene cages, 6 in each, and fed with standard laboratory bait. The veterinarian examination of the animals showed no systemic or nasal pathology.

Creating experimental AR

Active *Pasteurella multocida* toxin (PMT) was prepared by diluting homogenously with saline by calculating minimal toxic dose per kilogram (0.4 ug/kg) (9-10). All rats were given 0.1 cc PMT to both nasal cavities during inspiration for 21 days to create experimental AR. After 21 days, a punch biopsy was taken from the nasal cavity of 2 rats, and the AR findings were confirmed by the pathologist (Figure 1).

Grouping

A total of 12 animals were randomly assigned to two groups:

Group 1: After creating atrophic rhinitis in 6 rats, 3 mL intra-rectal ozone gas (60 µg/mL) (Hyper Medazon, Germany) was administrated 2 times a day for 21 days. (study group) (Figure 1).

Group 2: No treatment was given to 6 rats after creating atrophic rhinitis (control group) (Figure 1).

Histopathological Examination

Two weeks after ozone treatment, the rats were decapitated by cervical dislocation after anesthesia with 50 mg/kg ketamine hydrochloride and 5 mg/kg xylazine combination intraperitoneally. The nasal cavities of the sacrificed rats were removed as an enblock together with lip skin and sent to pathological examination in 10% buffered formaldehyde. Right/left tissue sections were taken from the excised specimens to include nasal mucosa and injection site. The tissues were fixed for 1 day in 10% buffered formol solution. After routine tissue processing, they were bathed in paraffin and sections with a thickness of 3 µm were taken. After staining with Hematoxylin and Eosin (H&E), the preparations were evaluated under light microscopy (Olympus BX51) for detection of histopathological changes.

Tab. 1. Statistical analysis of histological parameters between groups.

	CONTROL GROUP			OZONE GROUP			P
	MEAN±S.D.	MEDIAN	MIN-MAX	MEAN±S.D.	MEDIAN	MIN-MAX	
Epithelial hyperplasia	1,83 ± 0,75	2,0	1–3	1,63 ± 0,52	2,0	1–2	0,607
Goblet cell loss	2,17 ± 0,75	2,0	1–3	1,63 ± 0,52	2,0	1–2	0,147
Cilia loss	2,50 ± 0,55	2,5	2–3	1,88 ± 0,64	2,0	1–3	0,082
Inflammatory infiltration	2,17 ± 0,75	2,0	1–3	1,63 ± 0,52	2,0	1–2	0,147
Vascular ectasia	2,17 ± 0,75	2,0	1–3	1,38 ± 0,52	1,0	1–2	0,049

Mann-Whitney U test

Histopathological analysis was performed using histologic scales in accordance with the literature, including epithelial hyperplasia, goblet cell loss, cilia loss, inflammatory infiltration and vascular ectasia in the surface epithelium (Figure 2). Previous studies were taken as reference for scoring over 3; 1=minimal, 2=moderate, 3=severe. (16).

Statistical Method

Mean, standard deviation, median, lowest and highest values were used in the descriptive statistics of the data. The distribution of the variables was controlled with Kolmogorov Smirnov test. The Mann-Whitney U test was used for quantitative analysis. SPSS 22.0 program was used in the analyzes.

RESULTS

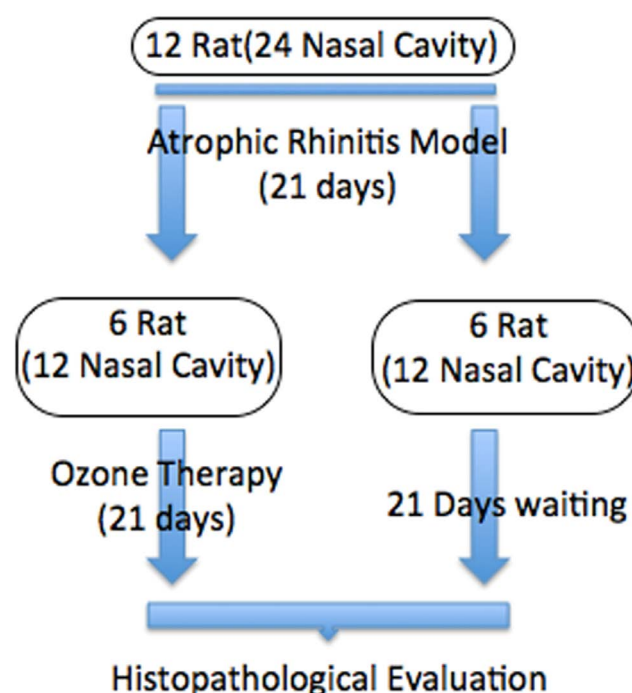
The incidence of epithelial hyperplasia was 1.63 ± 0.52 in the ozone group and 1.83 ± 0.75 in the control group. No statistically significant difference was found when both groups were compared to each other ($p>0.05$) (Table 1) (Figure 3).

The incidence of goblet cell loss was 1.63 ± 0.52 in the ozone group and 2.17 ± 0.75 in the control group. No statistically significant difference was found when both groups were compared to each other ($p>0.05$) (Table 1) (Figure 3).

The incidence of cilia loss was 1.88 ± 0.64 in the ozone group and 2.50 ± 0.55 in the control group. No statistically significant difference was found when both groups were compared to each other ($p>0.05$) (Table 1) (Figure 3).

The incidence of inflammatory infiltration was 1.63 ± 0.52 in the ozone group and 2.17 ± 0.75 in the control group. No statistically significant difference was found when both groups were compared to each other ($p>0.05$) (Table 1) (Figure 3).

The incidence of vascular ectasia was 1.38 ± 0.52 in the ozone group and 2.17 ± 0.75 in the control group. A statistically

**Fig. 1.** Process of experimental animal study

significant difference was observed when both groups were compared to each other ($p<0.05$) (Table 1), (Figure 3).

DISCUSSION

Atrophic rhinitis, also known as ozaena, is a chronic and progressive disease characterized by nasal mucosa crusts and nasal cavity enlargements. Although the cause of the disease is not known, *Klebsiella ozaenae*, *Corynebacterium diphtheriae* and *Perez-Hofer bacillus* strains are cultured from humans. The agent for atrophic rhinitis in animals is *Pasteurella multocida* and *Bordetella bronchiseptica* (17).

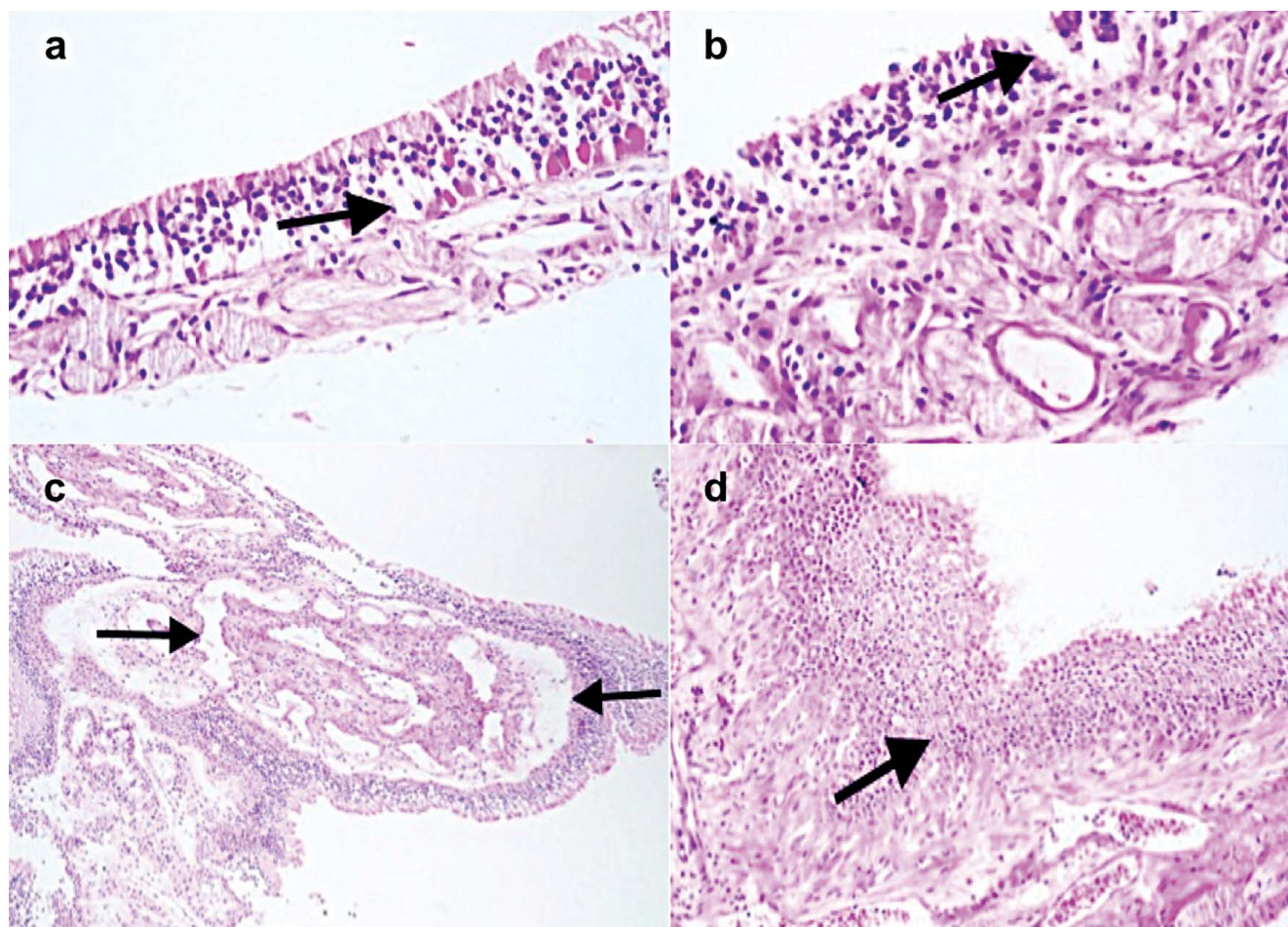
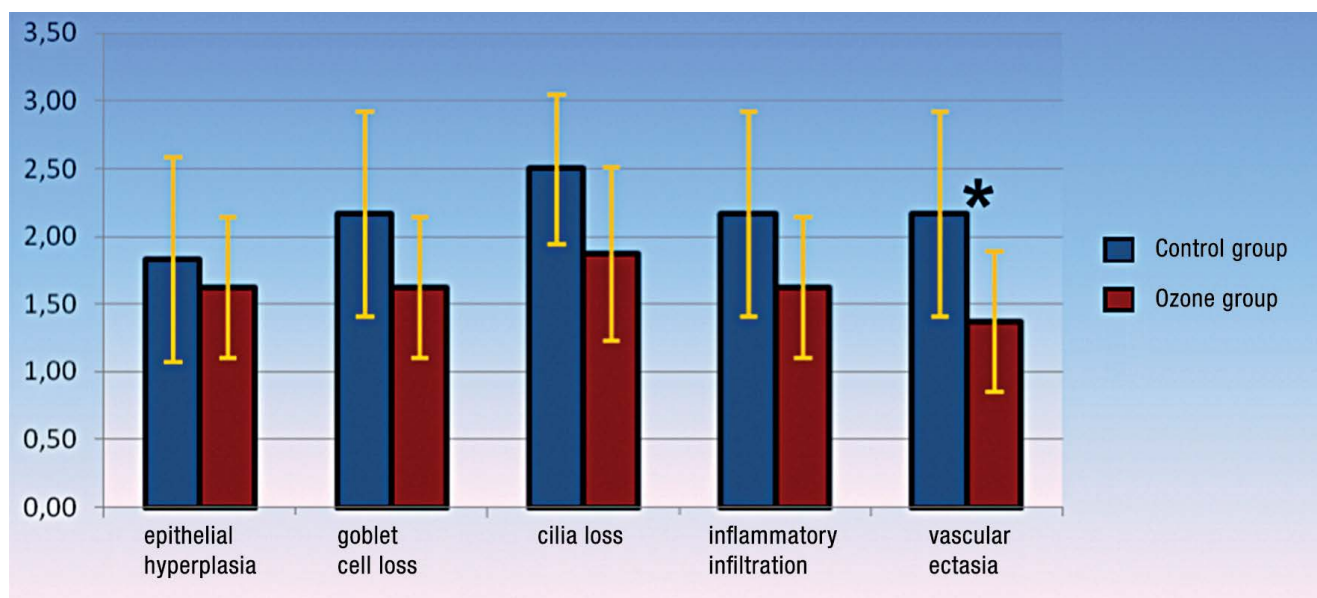


Fig. 2. a: Goblet cell presence (black arrow) and cilia in the group treated with ozone (H&E; x200). b: Cilia and goblet cell loss in the *Pasteurella multocida* inoculated group (control group) (H&E; x400). c: Thick-walled vascular structures (black arrows) accompanying epithelial hyperplasia are noted (H&E; x100). d: Apparent hyperplasia in the respiratory epithelium in the *Pasteurella multocida* inoculated group (control group) (H&E; x100).

Atrophic rhinitis is often created by direct bacterial inoculation or bacterial toxin injections to form animal models. In our study, however, we gave the toxin to nasal mucosa topically and created atrophic rhinitis. In the literature, in an animal model, Jordan et al. described in 2003 the following: nasal mucosa in rats was destroyed with acetic acid for seven days, and then toxigenic *Pasteurella multocida* bacteria were inoculated to the nasal cavity. In this way, the bacteria were colonized in the nasal cavity, and AR was created (18). In our study, after the toxin was diluted with saline, the method described by Rohrbach et al. used in their study was similarly applied to the nasal cavity by a minimally invasive method (19).

Two characteristic pathological findings of atrophic rhinitis that include vascular structures are described in humans. The most common type 1 endarteritis obliterans, periarteritis is periarterial fibrosis seen in the distal arteries. Type 2 is the

less common type with capillary vasodilatation. Histopathologic findings of atrophic rhinitis, epithelial status, the status of tunica propria, status of blood vessels and status of mucosal glands are evaluated. The epithelium is generally dominated by squamous metaplasia at various levels. While granulation tissue in tunica propria is observed, mucosal glands show mostly decrease in size and number. (20) Five parameters of atrophic rhinitis were used to histologically observe the effects of ozone therapy on AR in our study (Figure 2). Although vascular ectasia was statistically significant in the ozone therapy group compared to the control group, the difference between the two groups regarding other parameters was not significant. Despite being insignificant, it was found that epithelial hyperplasia, goblet cell loss, cilia loss and inflammatory infiltration were less frequent in the ozone group than in the control group (Table 1). It may be said that the ozone has a moderate effect on this vascular injury which is deteriorated in atrophic rhinitis.



Ryc. 3. Graphic evaluation of histopathological parameters of control group and ozone group. * statistical significant

A wide variety of protocols have been tried in the literature in the treatment of atrophic rhinitis. However, most of these treatments are conservative (such as nasal irrigation, glucose-glycerin, liquid paraffin) (4). The vicious circle between antibiotics, vasodilator drugs and atrophic rhinitis infection and atrophy was attempted to break (21). Surgery has been used for the same purpose by reducing the size of the nasal cavity and preventing mucosal dryness. For this purpose, cartilage or prosthesis have been used mostly (8). In the treatment of atrophic rhinitis, it is also aimed to improve the nasal mucosa healing besides narrowing the nasal cavity. Although many materials have been tried, still satisfactory results have not been obtained, and studies continue.

Ozone creates an oxidative effect in the organism, activating the antioxidant enzyme systems. Subsequent to the administration, ozone immediately reacts with antioxidants such as polyunsaturated fatty acids, uric acid, ascorbic acid, and albumin. During these very fast-developing reactions, all ozone is neutralized. Especially, hydrogen peroxide (H_2O_2), reactive oxygen radicals (ROS) and lipid oxidation products (LOP) arise. Activation of antioxidant enzymes (superoxide dismutase (SOD), catalase (CAT) and glutathione peroxidase (GSH-Px)), which provide body defense against these increased free radicals, is increased. Activation of endothelial, parenchymal and blood cells, which provides the therapeutic and biological response of the organism to diseases, is thus provided (14,15). There are many studies in the literature that examine the effect of ozone on wound healing. Valacchi et al. reported that

long-term exposure of chronic wounds to pure ozone delays wound healing, while administration of ozone as oxygen/ozone mixtures or as ozonated oils provide benefits by reducing bacterial counts, providing oxygenation, and accelerating wound healing (22). The dose of ozone used in wound healing is also very important. Travalgi et al. showed that the application at very low and very high doses delayed wound healing and that much more positive results could be obtained at moderate ozone concentrations (23). In the acute or chronic wound area exposed to ozone, it is stated that the activity of growth factors, which are extremely important in wound healing, is increased. Accordingly, angiogenesis, fibroblast activity, and collagen synthesis have been shown to increase (24,25,26). In a study by Lee MG et al., prolonged ozone inhalation for 8 hours/day for 3 months has been shown to reduce cutaneous injury in cytotoxicity due to 1-nitronaphthalene (1-NN) in the nasal mucosa (26). In our study, we also obtained positive results in atrophic rhinitis similar to the effective results of the ozone treatment mentioned in the literature. Five parameters were used for histopathological observations of the effects of intrarectal ozone treatment on AR in our study which are epithelial hyperplasia of the atrophic rhinitis, goblet cell loss, cilia loss, inflammatory infiltration and vascular ectasia. Although the mean values of epithelial hyperplasia, goblet cell loss, cilia loss and inflammatory infiltration were found to be decreased in the study group compared to the control group, the difference between the two groups was not statistically significant. In this study, vascular ectasia was found to be significantly lower in the study group than in the control group. Therefore, it was

determined that this histopathological criterion of atrophic rhinitis was significantly reduced by ozone therapy.

Our work had some limitations. When the animal model was planned, we observed that live bacteria were used in the literature, however since isolation conditions were not provided in our laboratory, AR was created with *Pasteurella multocida* toxin. We also believe that it is better to increase sample numbers and better standardize histologic findings so that the disease can be better modeled. We think that more studies are needed to develop more curative treatments for AR.

CONCLUSION:

As a result of our study, it was observed that one of the pathological parameters of atrophic rhinitis (vascular ectasia) decreased statistically significantly in the ozone therapy group. Apart from this, although it was not statistically significant, epithelial hyperplasia, goblet cell loss, cilia loss and inflammatory infiltration were found to be less pronounced in the ozone group compared to the control group. According to results of our study, ozone treatment in atrophic rhinitis has no or very limited effect at the histopathologic level.

REFERENCES

1. Shehata M.A.: Atrophic rhinitis. *Am. J. Otolaryngology*. 1996; 17: 81–86.
2. Moore E.J., Kern E.B.: Atrophic rhinitis: a review of 242 cases. *Am. J. Rhinol*. 2001; 15: 355–361.
3. Trepanier H., Martineau-Doize B., Martineau G.P.: Effect of *Bordetella bronchiseptica* on the osseous tissues of the nasal ventral conchae of the piglet. *Proc. 10th Int. Pig. Vet Soc. Congr.* 1988: 36.
4. Jaswal, A., Jana, A.K., Sikder, B. et al.: Novel treatment of atrophic rhinitis: early results. *Eur. Arch. Otorhinolaryngol*. 2008; 265: 1211–1217.
5. Park M.J., Jang Y.J.: Successful management of primary atrophic rhinitis by turbinate reconstruction using autologous costal cartilage. *Auris Nasus Larynx*. 2017 Jun 29. pii: S0385-8146(16)30548-X.
6. Udrescu S., Fircă D.: [Proposed modification of the Lautenschläger method for re-calibration of the nasal fossae in ozena]. *Otorinolaringologie*. 1971; 16: 275–278.
7. Sajjad A.: A new technique for nasal stent fabrication for atrophic rhinitis: a clinical report. *J. Prosthodont*. 2011; 20: 326–328.
8. Goldenberg D., Danino J., Netzer A., Joachims H.Z.: Plastipore implants in the surgical treatment of atrophic rhinitis: technique and results. *Otolaryngol. Head Neck Surg*. 2000; 122: 794–797.
9. Martineau-Doizé B., Dumas G., Larochelle R., Frantz J.C., Martineau G.P.: Atrophic rhinitis caused by *Pasteurella multocida* type D: morphometric analysis. *Can. J. Vet Res*. 1991; 55: 224–228.
10. Sakano T., Okada M., Taneda A., Mukai T., Sato S.: Effect of *Bordetella bronchiseptica* and serotype D *Pasteurella multocida* bacterin-toxoid on the occurrence of atrophic rhinitis after experimental infection with *B. bronchiseptica* and toxigenic type AP *multocida*. *J. Vet Med. Sci*. 1997; 59: 55–57.
11. Wilson B.A., Ho M.: Cellular and molecular action of the mitogenic protein-deamidating toxin from *Pasteurella multocida*. *FEBS J*. 2011; 278: 4616–4632.
12. Bocci V. Scientific and medical aspects of ozone therapy. State of the art. *Archives of Medical Research* 2006; 37:425–435.
13. Nogales C., Ferrari P., Kantarovich E.: Ozone therapy in medicine. *The Journal of Contemporary Dental Practice*. 2008; 9: 75–84
14. Madej P., Plewka A., Madej, J., Nowak M., Plewka D.: Ozonotherapy in an induced septic shock. I. Effect of ozonotherapy on rat organs in evaluation of free radical reactions and selected enzymatic systems. *Inflammation*. 2007; 30: 52–58.
15. Li L.J., Yang Y.G., Zhang Z.L., Nie S.F., Li Z., Li F., Hua H.Y., Hu Y.J., Zhang H.S., Guo Y.B.: Protective effects of medical ozone combined with traditional Chinese medicine against chemically-induced hepatic injury in dogs. *World Journal Gastroenterology*. 2007; 13: 5989–5994.
16. Parkins C.S., Fowler J.F., Yu S.: Murine model of lip epidermal/mucosal reactions to X-irradiation. *Radiother. Oncol*. 1983; 1: 159–165.
17. Lee J.Y., Byun J.Y.: Primary atrophic rhinitis. *Otolaryngol. Head Neck Surg*. 2010; 143: 601–602.
18. Jordan R.W., Roe J.M.: An experimental mouse model of jordan rhinitis of swine. *Vet Microbiol*. 2004; 103 :201–207
19. Rohrbach S., Junghans K., Köhler S., Laskawi R.: Minimally invasive application of botulinum toxin A in patients with idiopathic rhinitis. *Head Face Med*. 2009; 5: 18.
20. Bist S.S., Bisht M., Purohit J.P., Saxena R.: Study of histopathological changes in primary atrophic rhinitis. *ISRN Otolaryngol*. 2011; 2011: 269479.
21. Payne S.C.: Empty nose syndrome: what are we really talking about? *Otolaryngol. Clin. North Am*. 2009; 42: 331–337.
22. Valacchi, G., Fortino, V., Bocci, V.T.: The dual action of ozone on the skin. *The British Journal Dermatology*. 2005; 153: 1096–1100.
23. Travagli V., Zanardi I., Valacchi G., Bocci V.: Ozone and ozonated oils in skin diseases: A review. *Mediators of Inflammation*. 2010; 2010: 610418.
24. Bocci V.: Scientific and medical aspects of ozone therapy. State of the art. *Archives of Medical Research*. 2006; 37: 425–435.
25. Bocci V.: The case for oxygen-ozonotherapy. *British Journal of Biomedical Science*. 2007; 64: 44–49.
26. Kim H.S., Noh S.U., Han Y.W., Kim K.M., Kang H., Kim H.O., Park Y.M.: Therapeutic effects of topical application of ozone on acute cutaneous wound healing. *Journal of Korean Medical Science*. 2009; 24: 368–374.

Word count: 2950 Tables: 1 Figures: 3 References: 26

Access the article online: DOI: 10.5604/01.3001.0012.1265 Table of content: <https://otolaryngologypl.com/issue/11425>

Corresponding author: Dr. Hasan Emre KOÇAK, Bakırköy Dr. Sadi Konuk Eğitimve Araştırma Hastanesi Zuhuratbaba Mah. Tevfik Sağlam Cad. No: 11, Bakırköy, İstanbul, Türkiye, tel.: 0905324630517, e-mail: drhekkbb@gmail.com

Copyright © 2018 Polish Society of Otorhinolaryngologists Head and Neck Surgeons. Published by Index Copernicus Sp. z o.o. All rights reserved.

Competing interests: The authors declare that they have no competing interests.

Cite this article as: Altaş B., Koçak H., E., Altınay S., Yücebaş K., Taşkın Ü., Oktay M., F.; Is Ozone (O₃) Treatment Effective in Atrophic Rhinitis? Experimental Animal Study; Otolaryngol Pol 2018; 72 (5): 36-43
