INDEX COPERNICUS INTERNATIONAL

ORIGINAL ARTICLE

Subjective and objective assessment of voice quality in pregnancy

Authors' Contribution:
A – Study Design
B – Data Collection
C – Statistical Analysis
D – Data Interpretation
E – Manuscript Preparation
F – Literature Search
G – Funds Collection

Bożena Kosztyła-Hojna[ABDE], Anna Łobaczuk-Sitnik[BDEF], Jolanta Biszewska[DEF], Diana Moskal-Jasińska[DEF], Anna Kraszewska[DEF], Maciej Zdrojkowski[BCD], Emilia Duchnowska[EF]

Department of Clinical Phonoaudiology and Logopedics, Medical University of Bialystok, Poland ; Head: PH MD Bożena Kosztyła-Hojna

Article history: Received: 11.10.2018 Accepted: 13.12.2018 Published: 14.12.2018

ABSTRACT:

During pregnancy, voice quality disorders may occur in the form of: edema, dryness, nervousness. The aim of the study was a subjective and objective evaluation of voice quality in pregnant women. The study included 20 women in the third trimester of pregnancy, age 20-31 years, diagnosed at the Department of Clinical Phonoaudiology and Logopedics, Medical University of Bialystok.

Subjective assessment was based on the GRBAS scale. Objective assessment of the vocal organ used the HSDI (High Speed Digital Imaging) technique. In the laryngeal visualization, high-speed (HS) camera using rigid endoscope with 90° optics was used. Vibration of vocal folds was recorded during phonation of vowel "e" at 4000 frames/sec. The glottal closure (GTs), symmetry, regularity and synchronization of vocal fold vibration were assessed. When estimating the degree of glottal insufficiency, kymography of the larynx was performed by analysis of the value of Open Quotient (OQ). Objective acoustic evaluation of voice was also conducted using DiagnoScope Specjalista Program.

Hoarseness was observed in 15 pregnant women, whereas voice fatigability in 20 patients. With HSDI, the edema of vocal folds was observed in a part of the group. Decreased MPT was found in all examined women in the third trimester of pregnancy.

Hoarseness and fatigability of voice are the most frequent subjective symptoms of the voice organ in the third trimester of pregnancy. Decreased MPT is recorded objectively, as well as edema and insufficiency of vocal folds, using the HSDI technique.

KEYWORDS: HSDI, DKG, voice disorders, pregnancy

INTRODUCTION

Voice is the basic tool enabling verbal communication with the environment. The larynx belongs to the tertiary sexual features and is susceptible to hormones, from the period of puberty to old age [1, 8].

During pregnancy, a significant increase in the level of estrogen and progesterone is observed. Under the influence of sex steroids, in the mucosal membrane of the larynx, congestion and edema are observed, caused by increased permeability of blood vessels and accumulation of fluid in the interstitial spaces. Edematous changes in the larynx may be accompanied by dryness of the mucosal membrane of the upper respiratory tract [1, 8].

The above morphological changes may decrease voice quality (laryngopathia gravidorum). On auscultation, the voice becomes coated, rough, hoarse with a low fundamental frequency. There are three basic clinical forms of dysphonia during pregnancy: edema, dryness, nervousness.

In many cases, vasomotor disorders within the nasal mucosa (pregnancy-related rhinitis) may impair nasal patency and indirectly affect the voice color, causing closed rhinolalia [6]. Gastro-oesophageal reflux, which usually occurs in the third trimester of pregnancy, also deteriorates voice quality. Woman, during pregnancy, experiences many changes in the physiological, metabolic and anatomical systemic parameters [2].

The aim of the study was subjective and objective evaluation of voice quality in women in the third trimester of pregnancy.

MATERIAL AND METHODS

The study involved 20 pregnant patients in the III trimester of pregnancy – I group (examined group) and 20 women in the same age but not pregnant – group II (control group). The patients were diagnosed at the Department of Clinical Phonoaudiology and Logopedics, Medical University of Bialystok in 2018. The age of patients in the first group ranged from 20 to 31 years and amounted to an average of 23 years. Women were non-smokers, and no GERD or chronic inflammatory diseases of the upper respiratory tract were observed. The control group consisted of women aged 19 to 30 years, the average age being 24, healthy, non-smokers.

Subjective evaluation of voice quality was conducted using the GRBAS scale.

Larynx visualization included application of High-Speed Digital

Imaging (HSDI) technique as well as high-speed camera – High Speed (HS) in the HRES Endocam 5562 system by Richard Wolf GmbH. In the examination, a rigid endoscope with 90° optics, of the same producer was used. The examination was conducted during phonation of vowel „e". The 2-second recorded vibration sequence of both vocal folds was analyzed, recording the image at 4000 frames per second. The saved image was analyzed for 8.88 minutes using the play-back function. The asymmetry of vibration of vocal folds according to the 4-point Shaw-Deliyski scale [15] was assessed, with 1 point meaning mild asymmetry, 2 points moderate asymmetry, 3 points – severe asymmetry, and 4 and more points – profound asymmetry. Glottal Closure Types (GTs) were evaluated in accordance with the Committee on Phoniatrics of the European Laryngological Society (ELS) classification [3], diagnosing the type of phonation closure as A - rectangular, B - concave, C - triangular, D –V-shaped, E - medial. The value of the Open Quotient (OQ) in the front, middle and posterior part of the glottis was also assessed.

The voice acoustics analysis was conducted using the Diagnoscope Specialist software by DiagNova Technologies, analyzing the values of the parameters F0, Jitter, Shimmer, and NHR. A statistical analysis of the obtained results was conducted, in which a one-way analysis of variance was used, assuming the statistical significance level of P <0.05. The study was granted a consent of the Bioethical Committee No R-I-002/170/2018.

RESULTS

All patients from the first group reported voice fatigue, hoarseness and dryness of the mucosal membrane of the throat and larynx. Patients from the second group reported periodic hoarseness and fatigability of voice usually associated with a co-infection. In the perceptual evaluation of voice quality on the GRBAS scale in group I (Fig. 1), hoarseness was recorded in 10 (50%) patients, roughness in 6 (30%), strain of voice in 4 (20%), asthenic voice and breathiness of voice were not recorded. In group II, the physiological parameters in the form G-0, R-1, B-1, A-0, S-0 were found in the GRBAS scale (Tab. I). The most precise diagnostic tool is High Speed Digital Imaging (HSDI) technique, allowing for imaging of real vibrations of the vocal folds and the geometry of the vocal channel during breathing and phonation [9, 10, 11, 12].

In the examined group, HSDI recorded a slight edema and congestion of vocal folds in 14 (70%) pregnant subjects, while in the remaining 6 (30%) patients the physiological image was recorded (Fig. 2). In this group, a moderate mucosal wave (MW) asymmetry was recorded in 3 (15%) patients, mild – in 10 (50%) and – physiological MW in 7 (35%). The type of glottal closure was classified as type B in 3 women (15%), as type C – in 11 (55%) and as complete phonatory glottal in 6 (30%) pregnant women. The average value of the OQ coefficient was 0.23 in the anterior part, 0.5 – in the middle part, and 0.82 – in the posterior part (Tab. II and III).

No pathological features of the vocal organ were found in the control group. In 16 (80%) women, physiological MW was observed, and in 4 (20%) – mild asymmetry. A complete glottal closure was found in 15 (75%) women, type C – in 5 (25%). The average value of the OQ coefficient was 0.33 – in the anterior part, 0.43 – in the middle, and 0.52 – in the posterior part. In the examined group, the mean MPT value was 7.9 sec. and in group II – 22.3 sec. (Fig. 3)

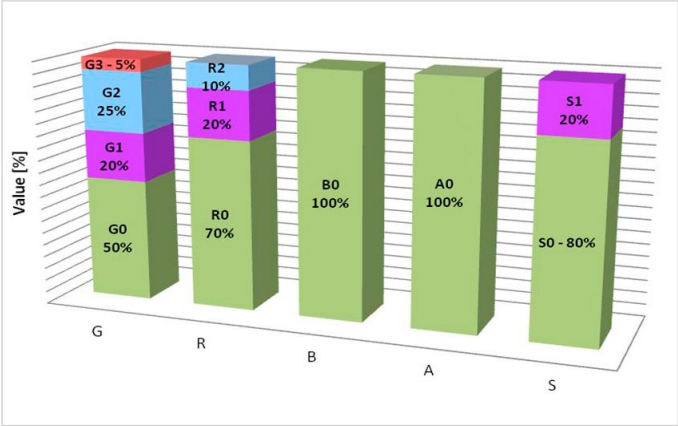

Fig. 1. Perceptual evaluation of GRBAS scale parameters in the study group.

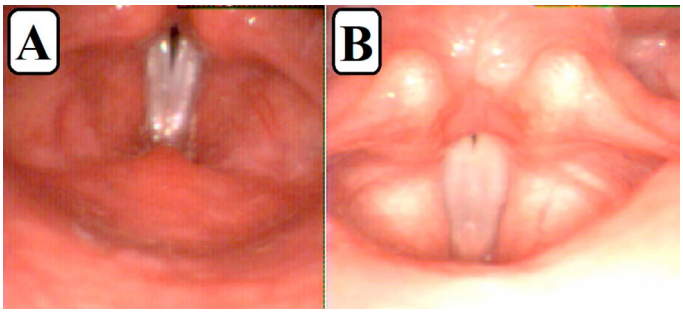

Fig. 2. Image of vocal folds, HSDI technique – examined group (A) and control group (B).

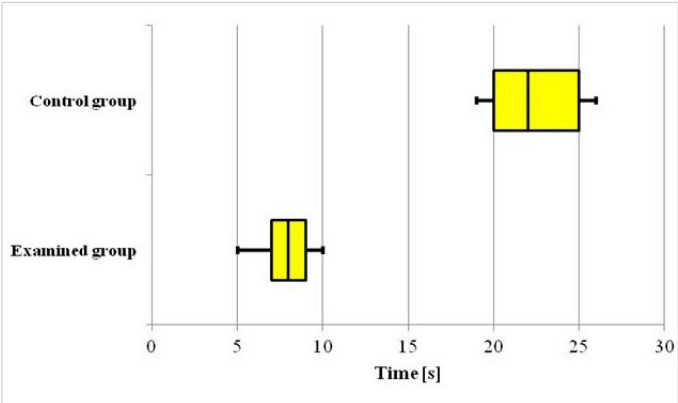

Fig. 3. Comparison of MPT values in the examined and control group.

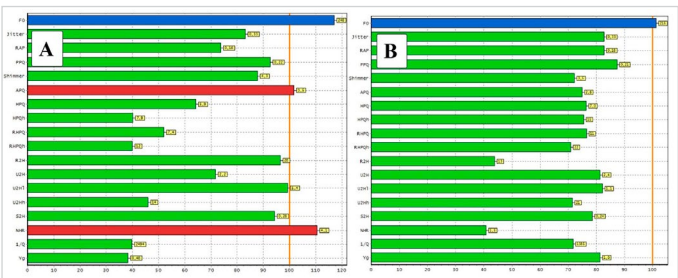

Fig. 4. Parametric evaluation of voice quality in the examined (A) and control (B) group.

In the acoustic assessment of voice in the examined group, no significant increase of F0, Jitter, Shimmer and NHR parameters was found in relation to the normal value. In the control group, the parameters analyzed reached physiological values (Fig. 4).

DISCUSSION

Pregnancy is a special period in a woman's life that requires anatomical, physiological and metabolic adaptations. The body is subject to many alterations under the influence of elevated levels of steroid hormones [16]. The fetus and placenta are an additional source of production of steroids which pass to the maternal circulation [5]. Elevated levels of estrogen increase mucus production, reduce its viscosity and dilate blood vessels. In contrast, increased levels of progesterone reduce the production of mucus and increase its viscosity leading to dehydration and thinning of the mucosal membrane of the vocal folds [1]. In pregnant women a significant increase in water content in the body is observed, which is an expression of adaptation to pregnancy and at the same time affects the quality of voice [6]. During pregnancy, the laryngeal membrane becomes congested and edematous. An increase in the mass of the vocal fold may cause hoarseness. Along with the development of pregnancy, the posture of a woman, lung capacity, pattern of breathing become different. Reflux and edema of vocal folds may appear, which, according to V.L. Cassiraga [2], affects voice quality. During pregnancy, woman also undergoes psychological changes [4].

Pregnant women often reported subjectively the occurrence of periodic hoarseness, voice fatigability, particularly those who used voice professionally, as confirmed by the studies of Hamdan et al. [6] and A.B Hancock et al. [7].

La and Sundberg [13] performed laryngeal examination in a soprano singer in the third trimester of pregnancy and observed an increase in pressure threshold, which indicated an increase in epithelial thickness and tissue viscosity within the phonatory organ. In case of singers, it is recommended to avoid forced vocal training and performances during pregnancy [7, 13].

In this study, a statistically significant decrease of MPT in women in the third trimester of pregnancy was observed. Similar results were obtained in the studies by Cassiraga et al. [2] who found a decrease of MPT in pregnant patients compared to non-pregnant women. Saltürk et al. [14] also registered a decrease of MPT in the third trimester, whereas in other analyzed groups, such a difference was not found.

On the other hand, Hancock et al. [7] observed a stability of MPT values and did not observe its decrease in the third trimester of pregnancy in a pregnant woman who is a professor in the field of voice emission and linguistic sciences. This result could be the consequence of knowing and observing the principles of voice emission and hygiene by that diagnosed woman [7].

In the acoustic voice assessment, no differences were found between pregnant and non-pregnant women. It is wondering why the values of F0, Jitter, Shimmer and NHR did not differ in both groups. The frequency F0 depends primarily on strain, stiffness and mass of the vocal folds. Increasing fold mass decreases F0, however shortening, increase of strain and stiffness of the vocal fold, and increase of subglottic pressure increases F0. The edema of vocal folds with HSDI technique, which should decrease F0, is observed. On the other hand, edema and water retention reduce the surface of the glottis, which may decrease the minimum flow and as a result lead to increased effort during phonation. It may also cause an increase in the strain of vocal folds, increase of subglottic pressure, and theoretically also increase of the F0 value. No differences in F0 may result from the adaptation of the woman's body to changes that occur in the body during pregnancy.

Tab. I. Perceptual assessment of GRBAS scale parameters in the control group.

GRBAS scale parameters	G0	R1	B1	A0	S0

Tab. II. One-way analysis of variance in the examined group .

GROUPS	COUNTER	SUM	AVERAGE	VARIANCE
OQ – posterior part	20	16,56	0,828	0,013217
OQ – middle part	20	10,09	0,5045	0,015731
OQ – anterior part	20	4,6	0,23	0,009611

Tab. II. One-way analysis of variance in the examined group.

VARIANCE'S SOURCE	SS	DF	MS	F	P VALUE	F TEST
Between groups	3,584043	2	1,792022	139,4255	0,0000000000	3,158843
Within groups	0,732615	57	0,012853			
Sum	4,316658	59				

The presented studies included a small number of patients and are considered as a pilot study. It would be necessary to increase the size of the examined group and it would be most beneficial to conduct tests in every trimester of pregnancy and postpartum as well as to monitor hormone levels in correlation with changes in the larynx recorded using the HSDI technique (glottis configuration-closure type, OQ).

CONCLUSIONS

1. Voice quality of women in advanced pregnancy changes because of congestion and edema of vocal folds and phonatory insufficiency of the glottis, which has been confirmed by an objective HSDI technique.

2. Hoarseness and voice fatigue are the most frequent subjective symptoms in women in the third trimester of pregnancy.

3. In women in advanced pregnancy, a statistically significant reduction of Maximum Phonation Time was found.

4. The acoustic analysis of voice showed no significant changes in voice quality parameters in women in advanced pregnancy.

REFERENCES

1. Quesnel AM, Ishai R, McKenna MJ. Otosclerosis: Temporal Bone Pathology. Abitbol J., Abitbol P., Abitbol B.: Sex hormones and the female voice. J Voice, 1999; 13 (3): 424–446.
2. Cassiraga V.L., Castellano A.V., Abasolo J., Abin E.N., Izbizky G.H.: Pregnancy and voice: changes during the third trimester. J Voice. 2012; 26 (5): 584–586.
3. Dejonckere P.H., Bradley P., Clemente P., Cornut G., Crevier-Buchman L., Friedrich G., Van De Heyning P., Remacle M., Woisard V.: Committee on Phoniatrics of the European Laryngological Society (ELS): A basic protocol for functional assessment of voice pathology, especially for investigating the efficacy of (phonosurgical) treatments and evaluating new assessment techniques. Guideline elaborated by the Committee on Phoniatrics of the European Laryngological Society (ELS). Eur Arch Otorhinolaryngol. 2001; 258 (2): 77–82.
4. Elliott S.A., Rugg A.J., Watson J.P., Brough D.I.: Mood changes during pregnancy and after the birth of a child. Br J Clin Psychol. 1983; 22 (Pt 4): 295–308.
5. Gabbe S., Niebyl J.R., Simpson J.L.: Obstetrics: Normal and Problem Pregnancies. Churchill Living stone, New York 2007.
6. Hamdan A.L., Mahfoud L., Sibai A., Seoud M.: Effect of pregnancy on the speaking voice. J Voice, 2009; 23 (4): 490–493.
7. Hancock A.B., Gross H.E.: Acoustic and aerodynamic measures of the voice during pregnancy. J Voice, 2015; 29 (1): 53–58.
8. Hari Kumar K.V.S., Anurag Garg, Ajai Chandra N. S., Singh S. P., Rakesh Datta: Voice and endocrinology. Indian Journal of Endocrinology and Metabolism, 2016; 20 (5): 590–592.
9. Kosztyła-Hojna B., Moskal D., Kuryliszyn-Moskal A., Andrzejewska A., Falkowski D.: Morphological changes of the vocal fold mucosa in hyperfunctional dysphonia diagnosed by psychoacoustic and videostroboscopic methods. Adv Med Sci, 2011; 56 (2): 343–351.
10. Kosztyła-Hojna B., Łobaczuk-Sitnik A., Zdrojkowski M., Biszewska J., Moskal D., Sitnik P.: High-speed digital imaging in the clinical analysis of voice change as a parameter of premenstrual syndrome. Pol Merkur Lekarski, 2017; 43 (256): 181–185.
11. Kosztyła-Hojna B., Moskal D., Falkowski D., Łobaczuk-Sitnik A., Kraszewska A., Skorupa M., Kita J., Kuryliszyn-Moskal A.: High-speed digital imaging in the diagnosis of voice pathologies. Pol Merkur Lekarski, 2016; 41 (241): 26–31.
12. Kosztyła-Hojna B., Moskal D., Kuryliszyn-Moskal A., Andrzejewska A., Łobaczuk-Sitnik A., Kraszewska A., Skorupa M.: Usefulness of high-speed digital imaging (HSDI) in the diagnosis of oedematous - hypertrophic changes of the larynx in people using voice occupationally. Otolaryngol Pol, 2017; 71 (4): 19–25.
13. Lã F.M., Sundberg J.: Pregnancy and the singing voice: reports from a case study. J Voice, 2012; 26 (4): 431–439.
14. Saltürk Z., Kumral T.L., Bekiten G., Atar Y., Ataç E., Aydoğdu İ., Yıldırım G., Kılıç A., Uyar Y. : Objective and Subjective Aspects of Voice in Pregnancy. J Voice, 2016; 30 (1): 70–73.
15. Shaw H.S., Deliyski D.D.: Mucosal wave: a normophonic study across visualization techniques J Voice, 2008; 22 (1): 23–33.
16. Soldin O.P., Guo T., Weiderpass E., Tractenberg R.E., Hilakivi-Clarke L., Soldin S.J.: Steroid hormone levels in pregnancy and 1 year postpartum using isotope dilution tandem mass spectrometry. Fertil Steril, 2005; 84 (3): 701–710.

Word count: 2160 Tables: 3 Figures: 4 References: 16

Access the article online: DOI: 10.5604/01.3001.0012.7856 Table of content: https://otolaryngologypl.com/issue/11772

Corresponding author: Prof. dr hab. n. med. B. Kosztyła-Hojna, Zakład Fonoaudiologii Klinicznej i Logopedii, Uniwersytetu Medycznego w Białymstoku; 15-295 Białystok, ul. Szpitalna 37, tel: 85 748-56-52, fax: 85 748-56-51, e-mail: fono@umb.edu.pl

Copyright © 2019 Polish Society of Otorhinolaryngologists Head and Neck Surgeons. Published by Index Copernicus Sp. z o.o. All rights reserved.

Competing interests: The authors declare that they have no competing interests.

Cite this article as: Kosztyła-Hojna B., Łobaczuk-Sitnik A., Biszewska J., Moskal-JasińskaD., Kraszewska A., Zdrojkowski M., DuchnowskaE.: Subjective and objective assessment of voice quality in pregnancy; Otolaryngol Pol 2019; 73 (2): 1-5