POLSKI
PRZEGLĄD CHIRURGICZNY
2016, 88, 1, 48–53

10.1515/pjs-2016-0027

DE GRUYTER
OPEN

PENETRATING TRAUMA TO THE FACIAL SKELETON BY PICKAXE – CASE REPORT

ANETA NESKOROMNA-JĘDRZEJCZAK[1], *KATARZYNA BOGUSIAK*[1], *ALEKSANDER PRZYGOŃSKI*[1], *DARIUSZ TIMLER*[2]

Department of Cranio-Maxillofacial and Oncological Surgery, Medical University in Łódź[1]
p.o. kierownika: dr n. med. *A. Neskoromna-Jędrzejczak*
Department of Emergency and Disaster Medicine, Medical University in Łódź[2]
Kierownik: prof. dr hab. *T. Gaszyński*

Number of deaths related with injuries suffered as a result of experienced traumas is increasing. Penetrating traumas of the facial skeleton occur relatively rarely and much more often concern rather children than adults. Epidemiology relating this kind of trauma differs depending on the region of the world. In Poland, gunshot injuries as well as traumas caused by explosions of firecrackers or fireworks amount only to a slight percentage among all facial skeleton traumas, and the most common reason for penetrating traumas lies in accidents or assault with the use of sharp, narrow and long objects that easily enter bones of the facial skeleton.
The present study reported the case of 50-year-old man who suffered from trauma of the facial skeleton, which resulted from foreign body (pickaxe) penetration into the subtemporal area, zygomatic arch and the right orbital cavity. The surgical treatment method and final outcome was presented and discussed.
Key words: penetrating trauma, maxillofacial trauma, foreign body

Penetrating traumas to the facial skeleton are relatively rare and more common in children compared to adults. Penetrating traumas occur in 1.2-4% of developmental age patients hospitalized due to craniocerebral traumas.

Epidemiology of these injuries varies by geographical region. In the US the majority of penetrating traumas are caused by gunshots, less commonly by suicide attempts, self-mutilation or transport accidents (3, 4). In Poland the leading causes of penetrating traumas are accidents or beating with a sharp, slim, long objects, while traumas caused by gunshots, fireworks explosion are scarce (5).

These traumas may be classified into low- and high-energy traumas depending on the factor causing injury. Low-energy traumas are caused by penetration of a sharp foreign body. High-energy penetrating traumas are caused by firecrackers or fireworks blow or gunshots. The clinical presentation of these accidents is associated with severe injuries of the soft and hard tissues. These are characterized by extensive, lacerated wounds and multiple, polyfragmented fractures, commonly with tissue defects (6, 7).

Due to the various causes of these injuries, both the clinical presentation and extent may widely vary. The knowledge of their pathomechanisms, as well as patient management is crucial for further course of therapy and patient outcomes. This has prompted the authors to present their own observations and treatment algorithm in a patient with atypical penetrating trauma of the face and facial skeleton.

CASE REPORT

A 50-year-old patient directly following facial skeleton trauma due to pickaxe stuck in the right infratemporal fossa between the zygomatic arch and the orbit was transported in an ambulance from the place of the accident

to the hospital emergency department of the Copernicus Memorial Hospital in Łódź (fig. 1). On admission the patient maintained verbal and logical contact, with preserved auto- and allopsychical orientation, respiratory and circulatory efficient. Pulse 100 beats per minute, regular, symmetric, peripherally palpable. BP 95/60 mm Hg. Sat O_2 90%. Local physical examination revealed a pick-axe penetrating into the zygomatic area, through zygomatic, buccal, right subnasal area to left buccal area. The skin on the left cheek was tense due to soft tissue prominence from the presence of a foreign body. A mucous membrane wound in the palatine raphe area was identified intraorally. Blood cell count – morphology, electrolytes, urea, coagulogram, blood group and ethyl alcohol tests have been performed. Following stabilization and sedation of the patient with Fentanyl, a head and facial skeleton CT with 3D reconstruction was performed (fig. 2, 3). CT visualized a foreign body within the facial skeleton, causing multiple artefacts, which limited the evaluation of fractures (fig. 4, 5). No bleeding was observed in the visualized cerebral tissue. Essential consultations have been performed – neurosurgical, ophthalmological and laryngological. Neurosurgical examination did not show limb paresis or other pathological symptoms. Ophthalmological examination showed

Fig. 1. The patient with a pickaxe stuck in the right facial skeleton

reduced visual acuity of the right eye and ocular motility disorders. Laryngological examination showed obstruction of nasal passages without features of active bleeding from nasal passages and liquorrhea.

Due to the nature of injury the patient was transported to the Clinical Department of Cranio-Maxillofacial Surgery. The patient's general condition has not changed significantly during transport. Following admission laryngological and ophthalmological consultations were performed. The patient was qualified for an immediate surgical procedure. A worsening of patient's local condition was observed – the patient developed trismus and post traumatic blindness of the right eye. Due

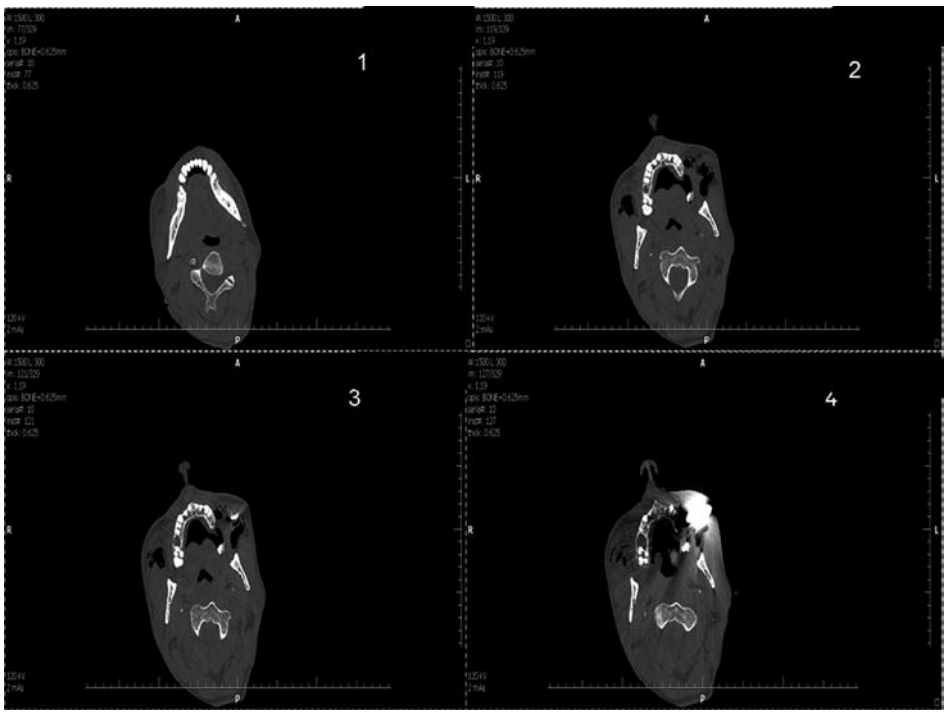

Fig. 2. CT images of the skull

Fig. 3. 3D reconstruction images of the pickaxe stuck in the facial skeleton

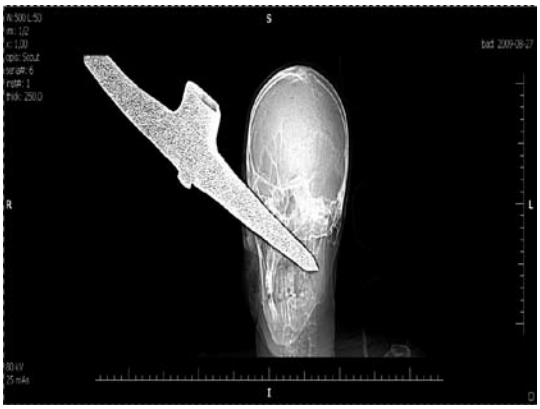

Fig. 4. CT image of the skull with a stuck pickaxe

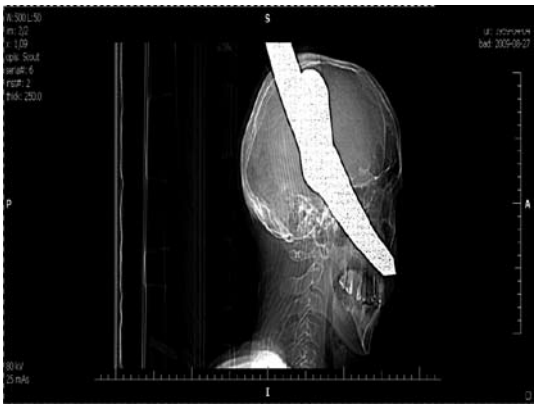

Fig. 5. CT image of the skull with a stuck pickaxe

Fig. 6. Patient during surgery – following removal of the foreign body (pickaxe)

to progressive trismus and inability to perform a nasotracheal intubation, tracheotomy was performed. An incision was made under general anaesthesia in the skin and subcutaneous tissue in the region of the penetrating pick-axe to the lateral nasal surface. Following the dissection of the soft tissues, the inferior orbital margin was revealed. The foreign body was removed (fig. 6). The penetrating trauma extended from the right infratemporal fossa through the maxillary sinus to the lumen of the maxillary sinus and soft tissues of the cheek along with the fracture of the left lateral maxillary sinus wall. No bleeding from large or medium-sized vessels was observed. Fracture of the lateral orbital wall was identified with a 2 cm indirect bone fragment, fracture of the inferior orbital wall and the zygomatic arch, orbital floor defect (5 mm from the anterior margin to the orbital cone) with fracture of the anterior wall of the left maxillary sinus.

Following the removal of loose bone fragments from the wound, a reposition of bone fragments was performed with stabilization using titanium plates, to reconstruct the lateral and inferior margin of the right orbit (fig. 7). The orbital floor was reconstructed with a titanium mesh, providing a backbone for orbital soft tissues. Normal passive mobility of the right eyeball was obtained. Hemostasis was achieved following electrocoagulation of small vessels. The patient underwent soft tissue reconstructive surgery. A drain was placed in the lumen of the right maxillary sinus. During surgery the reconstruction of the zygomatic arch bone defect and right maxillary bone was withdrawn due to primary wound contamination.

Directly following surgery the patient was transferred to the ICU, where he remained for 6 days. The patient was sedated, fed through a tube, and received anti-oedema and anti-inflammatory treatment. A daily toilet of the traumatic wounds was performed with irrigation of the right maxillary sinus for 5 days. On

Fig. 7. Patient during surgery – following reposition of the bone fragments and osteosynthesis with a titanium plate and screws

the 2 day following surgery the patient reported a regression of blindness in the right eye. A control CT examination showed a polyfragmented fracture of the zygomatic bone diaphysis and the zygomatic arch, fracture of the lateral and inferior orbital wall, the orbital floor, polyfragmented fracture of the right walls of the maxillary sinus, polyfragmented fracture of the medial and mediolateral wall of the maxillary sinus, with broken nasal septum and fracture of the part of the left hard palate. The CT images showed a surgical anastomosis of the frontal process of the zygomatic bone with zygomatic process of the frontal bone and the inferior margin of the right orbit and the titanium mesh used for reconstructions of the right orbital floor. On the third day of hospitalization at the ICU, a fluctuating lump was identified in the right temporal region and a large amount of hemolyzed blood was evacuated. The blood was sent for microbiological examination (culture was sterile). On the fourth day of hospitalization at the ICU the patient underwent ophthalmological consultation due to reported pain complaints of the right eyeball and diplopia in straight-ahead and upward gaze. Physical ophthalmological examination did not show any anterior eye segment lesions; only palpebral hyperaemia and palpebral oedema of the right eye and subconjunctival hemorrhage have been identified. The patient was then transferred to the Clinical Department of Cranio-Maxillofacial Surgery where he has been hospitalized for nine days. During hospitalization at the Department a gradual improvement of the patient's general condition was observed, and healing of postoperative wounds was uncomplicated. Following sutures removal in the 15 day post-surgery the patient was discharged in general well-being, acuity and field of vision as before injury, without features of diplopia. Normal jaw opening, without features of blocking with full opening, without functional disorders in the temporomandibular joints.

DISCUSSION

Nowadays an increase in death rate from injuries is observed. According to epidemiological data injuries are the third leading cause of death worldwide (8). In Poland more than 30,000 people die every year due to accidents, which is twice as much as in the Netherlands, and in Hungary and France more people die

Fig. 8. Patient on the day of discharge – en face and right profile

than in Poland. (8) Cranial injuries are a particular social and economic problem. The annual incidence of cranial injuries in highly developed countries is estimated at 200 per 100,000 people. Cranial injuries result in significantly higher mortality compared to injuries of other organs. They are the leading cause of death in all age groups, and are the first leading cause of death in young adults, aged below 30 (9). According to statistics the annual death rate due to craniocerebral injuries is approx. 17 per 100,000 people (10). The consequences often require long-term treatment and rehabilitation. These injuries are more common in men than in women, the death rate is 3-5 times higher in men than in women (10). Due to its location, penetrating traumas of the head and/or face may result in CNS injury and be life-threatening. Furthermore these injuries may result in the damage of large vessels, nervous trunks and also result in obstructive occlusion of upper airways (11). Both the extent, as well as serious general condition of the patient with a penetrating trauma of the face and/or head, require a prompt and comprehensive treatment. Patient with a pickaxe stuck in the infratemporal fossa was in a good general condition and maintained verbal and logical contact. A 7.5 kg foreign body stuck close to the orbit resulted in a post-traumatic blindness. Foreign body caused an optic canal compression due to development of haematoma. The removal of the pickaxe and evacuation of the clot from the lumen of the maxillary sinus, and the right orbital floor during its revision and reconstruction resulted in decompression of the optic canal. Positive results of vision restoration were achieved due to prompt intervention – up to 6 hours following trauma. Many authors suggest that surgery within 12 hours after trauma results in significant probability of regression of post-traumatic blindness and reduces the risk of persistent vision disorders (12). Revision and reconstruction of the orbital walls is therefore an effective and essential procedure to reduce post-traumatic diplopia, as well as visual field disorders with progressive vision acuity disorders, which should be performed within a few hours following trauma.

Radiological diagnostics is an important issue in patients with penetrating traumas of the face and facial skeleton due to assessment of extent of the injury and location of foreign bodies. Computed tomography (CT) is the examination of choice in patients with fractures of the facial skeleton. Despite high resolution of CT images, some metallic foreign bodies cause artefacts, which make the interpretation of results difficult or even impossible, because they result in occurrence of dark lines and areas interfering anatomical structures (13). Due to broadening of CT scans in the reported patient, which occurred from a presence of a large metallic foreign body it was possible to exclude only partially distinct bleeding focus, and the precise assessment of fractures within the facial skeleton was impossible. Only a repeated control CT examination following the removal of the foreign body showed a polyfragmented fracture of the zygomatic arch and zygomatic bone diaphysis (following reposition and osteosynthesis), fracture of the lateral orbital wall, the orbital floor (following reconstruction with a polypropylene fabric), polyfragmented fracture of the right walls of the maxillary sinus, polyfragmented fracture of the medial and mediolateral wall of the maxillary sinus, fracture of osseous walls of the inferior nasal passage with broken nasal septum and fracture of the part of the left hard palate.

Another important issue in patients with penetrating trauma of the face and facial skeleton is the selection of the treatment approach. Depending on the extent of injury the penetrating traumas may pose a significant therapeutic challenge and have an effect on delay of surgery both due to serious general condition which prompts the physician to carry out first-aid procedures, such as: ensure patency of airways, control bleeding, initiate anti-shock therapy (14), as well as local causes, e.g. post-traumatic wound infection due to sticking a contaminated tool. Extensive hard and soft tissue damage often requires the use of implants to restore defects. Reconstruction of tissue in a single-stage therapy is not always feasible due to high risk of inflammatory reaction. Therefore, the advantages and disadvantages of a multistep procedure should be considered.

In the reported patient the fractures were treated and the orbital floor was reconstructed on the day of trauma and reconstruction of bone defects in the middle facial skeleton was delayed. On the day of the accident a reposition and osteosynthesis of bone fracture was performed in the inferior, lateral orbital margin, with simultaneous reconstruction of orbital floor and local soft tissue reconstructive sur-

gery. In the second stage a secondary reconstruction of the bone defects was planned. Eventually the patient did not consent to the second stage of treatment due to patient-evaluated satisfactory aesthetic and functional outcome of the primary surgery.

CONCLUSIONS

1. Diagnostic-therapeutic management in patients following penetrating trauma of the facial skeleton should include teamwork of specialists in the field of maxillofacial surgery, ophthalmology, laryngology, neurosurgery, plastic surgery and anaesthesiology.
2. Depending on the patient's general condition therapeutic management should be individual depending on the extent of injuries, fractures should be treated according to 4E rule (early, everything, entirely, equally).
3. In the case of coexisting orbital fractures with suspected optic nerve damage, urgent reconstruction of the orbital walls is required with decompression of the optic canal.

REFERENCES

1. *Rouse TM, Eichelberger MR:* Trends in pediatric trauma menagement. *Surg Clin N America* 1992; 72(6): 1347-64.
2. *Kalińska-Lipert A, Osemlak P, Rudnik J, Osemlak J:* Epidemiologia i postacie obrażeń czaszkowo-mózgowych u dzieci. *Rocznik Dziecięcej Chirurgii Urazowej* 2005; 9: 33-40.
3. *Kauvar DS, Wade CE:* The epidemiology and modern management of traumatic hemorrhage: US and international perspectives. *Critical Care* 2005; 9: 1-9.
4. National Safety Council. Injury Facts 2008 Edition. Itasca 2008.
5. *Lewandowski B, Kulig T:* Postrzałowe obrażenia twarzy i czaszki twarzowej – przypadki własne. *Dent Med Probl* 2005; 42(2): 371-77.
6. *Demetriades D: Chahwan S, Gomez H* et al.: Initial evaluation and management of gunshot wounds to the face. *J Trauma* 1998; 45, 1: 39-41.
7. *Gaboriau HP, Kreutziger KL:* Penetrating injuries of the face. *J La State Med Soc* 1998; 150, 1: 6-9.
8. http://www.who.int/mediacentre/factsheets/fs310/en/ The top 10 causes of death. World Health Organization. Access on the 20th of October 2015.
9. *Wagner AK, Sasser HC, Hammond FM* et al.: Intentional traumatic brain injury: epidemiology, risk factors, and associations with injury severity and mortality. *J Trauma* 2000; 49(3): 404-10.
10. *Santos ME, De Sousa L, Castro-Caldas A:* Epidemiology of craniocerebral trauma in Portugal. *Acta Médica Portuguesa* 2003; 16(2): 71-76.
11. *Nicholoff TJ, Velmonte X:* Reconstructive surgery for complex midface trauma using titanium miniplates: Le Fort I fracture of the maxilla, zygomatico-maxillary complex fracture and nasomaxillary complex fracture, resulting from a motor vehicle accident. *J Philippine Dent Associat* 1998; 50(3): 5-13.
12. *Wohlrab TM, Maas S, de Carpentier JP:* Surgical decompression in traumatic optic neuropathy. *Acta Ophthalmol Scand* 2002; 80(3): 287-93.
13. Tomografia komputerowa XXI wieku – postęp w dziedzinie metod rekonstrukcji i jego wpływ na ograniczenie dawki promieniowania. Philips Healthcare. *Inżynier i Fizyk Medyczny* 2013; 2: vol. 2.
14. *Kobus K, Łątkowski I, Wójcicki P:* Współczesne poglądy dotyczące leczenia obrażeń twarzy. *Czas Stomatol* 2007; 8: 491-92.

Received: 24.10.2015 r.
Adress correspondence: 90-153 Łódź, ul. Kopcińskiego 22
e-mail: katarzyna.bogusiak@gmail.com