# Malignant melanoma of the nasal cavity mucous membrane – two cases report

## Czerniak złośliwy błony śluzowej jamy nosa – opis dwóch przypadków

**Wkład autorów:**
**A** – Study Design
**B** – Data Collection
**C** – Statistical Analysis
**D** – Manuscript Preparation
**E** – Literature Search
**F** – Funds Collection

Przemysław Krawczyk[1ABCDEFG], Dariusz Kaczmarczyk[2DE]

1 Student Research Association by the Department of Head and Neck Cancer Surgery at the Medical University of Lodz
2 Department of Head and Neck Cancer Surgery at the Medical University of Lodz, Head of the Department: Prof. Alina Morawiec-Sztandera MD PhD ul. Paderewskiego 4 93-509 Łódź dariusz.kaczmarczyk@umed.lodz.pl

Article history: Received: 19.01.2016 Accepted: 26.02.2016 Published: 30.09.2016

**ABSTRACT:** Malignant melanoma is highly aggressive type of malignant neoplasm. The skin of the head and neck region is common localisation for appearance of this tumour due to exposition to the sun light. However, some number of cases concern development of the malignant melanoma on the mucous membranes. Most common signs are epistaxis and nasal obstruction. Late diagnosis effects with poor clinical prognosis. In our case, despite complete surgical resection and adjuvant therapy, outcome of the treatment was unsatisfying, because of metastasis and local recurrence.

**KEYWORDS:** malignant melanoma, mucous membrane, nasal cavity, paranasal sinuses

**STRESZCZENIE:** Czerniak złośliwy jest wysoce agresywnym typem nowotworu złośliwego. Skóra rejonu głowy i szyi jest częstą lokalizacją dla rozwoju tego typu zmiany w związku z ekspozycją na światło słoneczne, jednak w części przypadków czerniak rozwija się w obrębie błon śluzowych. Najczęstsze objawy to krwawienia z nosa i jego niedrożność. Późno postawiona diagnoza wpływa na złe rokowanie kliniczne. W prezentowanych przez nas przypadkach, pomimo całkowitej resekcji chirurgicznej i terapii adjuwantowej, wynik leczenia był niesatysfakcjonujący z powodu wznowy miejscowej lub przerzutów odległych.

**SŁOWA KLUCZOWE:** czerniak złośliwy, błona śluzowa, jama nosa, zatoki przynosowe

## INTRODUCTION

Melanoma is a highly malignant neoplasm originating from pigment-containing cells. The most important factors promoting development of this neoplasm include I and II skin types (red or light, blond hair, poor skin pigmentation, freckles and blue eyes) and exposure to ultraviolet radiation [1]. About 20% of all cases of melanoma affect the head and neck, with only a little over 1/3 of them involving mucus membranes [2]. Negative predictive factors include metastases to regional and extra-regional lymph nodes, as well as metastases to other organs [3]. Distant metastases of mucosal melanoma most often involve lungs, liver, peritoneum, less often bones, or the central nervous system [4].

In this publication we present two case reports of mucosal melanoma of the nasal cavity and paranasal sinuses, as well as a review of current literature on the topic.

## CASE REPORT NO. 1

An 82-year-old patient was referred to the Department of Head and Neck Cancer Surgery in Lodz for the diagnostics and treatment of right nasal cavity tumor. She has been reporting impaired patency of the right nasal cavity and recurrent epistaxis for the past 6 months. Surgical biopsy was performed before admission to the Department and histopathological exami-

nation did not confirm a neoplasm. Laryngological examination performed on admission revealed the presence of an ulcerating, bleeding tumor invisible in posterior rhinoscopy. No enlarged lymph nodes were found in the neck region on palpation. Magnetic resonance imaging of the head and neck showed a tumor in the right nasal cavity without infiltration of the bones and sinuses (Fig. 1.). No enlarged lymph nodes of the neck were noted. Laboratory tests were unremarkable. Another biopsy of the right-sided tumor was taken under local anesthesia. Result of histopathological examination of collected tissue sections yielded the following results: infiltration by malignant melanoma cells HMB45+. The patient was referred for surgical treatment.

Right-sided medial maxillectomy was performed through lateral rhinotomy approach. Mucosa of the middle and posterior part of the nasal septum was resected on the right side. Frontal, posterior, ethmoidal air cells, as well as cavernous sinus were opened. The frontal recess was drained. The base of the tumor was located on the mucosa of the middle nasal concha, to little extent crossing onto the mucosa of the lateral wall of the nasal cavity. Macroscopically, there were no signs of neoplastic infiltration of paranasal sinuses. Since no signs of lymphadenopathy were noted in MRI examination and patient's age, we chose not to proceed with elective cervical lymphadenectomy.

Postoperative histopathological examination revealed the following changes: signs of chronic rhinitis and numerous necrotic fragments of the tumor – malignant melanoma (Fig. 2.). The patient was qualified for adjuvant treatment and received radical IMRT in a total dose of 50 Gy.

During subsequent follow-up visits we did not find any signs of tumor relapse neither in clinical examination nor imaging studies (computed tomography of the head, cervical ultrasound). Ten months after surgery an 18-FDG PET-CT examination was performed due to increasingly severe left shoulder pain, which demonstrated presence of metabolically active foci in the hila of both lungs and left humerus. Presence of a highly active bone metastasis was also confirmed in scintigraphy. The patient was referred for palliative treatment and died 2 months after diagnosis of distant metastases.

## CASE REPORT NO. 2

A 74-year-old patient reported to the Department of Head and Neck Cancer Surgery at the Medical University of Lodz due to recurrent and increasingly more severe bleeding from the right nasal cavity and growing sense of nasal obstruction. Nine years earlier the patient had undergone surgery to remove mucosal melanoma of the intranasal septum. Postoperative histopathological examination confirmed that treatment was radical. Following surgical treatment the patient was subject to adjuvant chemotherapy with dacarbasine, which was well tolerated.

Laryngological examination performed on admission to the Department revealed a presence of a pale pink tumor located beneath the middle nasal concha, completely obstructing the ostium of the maxillary sinus. Upon pressing, bright red blood appeared on the surface of the tumor. The patient was referred for tumor biopsy. Histopathological examination revealed the structure of malignant melanoma (spindle cell type). Laboratory tests were unremarkable except for slightly decreased renal clearance (eGFR 58ml/min/1.72 $m^2$). The patient reported being under care of a dermatology clinic due to numerous pigmented skin lesions, which are controlled dermatoscopically on regular basis.

Ordered CT examination showed changes in the upper part of the right nasal canal - scars or granulomatous lesions, mucosal thickening, or presence of polyps in both maxillary sinuses. Lymph nodes were not enlarged (Fig. 3.).

The patient was qualified for surgery. Tumor resection was performed through right-sided rhinotomy and a fragment of intranasal septum and middle nasal concha were removed. It was thought that mucosal membrane of the posterosuperior part of the intranasal septum was the place of origin of the tumor. Surgical procedure was uncomplicated. Histopathological examination of the postoperative material confirmed the presence of malignant melanoma – its spindle cell-type weaving reached the incision line but without infiltration of bone and mucosa. The patient was referred for adjuvant radiotherapy.

## DISCUSSION

Mucosal melanoma is rare and comprises only 1.3% of all cases of malignant melanoma, 55% of them being located in the head and neck region. The incidence of mucosal melanoma remains constant, as opposed to a growing rate of occurrence of skin melanoma [5]. Mean age of patients at diagnosis is 64 years [6]. Exposure to sunlight is considered the main factor influencing growth of the tumor, although in case of paranasal sinus lesions the greatest impact seems to be exerted by chemical agents contained in cigarette smoke and formaldehyde fumes [7,8].

The most frequent locations of mucosal melanoma include nasal cavity and paranasal sinuses (50%) or oral cavity (45%).

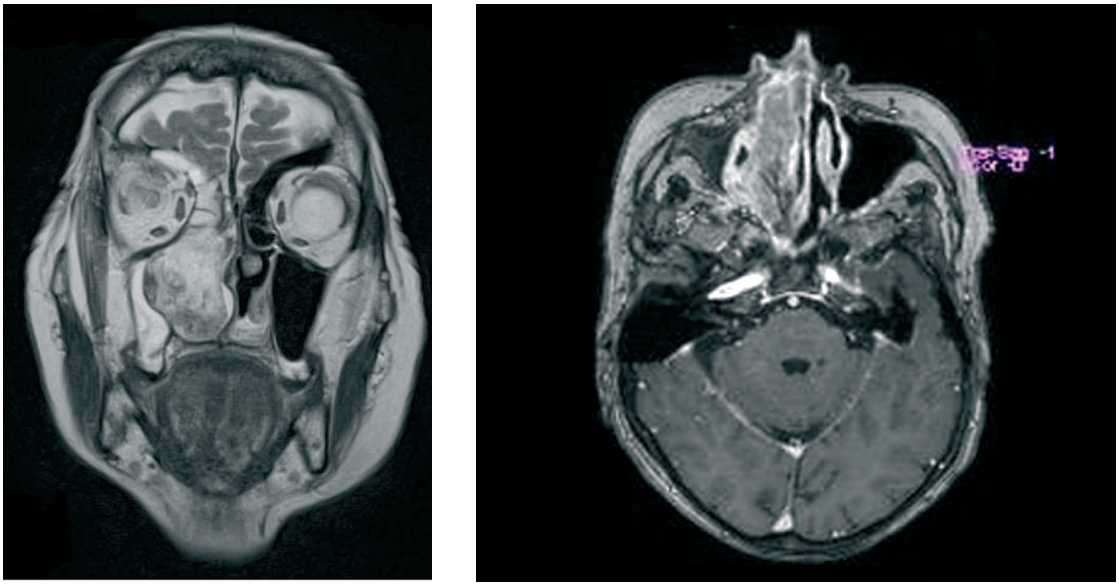

**Fig. 1.** Magnetic resonance images showing a tumor in the right nasal cavity, right maxillary sinus and right ethmoid bone.

Among patients diagnosed with local tumor proliferation, maxillary sinus is the most commonly involved site (75%) [9]. Tumors located in nasal canals and paranasal sinuses are poorly symptomatic, which impacts tumor staging at the time of diagnosis. Epistaxis is the most frequent symptom (62%) followed by unilateral nasal obstruction (33%) [10]. Due to frequent problems in establishing a certain clinical diagnosis, surgical biopsy of the lesion together with histopathological examination must be performed despite contraindications [11]. The most reliable results are obtained with immunohistochemical staining using antibodies against S-100, HMB-45 and Melan-A, which enable stating a precise diagnosis of melanoma [12]. Melanoma of the nasal mucosa is often diagnosed incidentally on histopathological examination among patients who had undergone polypectomy [13]. Therefore, it is important to assess the entire postoperative material histopathologically after such procedures.

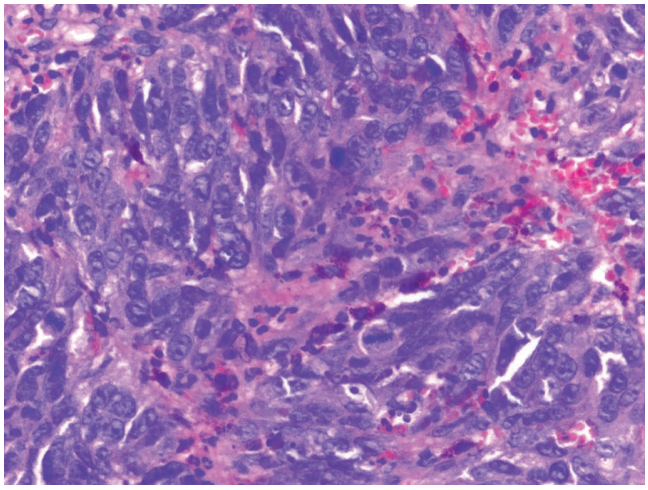

**Fig. 2.** Microscopic image of malignant melanoma of the mcuosa in H+E staining (×200 magnification)

Diversity of the clinical and histopathological picture of head and neck mucosal melanoma does not allow for determining symptoms typical for this tumor alone. Non-characteristic, nonpigmented lesions are often not considered suspicious of malignant melanoma in clinical examination. The covert course of the disease, especially in the region of maxillary sinuses and nose, is the reason for late diagnosis during more advanced phases of the disease (T3-T4). Sometimes, lymph node metastasis is the first sign of paranasal sinus melanoma, which correlates independently with poor prognosis [14]. Lack of association between predictive factors in skin melanoma, such as poor pigmentation and exposure to sunlight, and mucosal melanoma should be emphasized [15].

Radical tumor resection with proper resection margins together with lymphadenectomy or sentinel lymph node biopsy is the main treatment method [16,17]. Adjuvant treatment, such as radio- or chemotherapy is used in order to reduce the risk of local and distant recurrence as well as to improve patient survival. Standard radiotherapy in the postoperative period does not influence general patient survival, but allows for better local

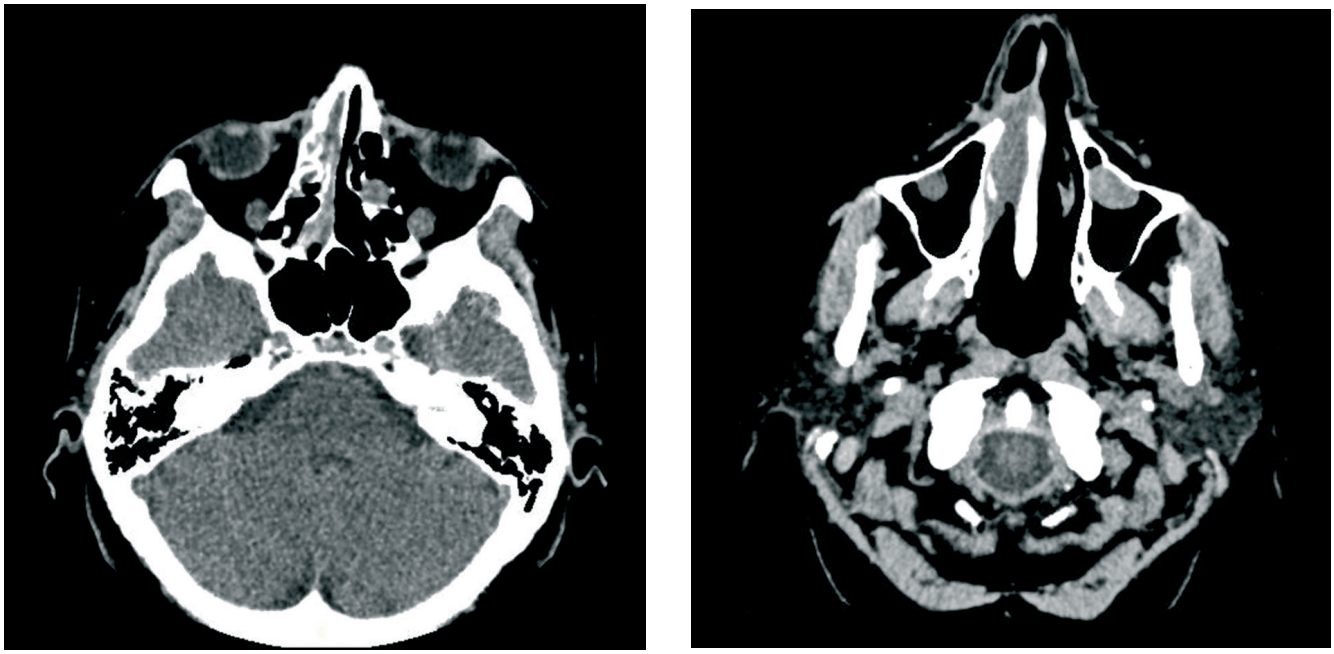

**Fig. 3.** Computed tomography images showing local recurrence within the right nasal canal.

control, which is related to decreased risk of distant recurrence [18,19]. High-dose proton therapy that prevents local recurrence in 62% of patients should be noted [20].

Application of sentinel lymph node biopsy (SLNB) in surgical treatment of skin cancer in the absence of lymph node metastases in imaging studies is currently a broadly accepted method. However, there is still controversy with regard to mucosal melanoma, likely due to the degree of disease advancement at the time of diagnosis and difficult surgical access that limits the possibility of performing SLNB [21,22].

Five-year survival among patients diagnosed with malignant melanoma of the mucus membranes reaches about 25% despite radical surgical treatment and adjuvant therapy [4]. Survival rate among patients treated due to mucosal melanoma is about 24.4 months, increasing to 34.6 months in a group where radical tumor resection was possible [23]. Our reported cases corroborate that despite total resection of a lesion confirmed in histopathological examination and application of postoperative adjuvant treatment (radiotherapy or chemotherapy), local recurrence and distant metastases are frequent.

## SUMMARY

Malignant melanoma of the head and neck mucus membranes is a rare neoplasm characterized by very poor prognosis and is very distinct from skin melanoma.

Occurrence of regional and distant metastases significantly worsens prognosis of patients treated for mucosal melanoma.

Radicality of surgery and application of adjuvant treatment for prevention of local recurrence and distant metastases exert the greatest impact on improvement of prognosis.

The risk of local recurrence and distant metastasis remains high despite total resection and adjuvant treatment.

## References


1. Nikolaou V., Stratigos A.: Emerging trends in the epidemiology of melanoma. The British Journal Of Dermatology. January 2014;170 (1): 11–19.
2. Bruzgielewicz A., Stanisławek-Sut O., Osuch-Wójcikiewicz E., Niemczyk K.: Czerniak złośliwy błon śluzowych jamy nosa i zatok przynosowych – opis przypadku. Otolaryngologia 2006; 5 (4): 195–198.
3. Nazim-Zygadło E., Kochanowicz J.: Czerniak złośliwy jamy nosa i zatok przynosowych. Współ. Onkol. 2001; 5 (3): 95–98.
4. O'Regan K., Breen M., Ramaiya N. et al.: Metastatic mucosal melanoma: imaging patterns of metastasis and recurrence. Cancer Imaging. 2013; 13 (4): 626–632.

5. Chang A.E., Karnell L.H., Menck H.R.: The National Cancer Data Base report on cutaneous and non-cutaneous melanoma: a summary of 84,836 cases from the past decade. Cancer. 1998; 83: 1664–1678.
6. Thompson L.D.R., Wieneke J.A., Miettinen M.: Sinonasal Tract and Nasopharyngeal Melanomas A Clinicopathologic Study of 115 Cases With a Proposed Staging System. The American Journal of Surgical Pathology. 2003; 27 (5): 594–611.
7. Axéll T., Hedin C.A.: Epidemiologic study of excessive oral melanin pigmentation with special reference to the influence of tobacco habits. Scand. J. Dent. Res. 1982; 90: 434–442.
8. Holmstrom M., Lund V.: Malignant melanomas of the nasal cavity after occupational exposure to formaldehyde. British Journal Of Industrial Medicine. 1991; 48 (1): 9–11.
9. Tas F., Keskin S.: Mucosal Melanoma in the Head and Neck Region: Different Clinical Features and Same Outcome to Cutaneous Melanoma. ISRN Dermatology [serial online]. January 2013; 1–5.
10. Xin-Jun M., Hua-Fei A., Wei-Ting H. et al.: Impact of different surgical and postoperative adjuvant treatment modalities on survival of sinonasal malignant melanoma. BMC Cancer 2014; 14: 608
11. Ballester Sánchez R., de Unamuno Bustos B., Navarro Mira M., Botella Estrada R.: Mucosal Melanoma: An Update. Actas Dermosifiliogr. (DNLM) 2015; 106 (2): 96–103.
12. Yuichi O., Masahiro W., Kenji K. et al.: A rare case of amelanotic malignant melanoma in the oral region: Clinical investigation and immunohistochemical study. Oncology Letters. 2015; 10 (6): 3761–3764.
13. Kung B., Deschenes G., Keane W. et al.: Paranasal sinus melanoma masquerading as chronic sinusitis and nasal polyposis. Ear, Nose & Throat Journal. 2007; 86 (9): 561–564.
14. Ettl T., Irga S., Gosau M. et al.: Value of anatomic site, histology and clinicopathological parameters for prediction of lymph node metastasis and overall survival in head and neck melanomas. Journal Of Cranio-Maxillo-Facial Surgery. 2014; 42: 252–258.
15. Kerr E.H., Hameed O., Lewis J.S. et al.: Head and neck mucosal malignant melanoma: clinicopathologic correlation with contemporary review of prognostic indicators. International Journal of Surgical Pathology. 2012; 20 (1): 37–46.
16. Witkowski W.: Miejscowe leczenie chirurgiczne czerniaka. Współ. Onkol. 2003; 7 (8):572–579.
17. Seetharamu N., Ott P.A., Pavlick A.C.: Mucosal Melanomas: A Case-Based Review of the Literature. Oncologist. 2010; 15 (7): 772–781.
18. Owens J., Roberts D., Myers J.: The role of postoperative adjuvant radiation therapy in the treatment of mucosal melanomas of the head and neck region. Archives Of Otolaryngology, Head & Neck Surgery. 2003; 129 (8): 864–868.
19. Bakkal F., Başman A., Aydil U. et al.: Oral and maxillofacial surgery: Mucosal melanoma of the head and neck: recurrence characteristics and survival outcomes. Oral Surgery, Oral Medicine, Oral Pathology And Oral Radiology. 2015; 120: 575–580.
20. Fuji H., Yoshikawa S., Kasami M. et al. High-dose proton beam therapy for sinonasal mucosal malignant melanoma. Radiation Oncology. 2014; 9: 162.
21. Clark R.R., Shoaib T.: Sentinel lymph node biopsy: A new perspective inhead and neck mucosal melanoma? Melanoma Res. 2007; 17: 59.
22. Govers T.M., Hannink G., Merkx M.A.W., Takes R.P., Rovers M.M.: Sentinel node biopsy for squamous cell carcinoma of the oral cavity and oropharynx: A diagnostic meta-analysis. Oral Oncol. 2013 Aug; 49 (8): 726–732.
23. Kim H., Kim E., Lee J. et al.: Noncutaneous malignant melanoma: a prognostic model from a retrospective multicenter study. BMC Cancer. 2010; 10: 167.


Word count: 1620 Tables: – Figures: 3 References: 23

Access the article online: DOI: 10.5604/20845308.1201906 Full-text PDF: www.otorhinolaryngologypl.com/fulltxt.php?ICID=1201906

Corresponding author: Dariusz Kaczmarczyk; Klinika Chirurgii Nowotworów Głowy i Szyi Uniwersytetu Medycznego w Łodzi Kierownik Kliniki: Prof. dr hab. med. Alina Morawiec-Sztandera ul. Paderewskiego 4 93-509 Łódź; e-mail: dariusz.kaczmarczyk@umed.lodz.pl



Competing interests: The authors declare that they have no competing interests.

Cite this article as: Krawczyk P., Kaczmarczyk D.: Malignant melanoma of the nasal cavity mucous membrane – two cases report. Pol Otorhino Rev 2016; 5(3): 33-37