INDEX COPERNICUS INTERNATIONAL

Surgical management of inverted papillomas of the paranasal sinuses

Chirurgia brodawczka odwróconego zatok przynosowych

Tomasz Gotlib

Department of Otorhinolaryngology, Head and Neck Surgery, Medical University of Warsaw, Poland; Head: prof. Kazimierz Niemczyk MD PhD

Article history: Received: 03.11.2020 Accepted: 03.01.2021 Published: 05.01.2021

ABSTRACT: Inverted papilloma is a locally aggressive lesion most commonly originating from the maxillary sinus. Currently transnasal endoscopic excision is a treatment of choice in the majority of cases. The article presents the evolution of endoscopic approaches and possibilities of minimally invasive treatment in regard to tumor location.

KEYWORDS: endoscopic access, inverted papilloma, paranasal sinuses, surgical procedure

STRESZCZENIE: Brodawczak odwrócony jest miejscowo złośliwym nowotworem, najczęściej występującym w zatoce szczękowej. Obecnie jest on leczony głównie z wykorzystaniem technik endoskopowych. W pracy omówiono ewolucję dostępów endoskopowych oraz możliwości postępowania chirurgicznego w zależności od lokalizacji guza.

SŁOWA KLUCZOWE: brodawczak odwrócony, dostępy endoskopowe, postępowanie chirurgiczne, zatoki przynosowe

ABBREVIATIONS

CT – computed tomography
FESS – functional endoscopic sinus surgery
HPV – human papilloma virus
IP – inverted papilloma
MR – magnetic resonance
SCCA – squamous cell carcinoma antigen

Inverted papilloma (IP) is a locally malignant tumor prevalent mainly within the maxillary sinus or the nasal cavity, and less frequently within the remaining paranasal sinuses. The name of the tumor reflects its typical feature – stromal ingrowth (with basal membrane remaining intact).

IP is most prevalent in male patients in the 5th and 6th decade of life [1]. Symptoms of IP include unilateral nasal congestion as well as mucous or purulent discharge, impaired sense of smell, and bleeding. The risk factors include occupational exposure to organic solvents and nickel.

The contribution of HPV to the formation of IP remains unclear despite numerous studies; however, some data indicate that HPV might contribute to tumor recurrence and malignant transformation. Malignant transformation and recurrence are more common in patients with HPV 6, 11, 16, and 18 [2]; malignant transformation is observed in 5–15% of IP cases [1]. Most frequently, IP undergoes transformation into squamous cell carcinoma. In some IP patients, synchronous or metachronous malignancies are observed.

As recently as in the late 20th century, IPs of the paranasal sinuses were usually treated with various external approaches, depending on their location. Since endoscopic surgery was introduced into IP treatment, the proportion of external, combined (endoscopic and external), and endoscopic procedures gradually changed to the favor of the latter. In the course of this evolution, there has been emerging evidence indicating the superiority of endoscopic access as less invasive and associated with a lower percentage of disease recurrence. It is believed that early recurrences of IP are due to incomplete lesion removal. Lower recurrence rates following endoscopic surgery are attributed to better visibility of the lesion.

Identification of the site of tumor's attachment in pre-operative imaging is of critical importance for surgery planning. Until 2008, both external and endoscopic surgeries involved the removal of the entire mucoperiosteum of the affected sinus. This led to prolonged healing, deposition of discharge, and significant scarring, frequently accompanied by neo-osteogenesis. In 2007, K. Yousuf described neo-osteogenetic lesions within the papilloma attachment site as observed in CT scans of paranasal sinuses [3]. One year later, Landsberg proposed an "attachment-oriented endoscopic strategy", i.e. an approach based on intraoperative identification of attachment and selective removal of the attachment along with the tissue margin [4]. The sparing of the remaining mucoperiosteum promotes faster healing without crusting or extensive neo-osteogenesis.

 DOI: 10.5604/01.3001.0014.6345

Most frequently, the tumor has a single attachment ingrown into the bone, resulting in localized bone remodeling which can be detected in CT scans. However, IP attachments may also be diffuse (i.e. broad) or multifocal. This latter type is more likely to occur in patients experiencing a recurrence following previous operations. Removal of bone with tumor ingrowth is crucial to achieve radical resection. Currently, irrigated curve-shaped diamond cutters are most commonly used for this purpose.

In magnetic resonance scans, tumor attachment is marked by tumor plaques converging from the periphery towards the attachment site. The pattern of these plaques is referred to as the "convoluted cerebriform pattern" and is visible in T2- and T1-weighted contrast-enhanced images. The radially spreading plaques follow a convoluted pattern which makes their appearance similar to that of the cerebral cortex [5]. The combined use of sinus CT and MRI offers a greater chance for correct identification of the attachment as compared to each of these methods being used separately [6]. In addition, T2-weighted MRI scans facilitate visualization of a portion of mucus-filled sinus(es), not visible in CT scans without contrast. In some cases, CT scans may reveal calcifications within the tumor which, when located close to the bony wall of the sinus, may resemble neo-osteogenetic lesions typical for tumor attachment. In T2-weighted images, IP is hyperintense in relation to the muscle tissue, as opposed to being iso- or hypointense in T1-weighted images. The tumor is enhanced following administration of a contrast agent.

There are different classifications of inverted papillomas. The most common is the simplest classification as proposed by Krouse and consisting of four grades: I – tumor confined to the nasal cavity; II – tumor confined to the ethmoid and to the upper and medial part of the maxillary sinus; III – involvement of the lateral and lower part of the maxillary sinus or the sphenoid or frontal sinus; IV – pathological lesion extending beyond paranasal sinuses, malignant transformation [7]. Other classification systems (Cannady, Hans, Olkawa, Kamel, Dragonetti) are used less frequently.

IP recurrence has been observed in 0 to 50% of cases in different case series as published in the literature. According to a meta-analysis of available papers reporting on the results of surgical treatment as published in 2006, the total recurrence rate was 15% [1]. However, one should take into account the progress in endoscopic techniques that has been made since that time, which is likely to reduce the recurrence rates. At the same time, publications included in the meta-analysis originated from centers with a high level of experience, and therefore the actual recurrence rates might be higher.

Early recurrence is affected by operator experience. Surgeries to treat recurrent lesions are associated with a higher risk of subsequent recurrence, mainly due to the altered anatomical conditions and the possible development of multifocal tumor attachment. In most series of patients subjected to surgical treatment of IP, no correlation was observed between the IP grade and the frequency of recurrence.

More than one half of recurrence episodes occur within 2 years after the surgery [8]. About 90% of the recurrence episodes occur within 5 years after the surgery [9], while about 6% of recurrences were observed after more than 10 years. Late recurrences are treated rather as „second foci", probably due to HPV infection. It is therefore necessary to perform frequent follow-up checkups (every 3 months) during the first 2 years. Then, the follow-up schedule should include examinations being performed every 6 months for another 2 years, and once a year thereafter. At present, some authors suggest that follow-up examinations be performed in a long-term and possibly even the lifetime scale due to the risk of late recurrences [10]. Postoperative follow-up is based mainly on endoscopic or fiberoscopic examinations and contrast-enhanced MRI scans. Sinus CT scans should be acquired less frequently due to risks associated with X-ray exposures. Imaging studies are particularly useful in cases of suspected submucosal recurrence, preoperative destruction of bone structures, or presence of scar tissue obstructing endoscopic evaluation in hard-to-reach locations.

Bone destruction is the main characteristics of malignant transformation in CT imaging. IP may lead to bone remodeling and thinning without obvious, well-defined, segmental defects. Focal disappearance of the convoluted pattern is a characteristic trait of malignant transformation.

Correct early diagnosis of IP facilitates the scheduled targeted surgery to reduce the risk of recurrence. Unfortunately, in numerous cases, the diagnosis is made following a FESS surgery with the possibility of IP not having being taken into account by the operator despite the unilateral character of lesions and local bone remodeling suggestive of IP being visible in CT scans. For patients with unilateral lesions, the incidence of IP is approximately 10% [11].

Endoscopy-guided biopsy may be useful in the diagnostics of IP in addition to endoscopic, CT and MRI exams. In some cases, the tumor is located so deep that biopsy under local anesthesia is difficult or impossible. As the material is being collected, the tumor should be carefully and delicately probed using a tool (e.g. a suction device) to verify whether it is bleeding upon touch. IP may bleed slightly upon touch, albeit the bleeding should not be extensive. Papilloma may frequently lead to secondary hyperplastic polyps or polyposis [12]. A negative biopsy result does not exclude IP.

Another method reported in literature as useful in the diagnostics and postoperative follow-up of IP is the determination of the squamous cell carcinoma antigen (SCCA) levels. Elevated levels of SCCA were observed in 89% of IP patients [13]. The tumor mass was found to correlate with the SCCA level [14], and the SCCA level decreased following IP resection. The sensitivity and specificity of the exam were established at 80% and 93%, respectively.

In 2006, Piero Nicolai presented three types of endoscopic resections for use in the treatment of inverted papilloma [15].

Type 1 surgery includes frontosphenoethmoidectomy with extended middle nasoantrostomy and middle turbinate resection. According to the authors, this approach should be used for IPs confined to the ethmoid and sphenoid sinus, or bulging into the maxillary sinus without the involvement of the maxillary mucoperiosteum.

Type 2 surgery consists in endoscopic medial maxillectomy. The scope of the resection includes the inferior turbinate, the medial wall of the maxillary sinus, the nasolacrimal duct (depending on tumor location), the uncinate process, ethmoidal cells and the middle turbinate.

Type 3 surgery consists in extended medial maxillectomy covering the range of resection of type 2 surgery with nasolacrimal duct being resected in all cases and the anterior part of the piriform aperture framework being removed as well. This resection is also referred to as endoscopic Denker or Sturman-Canfield surgery. It provides a good overview of the entire maxillary sinus and a better overview of the anterior maxillary sinus wall as compared to type 2 surgery.

Due to the more recent advances in endoscopic techniques, this classification does not reflect all the surgical possibilities available today, such as extended endoscopic approaches to the frontal sinus (Draf IIb, Draf III, extended Draf IIb) or the inferior turbinate-sparing approaches such as the prelacrimal approach or the combined middle and inferior nasoantrostomy approach. In addition, the use of very wide, pre-established resection ranges is assumed for individual types of resections as proposed by Nicolai whereas in most cases a customized, individually-planned access can be used following identification of tumor attachment [4]. In most cases, even if the tumor extends into spaces distant from the attachment, it remains attached to mucoperiosteum alone, and there is no need for aggressive extension of the surgical access.

Instruments useful in the course of endoscopic IP surgeries include angular optics (30, 45, 70 degrees) or a variable-view-angle endoscope, monopolar suction-coagulation device, and irrigated shaver with a curve-shaped cutting tip. If malignant transformation is suspected, intraoperative histopathological examination (frozen sections) is required and all resected material should be submitted for histopathological examination. Resection margin sections are most commonly used.

Different locations of IP lesions offer different possibilities for surgical treatment and determine its difficulty. Listed in order from the simplest to the most difficult to treat, the IP locations include nasal cavity, maxillary sinus and the lower part of the anterior ethmoid, the frontal sinus, and the sphenoid sinus.

This gradation is somewhat simplified since an IP with an attachment within the ostium of the sphenoid sinus may be easier to remove than an IP within the lacrimal recess of the maxillary sinus. The order of these locations is also consistent with the order of IP incidence in individuals. It is also partly consistent with the Krouse classification.

Listed below are the possible endoscopic approaches and procedures to follow for each of these locations.

NASAL CAVITY

Inverted papilloma confined to the nasal cavity is usually attached to the free edge of the uncinate process or to the middle turbinate. This location of the attachment facilitates smooth removal of the lesion with a sufficient resection margin without increased risk of complications. Papillomas attached to lamina papyracea are an exception from this rule. If the attachment cannot be identified by imaging studies, tumor masses loosely adherent to intranasal structures should be removed in a gradual fashion by being shaved (not pulled or torn away) to make the tumor attachment visible. This rule applies to all IP locations.

MAXILLARY SINUS

Prior to the introduction of endoscopic methods, inverted papillomas of the maxillary sinus were removed using the Caldwell-Luc or Denker procedures. According to P. Nicolai, conventional endoscopic accesses to be used for the removal of IPs within the maxillary sinus include the aforementioned type II resection as well as type III resection (endoscopic Denker surgery) [15] (Fig. 1.). These surgeries involve the resection of large areas of mucoperiosteum which, as already mentioned, leads to crusting and neo-osteogenesis; in addition, transection of lacrimal ducts is associated with the risk of scarring and consequent epiphora.

In 2010, Y. Nakamaru presented a modified endoscopic medial maxillectomy approach involving temporary dislocation of the nasolacrimal duct [16]. However, the technique has not gained widespread recognition and applicability, unlike the prelacrimal approach as described by M. Suzuki in 2011 (the name of the surgical access as referred to in the original paper was "modified transnasal endoscopic medial maxillectomy with medial shift of preserved inferior turbinate and nasolacrimal duct") [17]. In subsequent years, publications describing the results of treatment using some very similar techniques were published, and today these techniques are collectively referred to as the "prelacrimal approach". This approach facilitates a very good overview of the maxillary sinus through the prelacrimal recess (the antero-supero-medial part of the maxillary sinus between the anterolateral wall of the nasolacrimal duct and the anterior and medial walls of the maxillary sinus, medially to the suborbital nerve) which is the most inaccessible part of the maxillary sinus in conventional endoscopic approaches. When the maxillary sinus is accessed through the prelacrimal recess, the structures of the lateral wall of the nasal cavity are not removed (unless necessary later in the surgery), and therefore the term "maxillectomy" is not justified when referring to this procedure. Notably, a paper on the use of this approach was published by Polish authors as early as in 2013 [18].

In this access, a vertical incision is made in front of the inferior turbinate attachment. After the posteriorly based flap is created, the bone is cut using a chisel pointed at a slant towards the lateral wall of the nasal cavity starting just in front and below the anterior attachment of the inferior turbinate and continuing towards the area right in front of the anterosuperior attachment of the middle turbinate. Then, lateral wall of the nasal cavity and the inferior turbinate are broken off in medial direction. The piriform aperture is not routinely enlarged. After cutting through the mucoperiosteum of the maxillary sinus, the prelacrimal recess and the remaining parts of the sinus are open for overview. Upon completion of the procedure, the lateral wall of the nasal cavity and

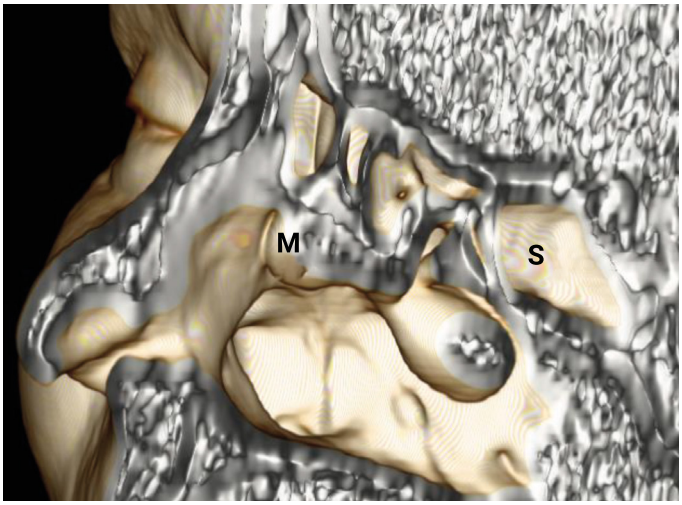

Fig. 1. 3D reconstruction of sinus CT scans acquired in a patient following right-sided endoscopic maxillectomy: M – middle turbinate, S – sphenoid sinus. A wide entrance to the maxillary sinus can be seen below the middle turbinate.

the inferior turbinate are moved back to the original position and, most frequently, stabilized using an absorbable suture.

A disadvantage of the prelacrimal approach consists in the limited availability of endoscopic follow-up examinations following the surgery. Follow-up exams can be performed either via middle nasoantrostomy (if performed, as it does not constitute a part of the standard scope of the surgery), or following a wide inferior nasoantrostomy being performed. In addition, the surgery may be technically difficult in cases of nasolacrimal duct running in the vicinity of the maxillary sinus wall, requiring an enlargement of the piriform aperture [19]. The enlargement of the piriform aperture as carried out in some variants of prelacrimal access surgeries may result in facial deformation. B. Zhou observed this complication in 4% of patients [20].

Another sparing technique was proposed by Pagella (2017) [21]. The procedure consists in medial maxillectomy with the anterior part of the nasal turbinate being spared (Tu-Na saving) and inferior nasoantrostomy being extended to the piriform aperture.

The authors classified endoscopic approaches into the maxillary sinus as practiced in surgical management of IP into four types (A–D):

- Type A – 'simple' maxillectomy with the anterior part of the inferior turbinate being spared, indicated in cases of tumors attached to the posterior or lateral maxillary sinus wall;
- Type B – the aforementioned "Tu-Na saving" maxillectomy used in cases of tumors attached to the anterior sinus wall;
- Type C – endoscopic medial maxillectomy with lacrimal duct transection and resection of the entire inferior turbinate with the removal of tumor attachment alone rather than of the entire sinus mucoperiosteum – used in cases when no sufficient control of the anterior wall of the maxillary sinus can be achieved;
- Type D – similar to type C but involving maximum resection of the mucoperiosteum. This type is applied in cases of diffuse or poorly identified attachments, particularly in recurrent disease.

The above classification does not account for the aforementioned prelacrimal access or the combined middle and inferior nasoantrostomy approach as discussed below. No results of postoperative observations were presented by the authors with regard to the possibilities of endoscopic follow-up examinations being performed within the anterior part of the sinus after the inferior turbinate stump had been spared as part of the Tu-Na saving approach.

In 2020, a series of cases were reported regarding patients with inverted papilloma within the maxillary sinus operated on using the combined middle and inferior nasoantrostomy approach [22]. This approach facilitates a good overview and the possibility of removing the tumor from nearly the entire maxillary sinus with the exception of some cases involving the prelacrimal recess. The main advantages of this approach consist in the inferior turbinate being spared in its entirety with lacrimal ducts also being spared and postoperative follow-up being facilitated via both nasoantrostomies (as opposed to prelacrimal access). In this approach, inferior nasoantrostomy can be extended depending on the need to visualize the anterior maxillary sinus wall. It can be extended all the way to the piriform aperture. In the broadest version of this access, nearly the entire lateral wall of the nasal cavity is removed, and both nasoantrostomies are connected (from the piriform aperture below the Hasner's valve to the posterior wall of the maxillary sinus). The lower turbinate remains suspended on its anterior and posterior attachments (the lateral attachment being removed) yet retains stable position (Fig. 2.).

When the prelacrimal recess is also affected, the approach may be extended to prelacrimal approach.

It seems that the most appropriate management of IP within the maxillary sinus consists in choosing an appropriate approach depending on the anatomy of the nasolacrimal duct and the visibility of papilloma attachment in CT and MRI scans.

When the attachment is located outside the anterior/upper wall (outside the prelacrimal recess region), the most suitable access is through middle and inferior nasoantrostomy. The same approach may be used when the attachment is located within the prelacrimal recess albeit only when the anteroposterior or transverse dimension of the recess exceeds 3 mm and the anterior attachment of the interior turbinate is in a high position.

If the visible attachment is located on the anterior and/or upper wall of the maxillary sinus in a patient with narrow prelacrimal recess, prelacrimal access with possible transposition of the nasolacrimal duct is the approach of choice.

If the attachment is not visible, broad middle nasoantrostomy followed by inferior nasoantrostomy is warranted regardless of the anatomy of the prelacrimal recess. If the tumor occupies the upper part of the anterior wall, the procedure is extended to include prelacrimal access. Medial maxillectomy should be considered as the last resort, for example in cases of diffuse or multifocal attachments in subsequent recurrences.

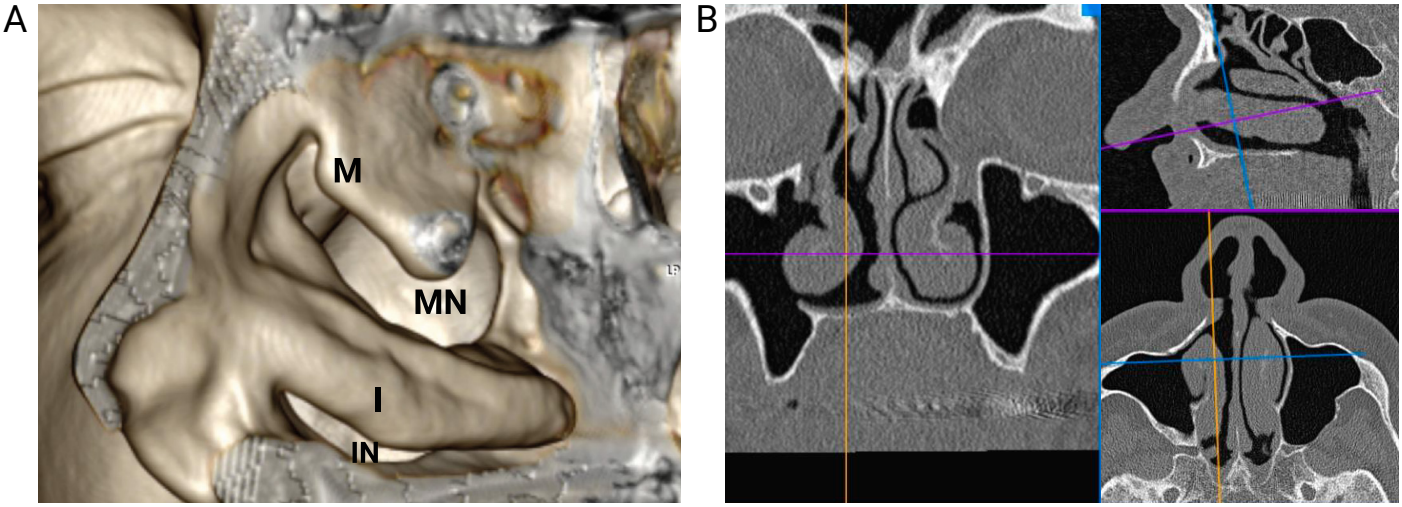

Fig. 2. (A) 3D reconstruction of sinus CT scans acquired in a patient having undergone surgery using right-sided access via middle and inferior nasoantrostomy. Both nasoantrostomies facilitating endoscopic follow-up can be seen. M – middle turbinate, MN – middle nasoantrostomy, I – inferior turbinate, IN – inferior nasoantrostomy, (B) Triplanar reconstruction following the surgery accessed via extended middle and inferior nasoantrostomy.

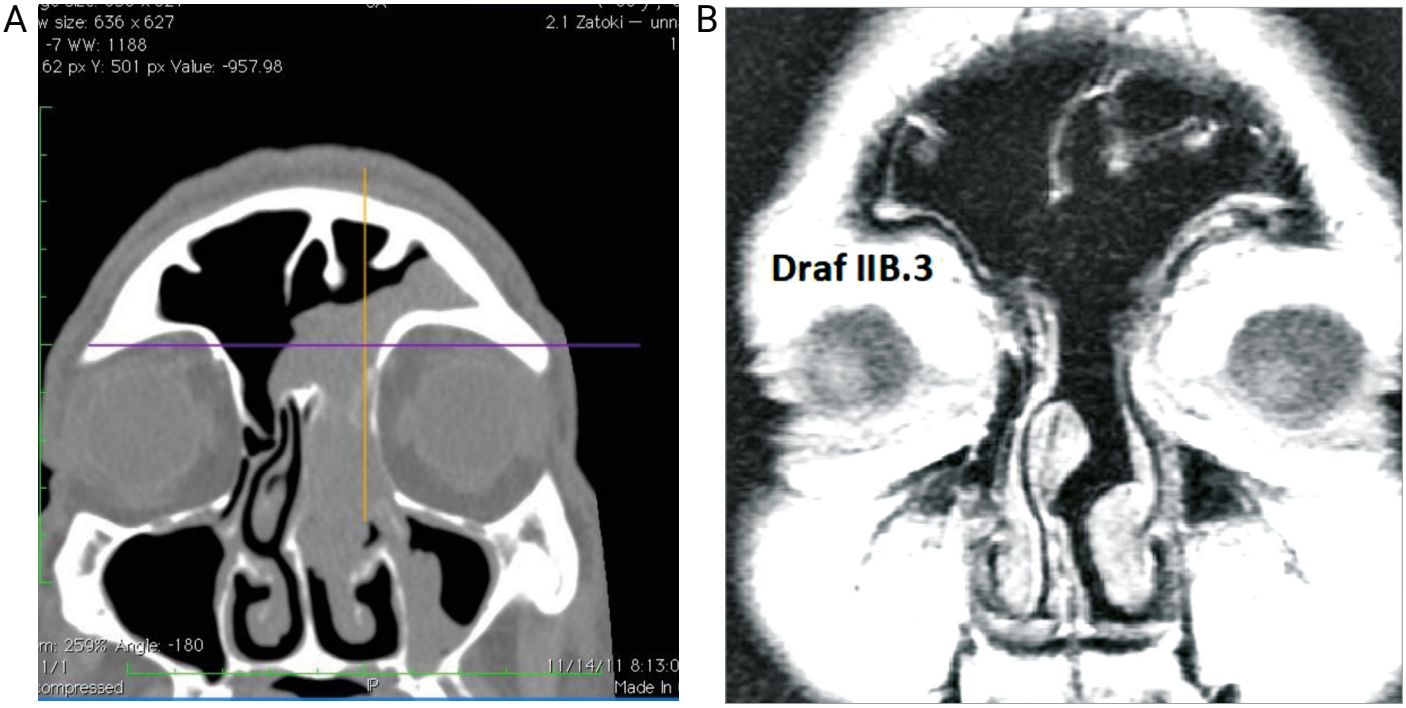

Fig. 3. (A, B) Preoperative CT and post-operative MRI scans after a Draf 2b.3 procedure (Draf 2b access extended to include the removal of the upper part of the nasal septum and the lower part of the intersinus septum) in a patient with inverted papilloma of the left frontal sinus.

FRONTAL SINUS

In most cases presenting with frontal sinus involvement, IP bulges into the frontal recess or even into the frontal sinus. Attachments within the frontal sinus are much less common. An attachment of the papilloma within the frontal sinus is often visualized in a CT scan as a part of significantly thickened yet decalcified sinus border (e.g. the intersinus septum or the frontoethmoidal cell). These lesions are usually more extensive which may result from a longer time of growth before the onset of the first symptoms (as compared to IPs confined to nasal cavity which lead to earlier symptoms). Bilateral involvement of frontal sinuses is observed in 15% of patients [23]. If the attachment is identified close to the medial line, not further that 1 cm laterally from the perisagittal plane transecting the lamina papyracea, IP may be removed using the Draf IIb/extended Draf IIb procedures (Fig. 3.) or the Draf III procedure [24, 25]. In cases of tumors with lateral penetration with large area of the attachment to the sinus floor, or bulging from above into the orbit, endoscopic surgery may be insufficient. Lesions which occupy the sinus floor medially to midpupillary line can be removed using orbital transposition. This technique can also be helpful when removing IPs from the supraorbital recess of the frontal sinus. It consists of coagulation and transection of the anterior ethmoid artery followed by the removal of the upper

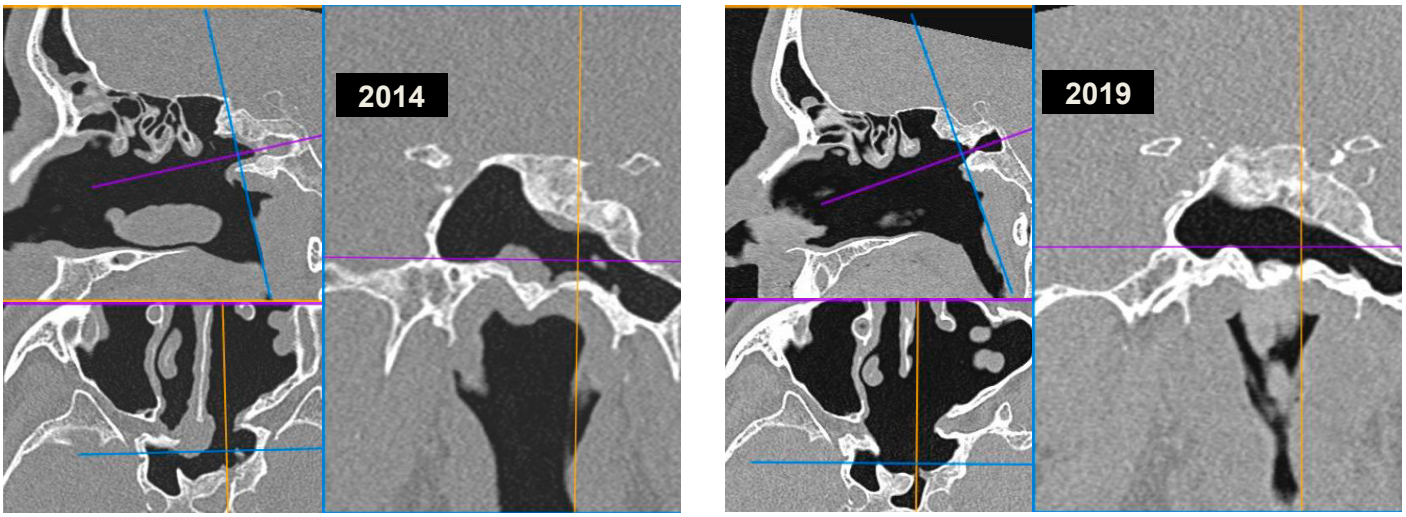

Fig. 4. (A) A patient with a recurrent inverted papilloma of the sphenoid sinus within the posterior part of nasal septum, mucocele and intense neo-osteogenesis following aggressive removal of sphenoid sinus lining; (B) Postoperative condition.

part of the lamina papyracea (with no damage being made to the periosteum) and the lateral and anteroinferior translocation of the orbital contents so as to provide a better view into the lateral part of the frontal sinus.

IP filling the lateral part of the frontal sinus requires external (osteoplastic flap) or combined (endoscopic + external) access. The combined access allows for reducing the scope of the external access and prevents ostial congestion. The enlarged ostium may be used for follow-up examinations of the sinus. In the case of lesions in lateral locations, the exams may be carried out using a fiberoscope. In the broadest variant, the combined approach includes osteoplastic flap and Draf 3 procedure.

It is important to ensure a wide sinus ostium. When large areas of mucoperiosteum are resected, the exposed bone may be covered by mucosal transplant. Obliteration of the frontal sinus should be considered as the last resort since it prevents endoscopic follow--up. Potential recurrence within an obliterated sinus is difficult to detect owing to bone remodeling following the resection of mucoperiosteum and the lack of well-defined boundary between the recurrent lesion and the neighboring tissue used for obliteration.

It is difficult to predict the extent of the attachment from preoperative imaging studies, and thus the patients should be informed of the possibility of an endoscopic procedure being converted to open surgery.

SPHENOID SINUS

Due to the vicinity of the internal carotid artery and the optic nerve, IPs within the sphenoid sinus pose the greatest challenge to surgeons. The main problem related to this location is associated with drilling down the attachment within the bony framework of the aforementioned structures. Although the attachment should be drill down, exposure of the dura, optic nerve, or carotid artery may present with risks not only in the course of the procedure itself, but also in case of future recurrence. Typically, IPs don't transgress natural barriers such as bone, dura, or orbital periosteum. Bone removal might promote future expansion of tumor into the exposed structures should the disease recur. It is recommended to ensure the maximum width of the sinus ostium. If the tumor is located within a hypoplastic sinus or if the intersinus septum is slanted so that the access to the posterior part of the sinus is restricted, the removal of the intersinus septum greatly improves the overview of the sinus and the ability to perform maneuvers using endoscopic tools. An even broader access can be achieved by removing the posterior part of the septum adjacent to the sphenoid rostrum, i.e. a part of the bottom sinus wall. The ability to maneuver using endoscopic tools is limited due to the small size of the sinus (as compared to the maxillary or ethmoid sinuses). This makes it much more difficult to selectively remove the lining while sparing the healthy mucoperiosteum within the remaining part of the sinus. Usually, a significant part of the lining is affected by the disease. Therefore, much more frequently than in other sites, nearly the entire mucoperiosteum is removed from the sphenoid sinus leading to increased neo-osteogenesis in the healing process.

In such cases, the sparing of the intersinus septum results in concentric stenosis responsible for difficulties with postoperative follow-up.

Massive bone remodeling, in some cases involving the formation of mucoceles, makes it difficult to identify a possible recurrence and requires repeated contrast-enhanced imaging studies (Fig. 4.).

A particular challenge is posed by IPs located within the lateral recess of the sphenoid sinus; they may be removed using the transpterygoid approach.

This approach involves coagulation of the sphenopalatine artery, removal of the anterior wall of the pterygopalatine fossa (the medial fragment of the posterior wall of the maxillary sinus) followed by lateral transposition of contents of the pterygopalatine fossa and the removal of its posterior wall

(i.e. the anterior wall of the lateral recess of the sphenoid sinus). This improves the visibility of the lateral part of the recess. To improve the viewing angle and the ability to maneuver using the endoscopic tools, contralateral transseptal approach may be used. The use of 45- or 70-degree optics improves the visibility, but does not alter the limited maneuverability of the tools.

After the IP surgery, patients should be informed about the nature of the disease, the possibility of early and late recurrences, and the consequent need to undergo regular postoperative follow-up checkups. Despite the development in endoscopic techniques, external approaches still have to be used in certain cases (particularly those of IPs located within the frontal sinus).

References

1. Busquets J.M., Hwang P.H.: Endoscopic resection of sinonasal inverted papilloma: a meta-analysis. Otolaryngol Head Neck Surg., 2006; 134(3): 476–482.
2. Budu V., Schnaider A., Bulescu I.: Endoscopic approach of sinonasal inverted papilloma – our 15 years' experience on 162 cases. Rom J Rhinol, 2015; 5(17): 31–36. https://doi.org/10.1515/rjr-2015-0004
3. Yousuf K., Wright E.D.: Site of Attachment of Inverted Papilloma Predicted by CT Findings of Osteitis. Am J Rhinol, 2007; 21(1): 32–36. doi:10.2500/ajr.2007.21.2984
4. Landsberg R., Cavel O., Segev Y., Khafif A., Fliss D.M.: Attachment-oriented endoscopic surgical strategy for sinonasal inverted papilloma. Am J Rhinol., 2008; 22(6): 629–634. doi: 10.2500/ajr.2008.22.3243. PMID: 19178804.
5. Barnes L., Verbin R.S., Gnepp D.R.: Diseases of the nose, paranasal sinuses, and nasopharynx. In: Barnes L, ed. Surgical Pathology of the Head and Neck., 1985; 1: 403–451.
6. Fang G., Lou H., Yu W. et al.: Prediction of the originating site of sinonasal inverted papilloma by preoperative magnetic resonance imaging and computed tomography. Int Forum Allergy Rhinol, 2016; 6(12): 1221-12-28.
7. Krouse J.H.: Development of a staging system for inverted papilloma. Laryngoscope, 2000; 110(6): 965–968.
8. Sham C.L., Woo J.K.S., Van Hasselt C.A., Tong M.C.F.: Treatment Results of Sinonasal Inverted Papilloma: An 18-Year Study. Am J Rhinol Allergy, 2009; 23(2): 203–211. doi:10.2500/ajra.2009.23.3296
9. Petit P., Vivarrat-Perrin L., Champsaur P. et al.: Radiological follow-up of inverted papilloma. Eur Radiol, 2000; 10: 1184–1189.
10. Bugter O., Monserez D.A., Van Zijl F.V.W.J., Baatenburg De Jong R.J., Hardillo J.A.: Surgical management of inverted papilloma; a single-center analysis of 247 patients with long follow-up. J Otolaryngol Head Neck Surg, 2017; 46(1): 1–13. https://doi.org/10.1186/s40463-017-0246-7
11. Mielcarek-Kuchta D., Simon K., Kondratowicz D., Łukomska Z., Rybak-Korytowska A.: Functional endoscopic sinus surgery (FESS) in unilateral sinus disease. Otolaryngol Pol., 2017; 71(5): 29–35. doi: 10.5604/01.3001.0010.5314. PMID: 29154250.
12. Díaz Molina J.P., Llorente Pendas J.L., Tapia J.P.R. et al: Inverted sinonasal papillomas. Review of 61 cases. Acta Otorrinolaringológica Española, 2009; 60(6): 402–408.
13. Yasumatsu R., Nakashima T., Masuda M.: Clinical value of serum squamous cell carcinoma antigen in the management of sinonasal inverted papilloma. Head Neck, 2005; 1: 44–48.
14. Matoušek P., Zeleník K., Šafarčík K. et al.: Squamous cell carcinoma antigen as a marker of sinonasal inverted papilloma. Eur Arch Otorhinolaryngol, 2014; 271: 535–538. https://doi.org/10.1007/s00405-013-2604-z
15. Nicolai P., Tomenzoli D., Lombardi D., Maroldi R.: Different endoscopic options in the treatment of inverted papilloma. Oper Tech Otolaryngol, 2006; 17: 80–86.
16. Nakamaru Y., Furuta Y, Takagi D. et al.: Preservation of the nasolacrimal duct during endoscopic medial maxillectomy for sinonasal inverted papilloma. Rhinology, 2010; 48(4): 452–456.
17. Suzuki M., Nakamura Y., Nakayama M. et al.: Modified transnasal endoscopic medial maxilectomy with medial shift of preserved inferior turbinate and nasolacrimal duct. Laryngoscope, 2011; 121(11): 2399–2401.
18. Sieśkiewicz A., Piszczatowski B., Olszewska E. et al.: Minimally invasive transnasal medial maxillectomy for treatment of maxillary sinus and orbital pathologies. Acta Otolaryngol, 2014; 134(3): 290–295.
19. Sieśkiewicz A., Buczko K., Janica J. et al.: Minimally invasive medial maxillectomy and the position of nasolacrimal duct: the CT study. Eur Arch Otolaryngol, 2016; 274(3): 1515–1519.
20. Zhou B., Huang Q., Sun J. et al.: Resection of inverted papilloma of the maxillary sinus via a prelacrimal recess approach: A multicenter retrospective analysis of surgical efficacy. Am J Rhinol Allergy, 2018; 32(6): 518–525. doi: 10.1177/1945892418801243
21. Pagella F., Pusateri A., Matti E. et al.: „TuNa-saving" endoscopic medial maxillectomy: a surgical technique for maxillary inverted papilloma. Eur Arch Otorhinolaryngol., 2017; 274(7): 2785–2791. doi: 10.1007/s00405-017-4549-0. Epub 2017 Apr 3. PMID: 28374054.
22. Gotlib T., Kuźmińska M., Kołodziejczyk P., Niemczyk K.: Endoscopic combined middle and inferior meatal antrostomies approach in treatment of maxillary sinus inverting papilloma. Videosurgery and Other Miniinvasive Techniques, 2020; 15(4): 645–652. doi: 10.5114/wiitm.2020.92309
23. Walgama E., Ahn C., Batra P.S.: Surgical management of frontal sinus inverted papilloma: a systematic review. Laryngoscope, 2012; 122(6): 1205–1209.
24. Gotlib T., Held-Ziółkowska M., Niemczyk K.: Extended Draf IIb procedures in the treatment of frontal sinus pathology. Clin Exp Otorhinolar, 2015; 8(1): 34–38.
25. Gotlib T., Krzeski A., Held-Ziółkowska M., Niemczyk K.: Endoscopic transnasal management of inverted papilloma involving frontal sinuses. 2012. Wideochir i inne Techniki Małoinwazyjne, 2012; 23(3): 588–590.

Word count: 4389 Tables: – Figures: 4 References: 25

Access the article online: DOI: 10.5604/01.3001.0014.6345 Table of content: https://otorhinolaryngologypl.com/issue/13438

Some right reserved: Polish Society of Otorhinolaryngologists Head and Neck Surgeons. Published by Index Copernicus Sp. z o.o.

Competing interests: The authors declare that they have no competing interests.

The content of the journal „Polish Society of Otorhinolaryngologists Head and Neck Surgeons" is circulated on the basis of the Open Access which means free and limitlessaccess toscientific data.

This material is available under the Creative Commons – Attribution-NonCommercial 4.0 International (CC BY-NC 4.0). The full terms of this license are available on: https://creativecommons.org/licenses/by-nc/4.0/legalcode

Corresponding author: Tomasz Gotlib MD PhD; Department of Otorhinolaryngology, Head and Neck Surgery, Medical University of Warsaw; Banacha street 1a, 02-097 Warsaw, Poland; Phone: +48 22 599 25 21; E-mail: tgotlib@wum.edu.pl

Cite this article as: Gotlib T.: Surgical management of inverted papilloma of the paranasal sinuses; Pol Otorhino Rev 2020; 9 (4): 60-66