

Endoscopic resection of sinonasal adenoid cystic carcinoma with radiofrequency coblation. A clinical report with literature review

Endoskopowa resekcja raka gruczołowo-torbielowatego jamy nosa i zatok przynosowych z zastosowaniem koblacji prądem o częstotliwości radiowej – opis przypadku i przegląd piśmiennictwa

Pedro Clarós¹, Agnieszka Waląg^{2,3}, Andrés Clarós¹

¹Clínica Clarós, Barcelona, Spain

²Scholarship at Clínica Clarós, Barcelona, Spain

³Department of Otolaryngology, Rydygier Memorial Hospital, Cracow, Poland

Article history: Received: 06.11.2019 Accepted: 22.02.2020 Published: 25.02.2020

ABSTRACT:

Introduction: Sinonasal cancer is very rare and accounts for under 1% of all malignancies of which sinonasal adenoid cystic carcinoma (SNACC) is about 5%. The maxillary sinus is the most common site of SNACC. Misleading symptomatology which overlaps with rhinosinusitis contributes to the delay of diagnosis. Recently, the endoscopic approach is commonly applied with equal or better results to the open approach. Radiofrequency coblation might be used to reduce blood loss.

Material and Methods: We present a case of an adenoid cystic carcinoma arising from the left inferior turbinate. The patient received endoscopic surgical treatment with the application of radiofrequency coblation in Clarós Clinic at the beginning of 2019 and remains followed up with no sign of recurrence. Afterward, we review the literature on the subject.

Conclusion: SNACC is a rare malignancy, characterized by slow growth and perineural infiltration with spreading towards the skull base, cavernous sinus, and orbit. The regional nodal involvement is rare. Frequent and delayed distant metastases in lung, bone, liver, and brain are also typical. Prognosis is poor with the 5-year overall survival between 41% and 86%. Surgery with or without complementary radiotherapy provides the best outcomes for the majority of patients. The significance of prognostic factors remains unclear. Lifelong surveillance is obligatory as very late recurrences are common.

KEYWORDS:

adenoid cystic carcinoma, endoscopic surgery, paranasal sinus neoplasm, radiofrequency coblation, sinonasal adenoid cystic carcinoma, sinonasal cancer, SNACC

STRESZCZENIE:

Wstęp: Rak jamy nosa i zatok przynosowych jest rzadką chorobą stanowiącą do 1% wszystkich nowotworów złośliwych. Rak gruczołowo-torbielowaty jamy nosa i zatok przynosowych (SNACC) stanowi około 5% nowotworów tej lokalizacji. Najczęstszym jego umiejscowieniem jest zatoka szczękowa. Objawy kliniczne nowotworu mogą być błędnie przypisywane zapaleniu błony śluzowej nosa i zatok przynosowych, co prowadzi do opóźnienia rozpoznania. W ostatnich latach coraz szerzej stosuje się zabiegi endoskopowe, których skuteczność w porównaniu z otwartą operacją jest podobna lub większa. Zastosowanie koblacji prądem o częstotliwości radiowej może być pomocne w zmniejszeniu krwawienia w czasie zabiegu.

Materiał i metody: Prezentujemy przypadek pacjentki z rakiem gruczołowo-torbielowatym wywodzącym się z lewej małżowiny nosowej dolnej. Na początku 2019 roku w Klinice Clarós pacjentka przeszła endoskopowy zabieg usunięcia zmiany, w czasie którego zastosowano koblację prądem o częstotliwości radiowej. Kobieta pozostaje pod obserwacją i nie prezentuje objawów wznowy. W dalszej części dokonujemy przeglądu piśmiennictwa na ten temat.

Wniosek: SNACC jest rzadkim nowotworem złośliwym, który cechuje się powolnym wzrostem i naciekiem przestrzeni okołonerwowych, szerzącym się w kierunku podstawy czaszki, zatoki jamistej i oczodołu. Rzadko dochodzi do zajęcia regionalnych węzłów chłonnych. Z czasem często pojawiają się przerzuty odległe do płuc, kości, wątroby i mózgu. Rokowanie

w SNACC jest złe, z 5-letnim przeżyciem wynoszącym 41–86%. Najlepsze wyniki leczenia uzyskuje się u chorych poddanych zabiegowi operacyjnemu z ewentualną uzupełniającą radioterapią. Znaczenie czynników prognostycznych pozostaje niejasne. Z powodu częstego występowania późnych nawrotów obowiązuje dożywnie monitorowanie pacjentów.

SŁOWA KLUCZOWE: chirurgia endoskopowa, koblacja prądem o częstotliwości radiowej, nowotwór zatok przynosowych, rak gruczołowo-torbielowy jamy nosa i zatok przynosowych, rak gruczołowo-torbielowy, rak jamy nosa i zatok przynosowych, SNACC

ABBREVIATION

MRI – magnetic resonance imaging

SNACC – sinonasal adenoid cystic carcinoma

INTRODUCTION

Sinonasal cancer is an uncommon entity which accounts for under 1% of all malignancies. The incidence is approximately one in 100,000 per year [1] with squamous cell carcinoma being the most common type accounting for about 65–70% [2]. Adenoid cystic carcinoma is a very rare malignancy in this region (about 5% of sinonasal cancers [Volpi L.]). Most often, it arises from the major and minor salivary glands without sex predilection. The maxillary sinus (49.7%) is the most common site of sinonasal adenoid cystic carcinoma (SNACC). Misleading symptomatology which overlaps with rhinosinusitis contributes to the delay of diagnosis. Prognosis is poor with the 5-year overall survival between 41% and 86% [1–10]. Surgery with or without complementary radiotherapy provides the best outcomes for the majority of patients [1, 3–5, 7, 9, 10]. Recently, the endoscopic approach is increasingly applied with equal or better results to the open approach [1, 4, 5]. Radiofrequency coblation might be used to reduce blood loss [11]. Late recurrences are frequent therefore life-long surveillance is required [12].

MATERIAL AND METHODS

We present a case of an adenoid cystic carcinoma arising from the left inferior turbinate. The patient received endoscopic surgical treatment with the application of radiofrequency coblation in Clarós Clinic at the beginning of 2019 and remains under observation with no signs of recurrence. The patient must be closely followed up for a lifetime due to a high risk of recurrence. Afterward, we review the literature on the subject.

CASE REPORT

A 61-year-old female born in Columbia, residing in the Balearic Islands (Spain) for the last 20 years, presented at our clinic with a history of progressive unilateral nasal obstruction and recurrent, self-limiting epistaxis lasting two years. The last nasal bleeding occurred 6 months before the initial consultation. The patient denied weight loss, fevers, or other symptoms. She was not suffering from any chronic illness and was not a smoker – neither currently nor in the past.

During an endoscopic examination a pedunculated tumor arising from the left inferior turbinate with well-defined margins was

visualized (Fig. 1.). Palpation of the neck showed no lymph nodes enlargement. Otherwise, the patient's general condition was good.

We performed computed tomography which visualized a polypoid lesion arising from the posterior portion of the left inferior turbinate expanding towards the left choana with slight contrast enhancement (Fig. 2A., 2B., 2C.).

The laboratory tests including complete blood count, clotting parameters, inflammatory markers were within the reference ranges. Based on the clinical data and imaging diagnostics the patient was qualified for surgical excision. Considering the need to remove the tumor regardless of pathology and the risk of bleeding we decided not to take a biopsy at the out-patient clinic but schedule an immediate surgery under general anesthesia.

Surgery technique

Endoscopic endonasal resection of the tumor was performed under general anesthesia. The inferior turbinate was infiltrated with Lignocaine 1% and 1:10000 adrenaline solution. Topical anesthesia with adrenaline 1:1000 and 10% Lignocaine was also applied. The scope of the operation included complete tumor removal within macroscopically unchanged margins together with the reduction of the inferior turbinate. We used radiofrequency coblation (Coblation®, Evac 70 Xtra, ArthroCare Corp) commonly applied during tonsil removal to decrease blood loss during the procedure. The tumor was resected in one piece (Fig. 3.), additional samples were taken from the margin for further pathological evaluation. Later the turbinate margin was enlarged with radiofrequency coblation. No nasal packing was required due to good hemostasis.

Postoperative management

The patient was released from the hospital the next day and put on 7-day ciprofloxacin and 4 weeks of nasal flushes. The first endoscopic debridement was performed two weeks after the operation.

The histopathological examination showed an anti-MYB positive adenoid cystic carcinoma without perineural invasion (Fig. 4.). The samples taken from the margin were free of disease. Healed mucosa was visualized during the endonasal examination. The magnetic resonance imaging (MRI) of the head and neck and the whole-body PET/CT scan were clear of disease. (Fig. 5A., 5B.)

Due to a low stage at presentation (T2N0M0) we decided on a close follow-up every three months including endoscopic examination and MRI.

DISCUSSION

Sinonasal adenoid cystic carcinoma is an infrequent malignancy accounting for 5% of sinonasal cancers [4]. It originates from the mucus-secreting glands of the upper aerodigestive tract. The maxillary sinus is the most common site of SnACC (49.7%), followed by the nasal cavity (32.4%), ethmoid sinus (5.8%) and sphenoid sinus (4.8%) [3]. Single cases in the frontal sinus have also been described [3, 13].

There is no sex predilection, it occurs in all age groups with the mean incidence in the second half of the fifth decade [3, 4, 12]. It is characterized by slow growth and perineural infiltration with spreading towards the skull base, cavernous sinus, and orbit. Contrary to sinonasal squamous cell carcinoma regional nodal involvement is rare [4, 14]. Frequent and delayed distant metastases are also typical [1, 4]. The most common sites are lung, bone, liver, and brain [4].

The most frequent presentation includes the nasal obstruction and recurrent epistaxis, sometimes pain, facial symptoms including paralysis, sensory changes, and swelling or loss of smell [4]. Misleading symptomatology which overlaps with rhinosinusitis contributes to the delay of diagnosis. In the research presented by Trope et al. nearly half of the patients presented with stage IV of the disease (49.1%) [3].

Most authors agree that surgery with or without complementary radiotherapy provides the best outcomes for the majority of patients [1, 3–5, 7, 9, 10]. Surgery alone is accepted in patients with early-stage tumors [5].

With the development of endoscopic sinus surgery in the treatment of chronic rhinosinusitis, it is not surprising that this approach is now becoming commonly used by ENT specialists in the field of oncology. It enables good visualization of endonasal tumors while avoiding facial incision and osteotomy. After analyzing the group of 34 patients treated endoscopically for SNACC Volpi et al. concluded that it is safe, effective and reduces the comorbidities when compared to the external approaches [4]. Most researchers agree that oncological results are similar for the endoscopic and the open approach [4, 10]. Some, however, presented an advantage of endoscopy. In the study by Mays et al. patients treated with endoscopic surgery alone had improved OS when compared to those treated with open surgery or endoscopy-assisted surgery [5].

Proper hemostasis is crucial to enable effective endoscopic surgery. A number of methods of bleeding reduction are known, such as controlled hypotension, reverse Trendelenburg position, local vasoconstrictors, and cautery. Radiofrequency coblation was also proven to significantly decrease blood loss during endoscopic sinonasal and skull base tumor removal [11]. The mechanism is based on cutting tissues at low temperature (40–70°C) and coagulating the surroundings at the same time [11]. In our patient, we were able to maintain minimal blood with good visualization and remove the tumor in one piece within a macroscopically unchanged margin with this device.

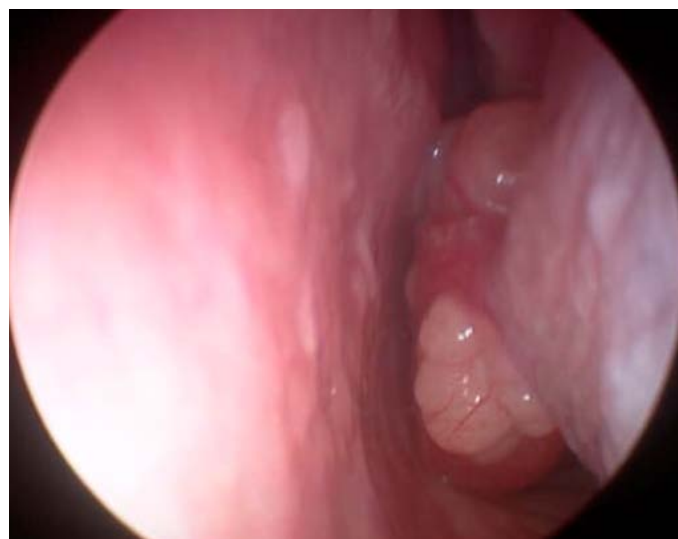

Fig. 1. An endoscopic examination showing a pedunculated tumor with well-defined margins arising from the posterior portion of the left inferior turbinate.

Tab. I. 5-year overall survival.

STUDY (YEAR, NO OF PATIENTS)	5-YEAR OS
Trope et al. (2019, 793) [3]	61%
Volpi et al. (2019, 34) [4]	86.5%
Mays et al. (2018, 160) [5]	67%
Miller et al. (2017, 23) [6]	62%
Unsal et al. (2017, 694) [7]	66.5%
Sanghvi et al. (2013, 412) [8]	68.8%
Michel J. et al. (2013, 11) [9]	41%
Michel G. et al. (2013, 25) [10]	63%
Rhee et al. (2006, 35) [1]	86%

According to the literature, the prognosis in SNACC patients is poor with the 5-year overall survival between 41% and 86% [1–10] (Tab. I.). Treatment failure is more often related to the late recurrence than distant metastases [4].

The significance of prognostic factors has been widely studied and remains unclear.

Trope et al. and Volpi et al. reported a negative effect of advanced age while Michel J. et al. and Michel G. et al. found no impact [3, 4, 9, 10]. We found one study [8] which presented a slightly better 10-year OS in females, however, the difference disappeared with longer observation. Most researchers found no correlation between gender and prognosis [7, 9].

Ethnicity is also a matter of debate. In the group analyzed by Sanghvi et al. the best survival was exhibited among others (non-black, non-whites) with 76.18% 5-year OS, whites had 69.22% 5-year OS, and the least favorable outcomes were reported in blacks (56.06% 5-year OS). Other researchers reported no impact of ethnicity [7].

Most authors agree that endonasal site at the initial presentation favors better survival outcomes, when epicenter in the sinus cavity,

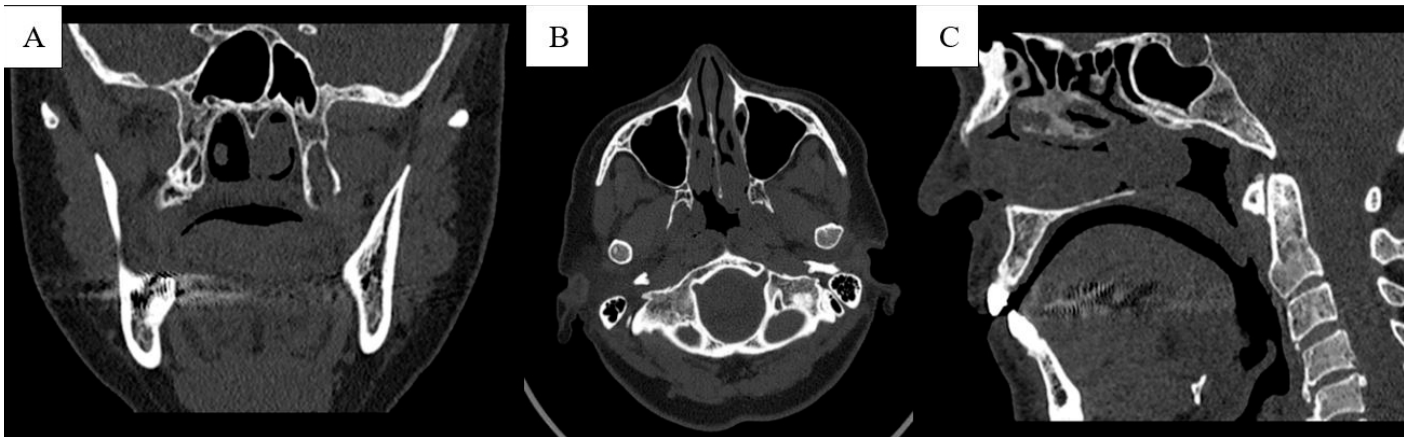


Fig. 2. Computed tomography showing a polypoid lesion arising from the posterior portion of the left inferior turbinate expanding towards the left choana with slight contrast enhancement. Coronal (A), axial (B), and sagittal (C) planes.

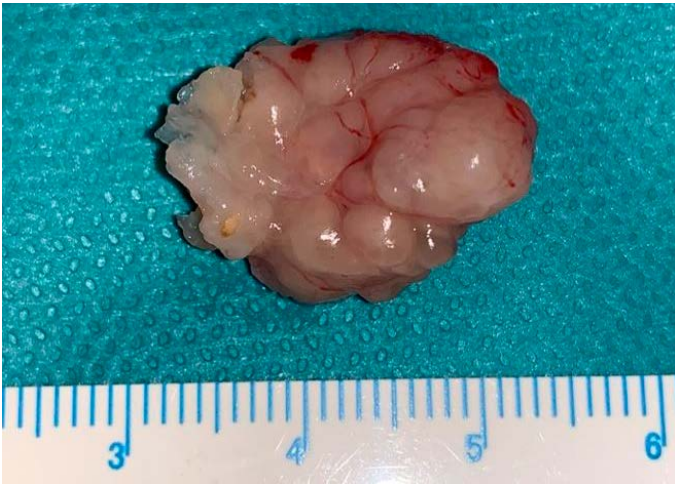

Fig. 3. The tumor was resected in one piece.

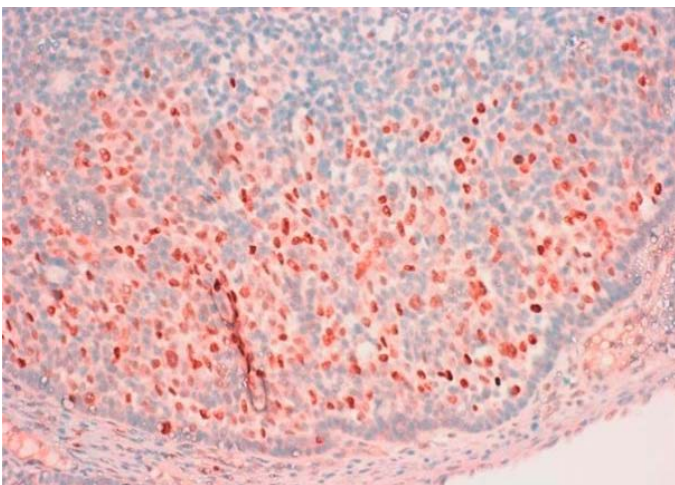


Fig. 4. The histopathological examination showing an anti-MYB positive adenoid cystic carcinoma without perineural invasion.

especially the frontal and ethmoid sinus is related to a worse prognosis [3, 5, 7]. Nonetheless, in the series reported by Michel J. et al. and Michel G. et al. there was no correlation between the initial location and survival [9, 10].

Non-specific symptomatology results in delayed diagnosis. Most cases of SNACC are detected at an advanced stage which was exhibited as a poor prognostic factor by the majority of researchers [1, 4, 5, 10]. However, some found only distant metastasis to be of impact [7]. Michel J. et al. showed no correlation after retrospectively analyzing 11 patients with SNACC [9].

Pathology plays an important role. The solid subtype has more tumor cells than tubular or cribriform Subtypes, which might be of impact [1]. Grade III [3, 4, 7] and the solid type [5, 10] are related to a poor OS.

So far, there is no agreement on the margins' status role. Positive margins were reported as a poor prognostic factor by Trope et al., Volpi et al., Michel G. et al. On the contrary, Mays et al. found no correlation in the group of 160 patients [3, 4, 5], which might be surprising. They conclude that adjuvant radiotherapy or chemoradiotherapy might mask the potential benefit of clearing all disease at the time of surgery [5].

The perineural infiltration is another uncertain factor. Volpi et al. found a negative impact on OS, Mays et al. demonstrated a decrease in both OS and DFS when large nerves were involved [4, 5]. In contrast, other studies have reported that microscopic perineural invasion was not associated with survival [1].

The impact of the recurrence of the disease is also questionable. It was proven to worsen the prognosis by some researchers [5, 10] while others presented no correlation [1]. Interestingly, the nodal status was found to have no impact on OS [5, 7].

Due to the high risk of the late recurrence, lifetime surveillance is compulsory. Kim et al. found that SNACC had the most common post-5-year recurrences of all sinonasal cancers (33.3%) [12]. In comparison, all cancers in the sinonasal region showed an 11.7% recurrence rate after a 5-year disease-free period. Also, as much as 11.1% of initially cured SNACC patients developed a local recurrence within the 10-to-15-year period, and 5.6% of the patients were diagnosed with distant metastasis in the 5- to-10-year period [12]. According to the European guidelines, a lifetime 6-month follow-up after 3 years is recommended [15].

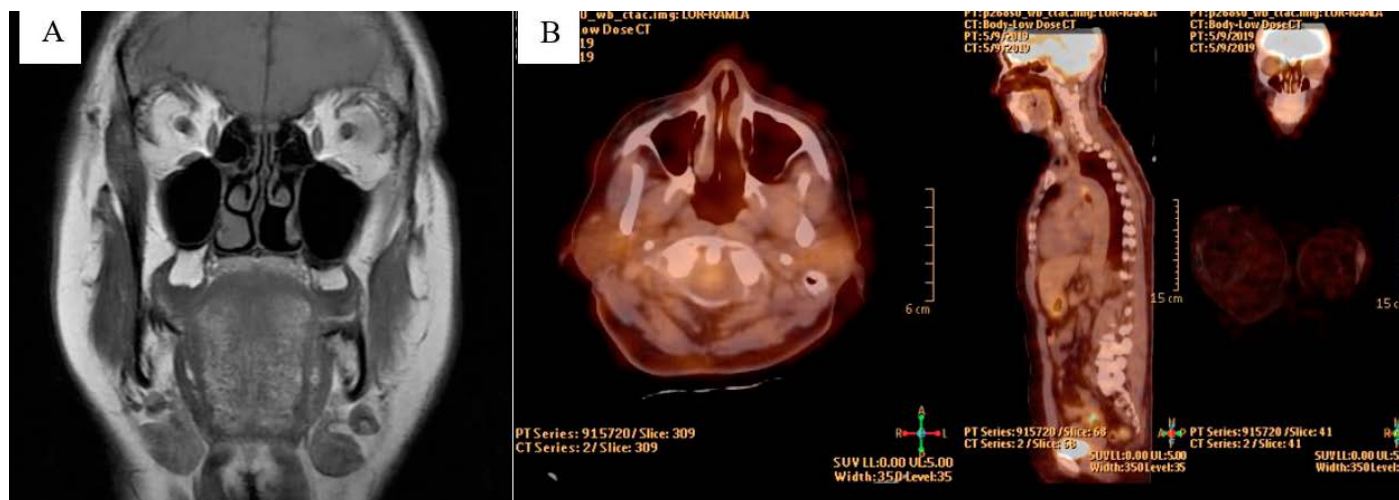


Fig. 5. Magnetic resonance imaging (MRI) of the head and neck (A) and whole-body PET/CT (B) scan were clear of disease. Gross reduction of the posterior part of the left inferior turbinate can be observed.

CONCLUSION

SNACC is a rare malignancy, characterized by slow growth and perineural infiltration with spreading towards the skull base, cavernous sinus, and orbit. The regional nodal involvement is

rare. Frequent and delayed distant metastases in lung, bone, liver, and brain are also typical. The significance of prognostic factors remains unclear.

Lifelong surveillance is obligatory as very late recurrences are common.

References

- Rhee C.S., Won T.B., Lee C.H. et al.: Adenoid cystic carcinoma of the sinonasal tract: treatment results. *Laryngoscope.*, 2006; 116(6): 982–986.
- Stelow E.B., Bishop J.A.: Update from the 4th Edition of the World Health Organization Classification of Head and Neck Tumours: Tumors of the Nasal Cavity, Paranasal Sinuses and Skull Base. *Head and Neck Pathol.*, 2017; 11: 3–15.
- Trope M., Triantafyllou V., Kohanski M.A. et al.: Adenoid cystic carcinoma of the sinonasal tract: a review of the national cancer database. *Int Forum Allergy Rhinol.*, 2019; 9(4): 427–434.
- Volpi L., Bignami M., Lepera D. et al.: Endoscopic endonasal resection of adenoid cystic carcinoma of the sinonasal tract and skull base. *Laryngoscope.*, 2019; 129(5): 1071–1077.
- Mays A.C., Hanna E.Y., Ferrarotto R. et al.: Prognostic factors and survival in adenoid cystic carcinoma of the sinonasal cavity. *Head Neck.*, 2018; 40(12): 2596–2605.
- Miller E.D., Blakaj D.M., Swanson B.J. et al.: Sinonasal adenoid cystic carcinoma: Treatment outcomes and association with humanpapillomavirus. *Head Neck.*, 2017; 39(7): 1405–1411.
- Unsal A.A., Chung S.Y., Zhou A.H. et al.: Sinonasal adenoid cystic carcinoma: a population-based analysis of 694 cases. *Int Forum Allergy Rhinol.*, 2017; 7(3): 312–320.
- Sanghvi S., Patel N.R., Patel C.R. et al.: Sinonasal adenoid cystic carcinoma: comprehensive analysis of incidence and survival from 1973 to 2009. *Laryngoscope.*, 2013; 123(7): 1592–1597.
- Michel J., Fakhry N., Santini L. et al.: Sinonasal adenoid cystic carcinomas: clinical outcomes and predictive factors. *Int J Oral Maxillofac Surg.*, 2013; 42(2): 153–157.
- Michel G., Joubert M., Delemazure A.S. et al.: Adenoid cystic carcinoma of the paranasal sinuses: Retrospective series and review of the literature. *Eur Ann Otorhinolaryngol Head Neck Dis.*, 2013; 130(5): 257–262.
- Kostrzewa J.P., Sunde J., Riley K.O. et al.: Radiofrequency coblation decreases blood loss during endoscopic sinonasal and skull basetumor removal. *ORL J Otorhinolaryngol Relat Spec.*, 2010; 72(1): 38–43.
- Kim S.A., Chung Y.S., Lee B.J.: Recurrence patterns of sinonasal cancers after a 5-year disease-free period. *Laryngoscope.*, 2019 Feb 22. DOI: 10.1002/lary.27866. [Epub ahead of print]
- Tirelli G., Capriotti V., Sartori G. et al.: Primary Adenoid Cystic Carcinoma of the Frontal Sinus: Case Description of a Previously Unreported Entity and Literature Review. *Ear Nose Throat J.*, 2019; 98(4): E8–E12.
- Bishop J.A., Devaney K.O., Barnes L. et al.: Cervical lymph node metastasis in adenoid cystic carcinoma of the sinonasal tract, nasopharynx, lacrimal glands and external auditory canal: a collective international review. *J Laryngol Otol.*, 2016; 130(12): 1093–1097.
- Lund V.J., Stammberger H., Nicolai P. et al.: European position paper on endoscopic management of tumours of the nose, paranasal sinuses and skull base. *Rhinol Suppl.*, 2010; 22: 1–143.

Word count: 2810 Tables: 1 Figures: 5 References: 15


Access the article online: DOI: 10.5604/01.3001.0013.8789


Table of content: <https://otorhinolaryngologypl.com/issue/12511>

Corresponding author: Prof. Pedro Clarós; ORCID: 0000-0002-7567-0370; Clínica Clarós, C. Los Vergós 31, 08017 Barcelona, Spain; Phone: +34 93 203 12 12; E-mail: clinica@clinicaclaros.com

Copyright © 2020 Polish Society of Otorhinolaryngologists Head and Neck Surgeons. Published by Index Copernicus Sp. z o.o. All rights reserved

Competing interests: The authors declare that they have no competing interests.

 The content of the journal „Polish Society of Otorhinolaryngologists Head and Neck Surgeons” is circulated on the basis of the Open Access which means free and limitless access to scientific data.

 This material is available under the Creative Commons – Attribution 4.0 GB. The full terms of this license are available on: <http://creativecommons.org/licenses/by-nc-sa/4.0/legalcode>

Cite this article as: Clarós P., Wałag A., Clarós A.: Endoscopic resection of sinonasal adenoid cystic carcinoma with radiofrequency coblation. A clinical report with literature review; Pol Otorhino Rev 2020; 9 (1): 45-50
