INDEX COPERNICUS INTERNATIONAL

ORIGINAL ARTICLE

Endovascular treatment of visceral artery aneurysms and pseudoaneurysms – evaluation of efficacy and safety based on long-term results

Authors' Contribution:
A – Study Design
B – Data Collection
C – Statistical Analysis
D – Data Interpretation
E – Manuscript Preparation
F – Literature Search
G – Funds Collection

Krzysztof Pyra[ABCDEF], Maciej Szmygin[ABCDEF], Michał Sojka[ABEF], Anna Drelich-Zbroja[ABF], Tomasz Jargiełło[ABF]

Department of Interventional Radiology and Neuroradiology, Medical University of Lublin, Poland;
Head: prof. Tomasz Jargiełło MD PhD

Article history: Received: 22.10.2019 Accepted: 20.11.2019 Published: 21.11.2019

ABSTRACT:

Background: With estimated prevalence of 1% of the general population, visceral artery aneurysms are not a frequent pathology, however, their rupture is a life-threatening occurrence with mortality rate ranging from 10% to 25%, up to 75% in case of pregnant women. Therefore, the identification and treatment of visceral artery aneurysms is of great importance in the prevention of early rupture.

Purpose: To assess the effectiveness and safety of treatment of visceral artery aneurysms with various endovascular methods focusing on technical aspects, complications and long-term clinical outcome.

Materials and Methods: 60 patients with visceral artery aneurysms were treated percutaneously. Various techniques were used: coiling (23), covered stents (15), thrombin (7), and other mixed techniques. Aneurysm characteristics, size and localization, procedural data, peri-procedural complications, technical success, 90- and 180-day clinical success and follow-up period (aneurysm exclusion, patency of the artery and complications) were prospectively analyzed.

Results: The procedure was performed in 57 of 60 patients. In 56 of 57 patients aneurysms ware effectively excluded. The success rate was 93.3% (56 of 60 enrolled patients). Technical success after the intervention was 82.4%, after second 98.2%. Embolization with covered stents was characterized by the highest efficiency. Serious complications occurred in 1.8% of cases.

Conclusions: The minimally invasive endovascular treatment of visceral artery aneurysms is characterized by high efficacy and safety. Good treatment results depend on proper assessment of the aneurysm's morphology as well as on selection of the appropriate vascular approach and endovascular technique.

KEYWORDS: aneurysms, endovascular, long-term results, visceral

ABBREVIATIONS

3DRA – 3D rotational angiography
GDA – gastroduodenal aneurysms
HAA – hepatic artery
SAA – aneurysm of the splenic artery
SIR – Society of Interventional Radiology
VAA – visceral artery aneurysm

INTRODUCTION

With documented prevalence of 0.1–2% [1] visceral aneurysmal degeneration is a rare but potentially life-threatening disease entity. Visceral artery aneursym (VAA) is most commonly found in the splenic (60–80%), hepatic (20%) and superior mesenteric artery (5.5%). Widely available ultrasonography and cross-sectional body imaging observed over last few decades has risen the incidental identification of VAA. Degenerative changes of the middle layer of the artery – tunica media which consists of smooth muscle cells, elastic tissue and collagen are responsible for the majority of the aneurysms. They result in fragmentation and loss of muscle fibers and lead eventually to weakening of the vessel. The other causes are: atherosclerosis, hypertension, fibromuscular dysplasia and connective tissue diseases. Visceral artery aneurysms and pseudoaneurysms can also have a post-inflammatory origin. Acute pancreatitis during which the vessel wall is exposed to proteolytic enzymes' activity may lead to the development of aneurysms and pseudoaneurysms in peri-pancreatic arteries [2].

Clinical manifestations of VAA depend on the size and location but the majority of them are asymptomatic and are detected incidentally. Nowadays, radiologists have a variety of imaging examinations at their disposal, from Ultrasound Doppler to Digital Subtraction Angiography and Computed Tomography Angiography or Magnetic Resonance Angiography that enable them to visualize and reconstruct the vessels in 3D.

The treatment of visceral artery aneurysms can be both surgical and percutaneous and depends on their location and morphology as well as comorbidities and acute clinical condition of the patient. Endovascular methods should be considered particularly in cases of extensive comorbidities after thorough examination of vascular surgeon and interventional radiologist [3]. Close cooperation of the above-mentioned specialists is a key to successful treatment.

MATERIALS AND METHODS

In total, 60 patients with VAA were referred to the Department of Interventional Radiology and Neuroradiology for endovascular treatment from January 2014 to July 2018. From this group, 57 were

treated. The mean age of the patients was 49.9 years (range from 28–89). The majority of patients were asymptomatic (44–77.2%) and the aneurysms were detected incidentally. The rest (13–22.8%) reported discomfort in the abdominal area.

Nearly 60% of discovered VAAs were aneurysms of splenic artery. Aneurysms of hepatic and gastroduodenal arteries made up 15.8% and 19.3% respectively. The least common were aneurysms of the superior mesenteric artery, found in 3 (5.3%) cases. True aneurysms (31–54.4%) were differentiated from pseudoaneurysms (26–45.6%) based on clinical and morphological criteria. The mean maximum diameter of the treated aneurysms was 25.8 mm (12–57 mm). Tab. I. shows the data gathered before the treatment.

All patients were asked to fulfill the survey concerning their medication, lifestyle and comorbidities. Following risk factors were included: hypertension, arteriosclerosis, vasculitis, connective tissue diseases, smoking. All patients were consulted by Interventional Radiologist and Vascular Surgeon who explained the procedure, possible risks and complications and obtained informed consent afterwards.

The materials and techniques used in all interventions were evaluated. Angiography was performed at the beginning of every procedure. In inconclusive or questionable cases the aneurysms were depicted with 3D rotational angiography (3DRA). Following factors were taken into account when choosing the treatment method: location of the aneurysm, dome-to-neck ratio, tortuosity of the parent vessel and inflow angle.

Due to favorable vascular conditions (narrow neck, dome-to-neck radio >2, little tortuosity of the parent vessel) coils and covered stents were used in the majority of cases. In cases with particularly unfavorable morphology of the aneurysm (wide neck, dome-to-neck ratio <2) balloon or stent-assisted coiling technique was performed.

The percentage of successful primary interventions and the rate of re-interventions were evaluated. Technical success assessed in control angiography was defined as complete elimination of the (pseudo-) aneurysm after the intervention. All patients underwent Ultrasound Doppler examination within 24 hours after the intervention. Complications during the procedure or occurring within a maximum of 30 days after the intervention were evaluated and classified according to the guidelines of the Society of Interventional Radiology [4].

Statistical analyses of the results were carried out using the Statistica Program. Normal distribution of continuous variables was verified using the Shapiro-Wilk`s W test, the significance of relationships between variables by means of the Chi-square test and Spearman coefficient of rank correlation. A significance level of $\alpha = 0.05$ was defined.

RESULTS

From the group of 60 patients with a diagnosed VAA, 57 were treated because in 3 cases safe vascular access could not have been obtained and therefore the patients were disqualified from the treatment. In 31 patients there were true aneurysms and in 26 pseudoaneurysms. Interestingly, the correlation between sex and aneurysm type is almost exactly opposite - female patients were diagnosed with 26 (72.2%) aneurysms and 10 (27.8%) pseudoaneurysms, whereas male patients with 5 (23.8%) aneurysms and 16 (76.2%) pseudoaneurysms.

Tab. I. Characteristics of the patients.

PATIENTS (N)	57 36 FEMALE; 21 MALE
Mean age (years)	49.9
Median age (years)	47 ± 14 (28–89)
Aneurysms/Pseudoaneurysms	31/26
Location:	
Splenic artery	34 (59.6%)
Hepatic artery	9 (15.8%)
Gastroduodenal artery	11 (19.3%)
Superior mesenteric artery	3 (5.3%)
Mean maximum diameter (mm)	26.8
Median maximum diameter (mm)	23 ± 10.3 (12–57)
Clinical manifestations:	
Asymptomatic	44 (77.2%)
Abdominal pain	13 (22.8%)
Nausea, vomiting	1 (1.8%)

Tab. II. Techniques used during primary intervention.

USED TECHNIQUE	NUMBER (N)	PERCENTAGE (%)
Coils	23	40.4
Covered stent	15	26.3
Thrombin	10	17.5
Liquid embolic agent	3	5.3
Balloon-assisted coiling	1	1.8
Stent-assisted coiling	3	5.3
Coils + thrombin	2	3.5

All interventions were performed in local anesthesia. In 51 cases (89%) femoral and in 6 (11%) axillary access was obtained. In each case selective angiography determined final decision on treatment details. The details of the procedures are presented in Tab. II.

The percentage of successful primary interventions and the rate of re-interventions were evaluated. Technical success assessed in control angiography was defined as complete elimination perfusion in VAA after the intervention.

Splenic artery was the most common location of VAA – 34 cases (59.6%) from which 25 (74%) were true aneurysms and 9 (26%) pseudoaneurysms. As many as 21 patients (62%) were treated once and the rest, 13 (38%), required secondary intervention. In the first group coils were used in the majority of cases (12–55%), followed by covered stents (6–27%), thrombin (3–14%) and stent-assisted coiling in 1 case. Reinterventions were necessary due to inadequate coil packing in the aneurysmal sac in 8 cases and multiple aneurysms in 5. Multiple aneurysms of the splenic artery were treated with coils (3), thrombin (1), and coils + thrombin (1).

Second most common location of VAA was gastroduodenal artery – 11 cases. All aneurysmal degenerations in this group were pseudoaneurysms. Apart from 1 case all patients were treated once. Following techniques were deployed: coils (6–55%), covered stent

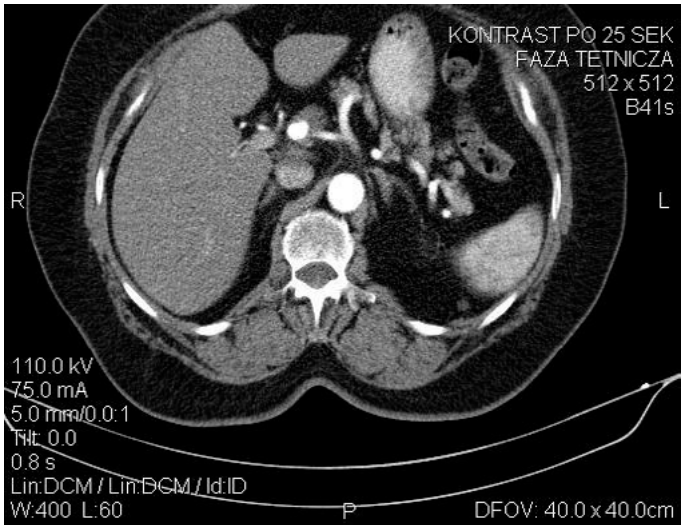

Fig. 1. CT-scan of a 66-year-old female patient with hepatic artery pseudoaneurysm.

(3–27%) and liquid embolic agents (2–8%). In one case secondary coiling was required.

Nine VAAs were located in the hepatic artery, 2 of which were intrahepatic and 7 extrahepatic. Pseudoaneurysms were significantly more common than true aneurysms (6 and 3 respectively). All patients in this group underwent one procedure. Methods used were equivalent in frequency – 33% coils, 33% covered stents and 33% thrombin.

Aneurysms of the superior mesenteric artery were diagnosed in 3 patients (1 pseudoaneurysm and 2 true aneurysms). All cases were treated with covered stents during primary intervention.

Technical success was firstly assessed in a control angiography performed after the procedure. Complete elimination of the (pseudo) aneurysm was observed in 30 cases (52.6%) and partial elimination in 27 cases (47.4%).

Ultrasound Doppler examinations were performed 24 hours, 3 months and 6 months after the intervention in all treated patients. In inconclusive or questionable cases CTA and MRA were used. The rate of complete exclusion of an aneurysm was gradually higher with time (70.2% after 24 hours, 82.5% after 3 months) and finally reached 98.2% in a 6-moth follow-up period. Fig. 4. presents the follow-up data.

Parent vessel patency after the intervention was also reported on. In 6 cases due to well developed collateral circulation and complex anatomical condition, a "trapping" technique was employed and both parent vessels and aneurysms were occluded. In 1 case stenting of the splenic artery led to parent artery occlusion and development of collateral circulation from pancreatic branches. In 50 cases (87.7%) at 6-month follow-up USG examination proved patency of the parent artery.

The efficacy of the following endovascular methods was compared using the Chi-square test: coils, covered stents and other. Results at control angiography and USG examination 24 hours after the intervention are comparable – complete elimination was observed in 9 of 23 (39.1%) patients treated with coils, 15 of 15 (100%) with covered stents and 7 of 19 (36.8%) with other methods. Tests performed 6 months after the intervention show 100% efficacy in case of coils and covered stents and 94.7% (18 of 19 patients) with other techniques.

The complication rate for all endovascular interventions was 12.3% (n = 7). According to the SIR classification (Society of Interventional Radiology) there were 6 minor complications and 1 major complication. Minor complications included 4 hematomas (3 inguinal and 1 axillary), 1 case of hepatic artery dissection (control examination showed proper blood flow) and 1 case of parenchymal infarction in the flow region of the treated aneurysm. It was partial splenic infarction but loss of spleen function was not observed in the follow-up period.

One patient with an aneurysm of the gastroduodenal artery after "trapping" embolization reported severe abdominal pain. Control angiography disclosed occlusion of the proximal part of the superior mesenteric artery. Clot removal and balloon angioplasty were successfully performed. After a few days of hospitalization the patient was discharged in a good clinical condition.

DISCUSSION

VAA is a rare but potentially life-threatening disease entity. Increased number of endoscopic operations, endovascular interventions and lifestyle predisposing to pancreatitis on one hand and increased accessibility of ultrasonography and cross-sectional body imaging on the other lead to increase in incidental identification of VAA. Early diagnosis and treatment is critical for prevention of rupture. Authors report that mortality rates of patients with ruptured VAA range from 10–20% to 75% during pregnancy [5–7]. One of the factors determining high mortality is the location of the aneurysm – self-limiting bleeding from hepatic artery or gastroduodenal artery results in mortality of 20–35% and 50% respectively, whereas retroperitoneal bleeding from mesenteric arteries or celiac artery may be fatal in up to 100% of cases. Therefore, safe and effective treatment is crucial.

Among VAAs, the aneurysm of the splenic artery (SAA) is reported to be most frequent. In our study they accounted for 60% of VAA, which remains with concordance with the literature [8]. Due to an increasing number of hepatobiliary interventions, aneurysm of the hepatic artery (HAA) is the second most common type of VAA of nontraumatic origin. They account for 20% of cases and are more characteristic for male patients [9]. Also, in contradiction to recent reports, our analysis detected 11 (19.3%) gastroduodenal aneurysms (GDAs) which are not a common type of VAA [10].

The indication for treatment should derive from existing symptoms, or in cases of asymptomatic patients be determined based on the risk of rupture that corresponds with the diameter of the aneurysm. Belli et al. [11] recommend to treat aneurysms with a diameter of minimum 20 mm, regardless of the diameter of the parent vessel. This indication expands however in cases of women who wish to become pregnant and includes all asymptomatic aneurysms regardless of the size of the aneurysmal sac [12]. According to the guidelines, treatment of VAA with a diameter smaller than 2 cm is recommended if the VAA exceeds three times the diameter of the respective normal artery [13, 14]. At our study, the mean maximum diameter was 26.8 mm. Treatment decisions in patients with aneurysm diameter below 2 cm were based on an

Fig. 2a. Selective angiography of the common hepatic artery – brachial artery access.

Fig. 2b. The positioning of a balloon-expandable covered stent.

Fig. 3. Control angiography performed after the procedure shows proper stent placement and complete aneurysm exclusion.

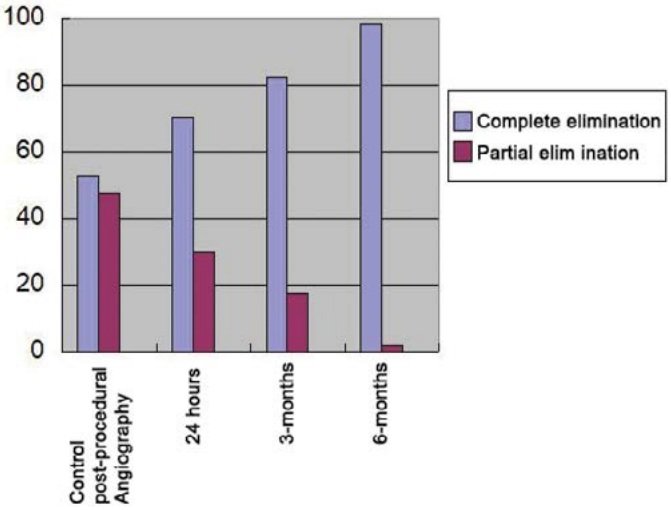

Fig. 4. Follow-up results.

interdisciplinary discussion that included not only the aetiology of the aneurysms but also all clinical aspects of the particular case.

In 2015 Pitton et al. [15] published data of over 200 VAAs treated over a 10-year period in which the authors concluded that the type of aneurysm rather than its size seems to be a reliable predictor of rupture. Hence, the diameter alone is an inadequate criterion for decision making and the management should rather be based on the aetiology of aneurysmal degeneration [16]. According to Pitton et al., pseudoaneurysms presented with a significantly increased risk of rupture (76.3%) compared with true aneurysms (3.1%). Nevertheless, conservative treatment of true VVAs remains a matter of debate [17, 18]. Our results show that pseudoaneurysms are more common in men than women and therefore men are treated more frequently.

Traditionally, open surgery under general anaesthesia was the only possible treatment for VAAs. In contrast, interventional techniques are performed under local anaesthesia which reduces the risks of complications and shortens hospital stays. Treatment modalities include coiling, stent grafting or embolization and are characterized by a high technical success rate [19, 20]. In our study the majority of patients were treated using stents and coils (73.8%). Procedures with covered stents were successful in 100% and therefore it seems that this method should be implemented whenever vascular anatomy and aneurysm's morphology is favorable. The combination of two methods – "stent-assisted coiling" widely performed by neuroradiologists [21] – also proved to be safe and effective, especially in aneurysms with a less favorable head-to-neck ratio. The only limitation results from a relatively large diameter of catheters used for stent implantation. The complication rate for endovascular treatment was 12.3% and was comparable with other series published [22]. Apart from most common and characteristic for procedures performed with the Seldinger technique haematomas at the arterial puncture site, we noted arterial thrombosis resulting in organ infarction, artery dissection and artery occlusion.

Our study has some limitations. First of all, incoherence of patients – 14 (25%) were treated 2 times and therefore it is impossible to draw valid conclusions regarding primary endovascular treatment of VAAs. Ideally, a very coherent and randomized group of patients is required to clearly define the optimal treatment for VAA. Secondly, authors recommend a follow-up for at least 1 year after the treatment. In our case, the follow-up period was limited to 6 months post-procedural.

In conclusion, aneurysms of visceral arteries are a rare but potentially life-threatening disease entity with an estimated preva-

lence of 0.1–2%. Treatment options include open surgery and endovascular techniques. Patients should be therefore consulted by an interdisciplinary board consisting of a Vascular Surgeon and Interventional Radiologist. The best treatment modality should be a result of team work and close cooperation of both specialists. Methods of interventional radiology are safe and effective treatment modalities both in case of true aneurysms and pseudoaneurysms. Among endovascular techniques, covered stents were characterized by the highest efficacy, while thrombin therapy by the lowest. Aneurysm size, location, etiology and morphology are the factors determining treatment success and periprocedural morbidity and complications.

REFERENCES

1. Tulsyan N., Kashyap V.S., Greenberg R.K., Sarac T.P., Clair D.G. et al.: The endovascular management of visceral artery aneurysms and pseudoaneurysms. Journal Vasc Surg, 2007; 45(2): 276–283.
2. Zabicki B., Limphaibool N., Holstad M.J.V., Juszkat R.: Endovascular management of pancreatitis-related pseudoaneurysms: a review of techniques. PLoS One, 2018; 13: e0191998.
3. Ruhnke H., Kröncke T.: Visceral Artery Aneurysms and Pseudoaneurysms: Retrospective Analysis of Interventional Endovascular Therapy of 43 Aneurysms. RöFo – Fortschritte Auf Dem Gebiet Der Röntgenstrahlen Und Der Bildgebenden Verfahren, 2017; 189(07): 632–639.
4. Omary R.A., Bettmann M.A., Cardella J.F., Bakal C.V., Schwartzberg M.S. et al.: Quality improvement guidelines for the reporting and archiving of interventional radiology procedures. J Vasc Interv Radiol, 2003; 14: S293–S295.
5. Chiesa R., Astore D., Guzzo G., Frigerio S., Tshomba Y. et al.: Visceral artery aneurysms. Ann Vasc Surg, 2005; 19: 42–48.
6. Panayiotopoulos Y.P., Assadourian R., Taylor P.R.: Aneurysms of the visceral and renal arteries. Ann R Coll Surg Engl, 1996; 78: 412–419.
7. Shanley C.J., Shah N.L., Messina L.M.: Common splanchnic artery aneurysms: splenic, hepatic, and celiac. Ann Vasc Surg, 1996; 10: 315–322.
8. Jesinger R.A., Thoreson A.A., Lamba R.: Abdominal and pelvic aneurysms and pseudoaneurysms: imaging review with clinical, radiologic, and treatment correlation. Radiographics., 2013; 33: E71–96.
9. Arend P., Douillez V.: Hepatic artery aneurysm: case report. Acta Chir Belg, 2007; 107(4): 409–411.
10. Moore E., Matthews M.R., Minion D.J., Quick R., Schwarcz T.S. et al.: Surgical management of peripancreatic arterial aneurysms. J Vasc Surg, 2004; 40(2): 247–253.
11. Belli A.M., Markose G., Morgan R.: The role of interventional radiology in the management of abdominal visceral artery aneurysms. Cardiovasc Intervent Radiol, 2012; 35: 234–243.
12. Carroccio A., Jacobs T.S., Faries P., Carroccio A., Jacobs T.S. et al.: Endovascular treatment of visceral artery aneurysms. Vasc Endovascular Surg, 2007; 41: 373–382.
13. Liu Q., Lu J.P., Wang F., Wang L., Jin A.G. et al.: Visceral artery aneurysms: evaluation using 3D contrast-enhanced MR angiography. AJR Am J Roentgenol., 2008; 191: 826–833.
14. Pasha S.F., Gloviczki P., Stanson A.W., Kamath P.S.: Splanchnic artery aneurysms. Mayo Clin Proc., 2007; 82: 472–479.
15. Pitton M.B., Dappa E., Jungmann F., Kloeckner R., Schotten S. et al.: Visceral artery aneurysms: Incidence, management, and outcome analysis in a tertiary care center over one decade. Eur Radiol., 2015; 25(7): 2004–2014.
16. Dawson J., Fitridge R.: Update on aneurysm disease: current insights and controversies: peripheral aneurysms: when to intervene – is rupture really a danger? Prog Cardiovasc Dis., 2013; 56: 26–35.
17. Sessa C., Tinelli G., Porcu P., Aubert A., Thony F. et al.: Treatment of visceral artery aneurysms: description of a retrospective series of 42 aneurysms in 34 patients. Ann Vasc Surg., 2004; 18: 695–703.
18. Abbas M.A., Stone W.M., Fowl R.J., Gloviczki P., Oldenburg W.A. et al.: Splenic artery aneurysms: two decades experience at mayo clinic. Ann Vasc Surg., 2002; 16: 442–449.
19. Gabelmann A., Görich J., Merkle E.M.: Endovascular treatment of visceral artery aneurysms. J Endovasc Ther., 2002; 9: 38–47.
20. Hossain A., Reis E.D., Dave S.P., Kerstein M.D., Hollier L.H.: Visceral artery aneurysms: experience in a tertiary-care center. Am Surg., 2001; 67: 432–437.
21. Ghinda et al.: Clinical and angiographic outcomes of stent-assisted coiling of intracranial aneurysms. Interv Neuroradiol., 2015; 21(2): 146–154.
22. Cochennec F., Riga C.V., Allaire E., Cheshire N.J., Hamady M. et al.: Contemporary management of splanchnic and renal artery aneurysms: results of endovascular compared with open surgery from two European vascular centers. Eur J Vasc Endovasc Surg., 2011; 42: 340–346.

Liczba słów: 3240 Liczba stron: 6 Tabele: 2 Ryciny: 4 Piśmiennictwo: 22

DOI: 10.5604/01.3001.0013.5895 Table of content: https://ppch.pl/issue/12552

Competing interests: The authors declare that they have no competing interests.

Corresponding author: Maciej Szmygin; Department of Interventional Radiology and Neuroradiology, Medical University of Lublin, Poland, Jaczewskiego St. 8, 20-954 Lublin, Poland; Phone: +81 724 41 54; E-mail: mszmygin@gmail.com

Cite this article as: Pyra K., Szmygin M., Sojka M., Drelich-Zbroja A., Jargiello T.: Endovascular treatment of visceral artery aneurysms and pseudoaneurysms – evaluation of efficacy and safety based on long-term results; Pol Przegl Chir 2020: 92 (1): 23–28