INDEX COPERNICUS INTERNATIONAL

CASE REPORT

# Minimally Invasive Repair of Acquired Benign Thoracic Tracheo-Esophageal Fistula

**Authors' Contribution:**
**A** – Study Design
**B** – Data Collection
**C** – Statistical Analysis
**D** – Data Interpretation
**E** – Manuscript Preparation
**F** – Literature Search
**G** – Funds Collection

Jayant Kumar Banerjee[ABCDEF], Ramanathan Saranga Bharathi

Department of Gastrointestinal Surgery, Command Hospital Central Command), Lucknow, Uttar Pradesh, India

Article history: Received: 05.01.2019 Accepted: 10.03.2019 Published: 25.03.2019

**ABSTRACT:**

**Background:** Repair of large, upper thoracic, cuff-induced, tracheo-esophageal fistula (TEF) is technically demanding and is conventionally performed by open surgery. Minimal access approach is, hitherto, unreported.

**Technique & Case:** Minimally invasive repair of TEF involving fistula isolation – by thoracoscopic oesophageal exclusion, and simultaneous establishment of alimentary continuity – by laparoscopy-assisted sub-sternal colonic transposition, is described. The technique was successfully employed in repairing a large (4.5 centimetres), cuff-induced, upper thoracic TEF, in a 25-year-old woman. The rationale behind the technique, its pros and cons are analysed and contrasted against conventional techniques of TEF repair.

**Conclusion:** Large upper thoracic, cuff-induced TEF can be successfully repaired employing minimal access.

**KEYWORDS:** fistula exclusion, laparoscopy, single stage procedure, sub-sternal colonic transposition, thoracoscopy, tracheo-esophageal fistula

## SINGLE-SENTENCE SUMMARY

Large upper thoracic, cuff-induced tracheo-esophageal fistula can be successfully repaired employing minimal access, in a single stage, by fistula isolation and simultaneous establishment of alimentary continuity by sub-sternal colonic transposition.

## INTRODUCTION

Repair of large, thoracic, cuff-induced, tracheo-esophageal fistula (TEF) is difficult [1]. It is, conventionally, performed by open surgery, which entails access trauma and recurrent laryngeal nerve (RLN) injury, anastomotic dehiscence and tracheal/esophageal stricture [1]. Minimal access surgery (MAS) of TEF, hitherto unreported, is described. It overcomes the above mentioned pitfalls.

## CASE

A 25-year-old woman developed a 4.5 centimetre-long upper thoracic TEF, commencing at the thoracic inlet (Fig. 1.), following prolonged endotracheal/nasogastric intubation for treating organophosphorus poisoning. The patient was tracheostomized, with cuff inflated below TEF, to control aspiration. Nutritional optimisation and resolution of poisoning/aspiration pneumonitis heralded TEF repair.

## TECHNIQUE

Right-sided thoracoscopy was performed in prone position. The esophagus was dissected caudo-cranially up to the level of carina and transected using an endo-stapler (Fig. 2.). Dissection was avoided above the level of the carina to prevent esophageal devascularization and inadvertent breach of TEF. The patient was turned supine. Using left pre-sternomastoid incision, the esophagus was stapled and transected 4 centimetres below the cricoid, whilst preserving RLN and avoiding the fibrosed area where TEF commenced. This created a snug, vascularized, un-violated, full-thickness, cylindrical esophageal cuff, effectively isolating TEF (Fig. 3.).

Colonic mobilization and sub-sternal tunnelling were performed laparoscopically (Fig. 4.). Iso-peristaltic colonic segment, based on the left colic vessels, was transposed sub-sternally, aided by mini-celiotomy (Fig. 5.). Marginal arcade was preserved for enhancing blood supply to colonic conduit. Esophago-colonic anastomosis, in the neck, and colo-antral/colo-colonic anastomoses, in the abdomen, restored alimentary continuity. The operation lasted 4 hours and entailed blood loss of 200 mL.

Oral nutrition was commenced on the 7th post-operative day following normal barium swallow. Imaging, 4 weeks later, showed collapsed/ shrunken esophageal cuff forming the posterior tracheal wall, effectively sealing the TEF (Fig. 6.). The patient was well on follow-up at 2 years and 6 months.

## DISCUSSION

Conservative management and stenting prove ineffective in treating large TEF [1]. Surgery remains the only option [1–4]. However, conventional procedures suffer from shortcomings outlined below, which prompted design/ adoption of the described technique.

Cervical approach: Repairing thoracic TEF through cervical approach proves difficult and unergonomic, even after splitting the manubrium [1, 2].

Primary apposition and flap interposition: Suturing tracheal/esophageal defects may heal small TEF [1–4]. However, large TEF have no membranous segment left for suturing. If attempted, anastomotic dehiscence/ stricture rates are high (50%) [1]. Interposing flaps between the defects may enhance vascularity, but entails tho-

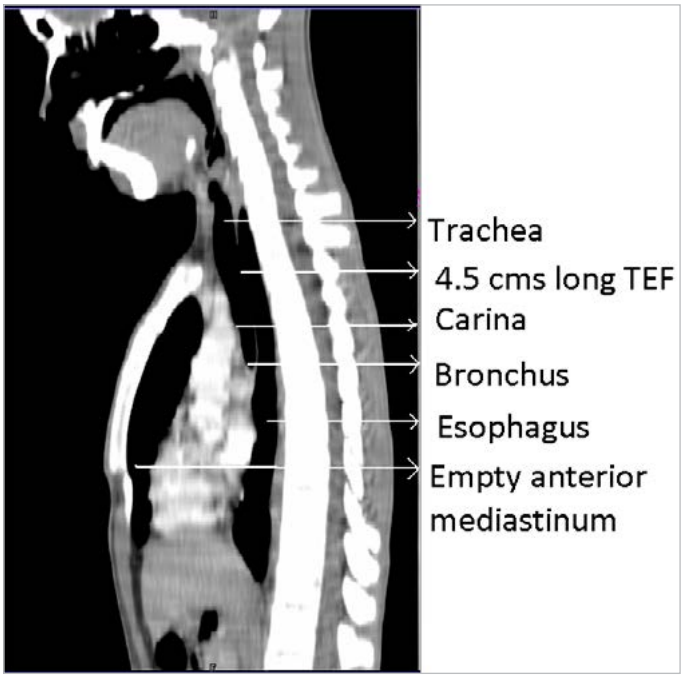


**Fig. 1.** Computerized tomogram showing TEF.

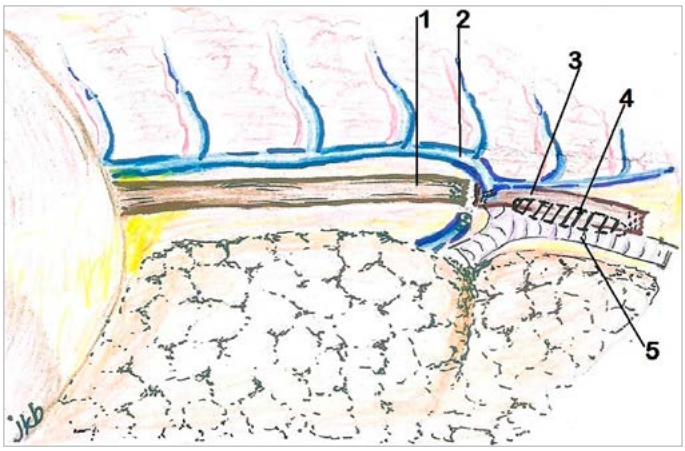


**Fig. 3.** Diagrammatic representation of the procedure in prone position: 1 – Divided distal esophagus; 2 – Azygous vein; 3 – Esophageal cuff; 4 – A 4.5–cm–long tracheoesophageal fistula; 5 – Trachea.

racotomy/ sternotomy and hazardous dissection at the fibrosed tracheo-esophageal groove (TEG), jeopardising RLN [1, 4]. Flaps do necrose, cause dysphagia and form diverticula/flap valve due to airway pressure [1–4].

### Segmental resection and anastomosis

TEF segment may be resected and primarily anastomosed, following cervical/thoracic mobilization [1–4]. However, a large defect (50% of tracheal length, in our case) poses restriction on the number of tracheal cartilages that can be resected and anastomosed, without tension [1–4].

### Esophageal wall flap

Apposing tracheal defect with contiguous esophageal wall courts anastomotic dehiscence, as the esophageal flap derives tenuous vascularity from the fistula site [5]. Moreover, restoring alimentary continuity by orthotopic gastric pull-up renders esophago-gastric

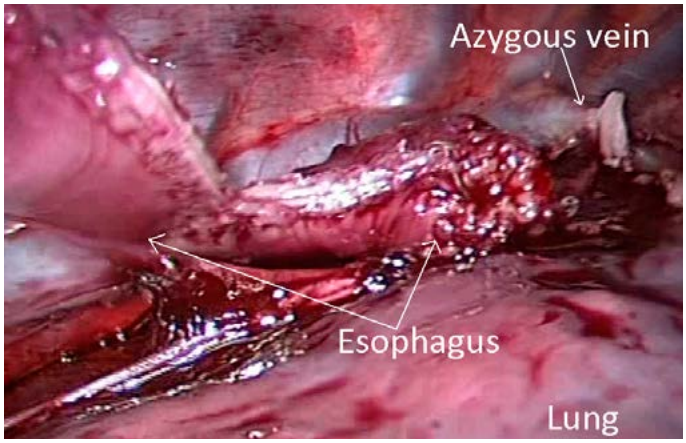


**Fig. 2.** Prone position thoracoscopic view showing the esophagus divided at the level of the azygous arch.

anastomosis prone to leak (20%), stricture (59%), reflux and subsequent Barrett's/malignant transformation [6, 7].

### Fistula isolation

Fistula isolation by cervical esophageal exclusion, with tube pharyngostomy and gastrostomy for salivary drainage and feeding, respectively, is an effective emergent measure in those critically ill. However, it entails salivary loss and needs subsequent reconstruction [8].

## BENEFITS

Our technique proves advantageous in isolating TEF and establishing alimentary continuity in a single stage. It permits early oral nutrition. Avoidance of dissection/repair at fibrosed TEF site preserves RLN and averts anastomotic dehiscence/stricture. As the esophageal cuff is left unviolated, in-situ, its vascularity remains preserved, thanks to tracheo-bronchial vessels [9]. Its not dependent on tenuous blood supply from the fistula site. Traumas of thoracotomy, sternotomy and flaps are avoided. MAS enhances post-operative recovery and cosmesis. Prone-position thoracoscopy avoids single lung ventilation and its complications. By confining surgery to virgin areas, our technique proves easier, faster and bloodless. Our technique utilizes colon, which is a better esophageal substitute than stomach, for benign conditions, where life expectancy is high [6, 10]. It has low leak/stricture rates. It avoids reflux and subsequent problems [6].

## CONCERNS

Mucocele formation in the esophageal cuff is possible, but unlikely, as the cuff is snug, extending just 1 centimetre above and below TEF, which is insufficient to collect copious secretions. A large fistula defect aids coughing out secretions, as they collect. Furthermore, the esophagus is lined by squamous epithelium, with sparse goblet cells and submucosal mucus glands, hence, mucin production is minimal [9].

As per Bernoulli's principle, air flow in the trachea would suck in air from the esophageal cuff, not distend it. Hence, chances of diverticulum/pneumomediastinum formation are minimal. The unviolated esophageal cuff is well anchored by fibrous tissue to

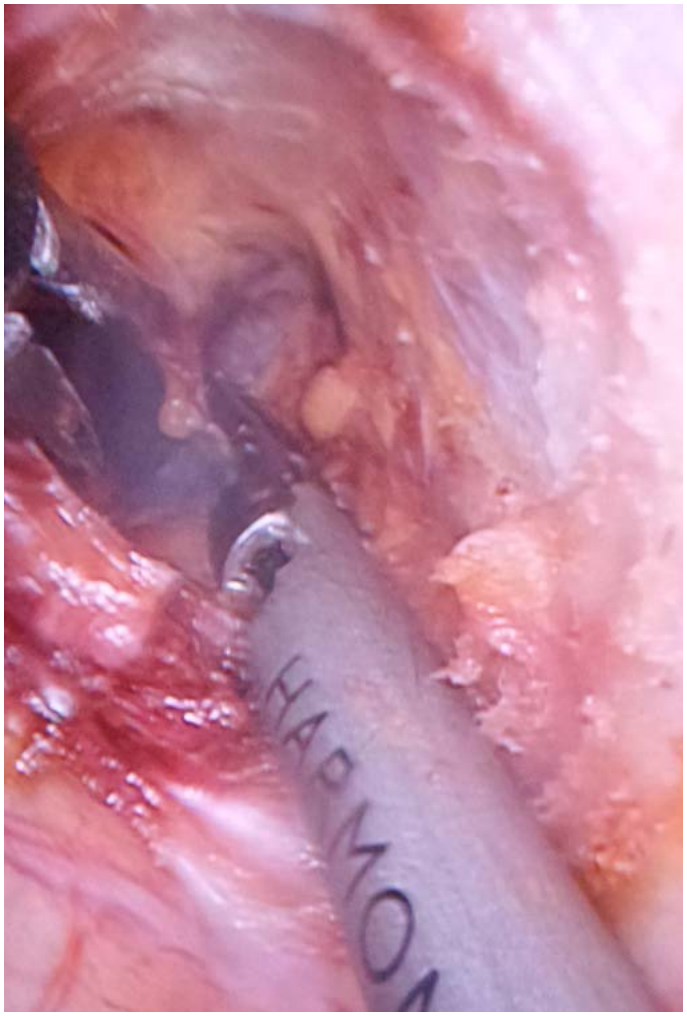

**Fig. 4.** Sub-sternal tunnel being formed laparoscopically.


**Fig. 5.** Colonic conduit taken out of the mini-celiotomy incision.

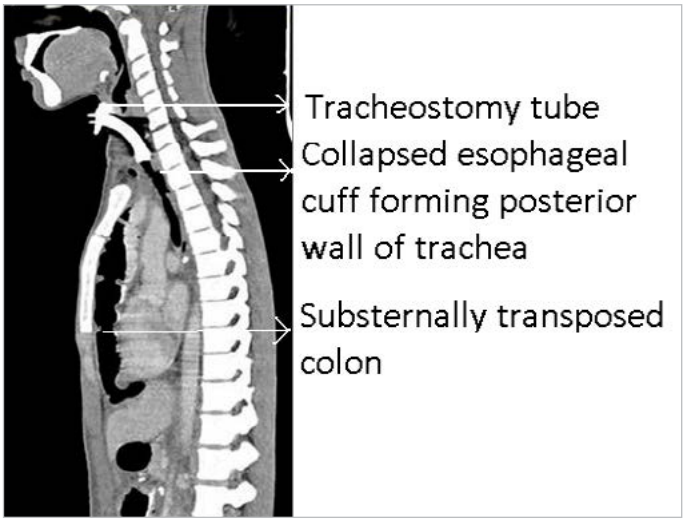


**Fig. 6.** Post operative computerized tomogram showing collapsed esophageal cuff forming the posterior wall of trachea at the trachea-esophageal fistula site. Transposed colon seen in the anterior mediastinum.

surrounding structures, therefore, it is unlikely to bulge into the tracheal lumen and act as a flap valve [9].

Loss of the esophagus is an unavoidable consequence of our technique and of other [5, 8]. Colonic transposition entails 3 anastomoses [10]. However, leak rate of esophago-colonic anastomosis is low (3.5%) and that of other two anastomoses is lower, hence, safer [6]. Colonic conduits tend to dilate over decades, which may have to be addressed later [6].

## CONCLUSION

Large, thoracic, cuff-induced TEF can be successfully repaired by MAS.

## REFERENCES

1. Sileika N., Jovaisas V., Jagelavicius Z., Janilionis R.: Management of acquired benign tracheoesophageal fistula in adults: a twelve-year experience. Lithuanian Surg, 2013; 12(4): 196–203.
2. Marulli G., Loizzi M., Cardillo G. et al.: Early and late outcome after surgical treatment of acquired non-malignant tracheo-oesophageal fistulae. Eur J Cardiothorac Surg, 2013; 43; e155–e161.
3. Muniappan A., Wain J.C., Wright C.D., Donahue D.M., Gaissert H., Lanuti M., Mathisen D.J.: Surgical treatment of nonmalignant tracheoesophageal fistula: a thirty-five year experience. Ann Thorac Surg, 2013; 95: 1141–1146.
4. Camargo J.J., Machuca T.N., Camargo S.M., Lobato V.F., Medina C.R.: Surgical treatment of benign tracheo-esophageal fistulas with tracheal resection and esophageal primary closure: is the muscle flap really necessary? Eur J Cardiothorac Surg, 2010; 37(3): 576–580.
5. Deshpande G., Samarasam I., Banerjee S., Gnanamuthu R.B., Chandran S., Mathew G.: Benign esophagorespiratory fistula: a case series and a novel technique of definitive management. Dis Esophagus, 2013; 26(2): 141–147.
6. Mathiesen D., Morse C.R.: Techniques of esophageal reconstruction. W: Shakleford's surgery of the alimentary tract. 7th ed., red: C.J. Yeo, J.B. Matthews, D.W. McFadden, Saunders, Philadelphia 2012, 518–536.
7. Gupta N.M., Gupta R.: Transhiatal esophageal resection for corrosive injury. Ann Surg, 2004; 239(3): 359–363.
8. Landreneau R.J., Hazelrigg S.R., Foley T.M., Johnson J.A., Curtis J.J.: Management of an extensive tracheoesophageal fistula by cervical esophageal exclusion. Chest, 1991; 99: 777–780.
9. Liebermann-Meffert D.: Human foregut anatomy, adjacent structures, and their relation to surgical approaches. W: Shakleford's surgery of the alimentary tract. 7th ed., red: C.J. Yeo, J.B. Matthews, D.W. McFadden, Saunders, Philadelphia 2012, 9–31.
10. Banerjee J.K., Saranga Bharathi R.: Minimally invasive substernal colonic transposition for corrosive strictures of upper aerodigestive tract. Dis Esophagus, 2017; 30(4): 1–11.

Word count: 1494 Page count: 4 Tables: – Figures: 6 References: 10

DOI: 10.5604/01.3001.0013.1026 Table of content: https://ppch.pl/issue/12160



Competing interests: The authors declare that they have no competing interests.



Corresponding author: Ramanathan Saranga Bharathi; Department of Gastrointestinal Surgery, Command Hospital Central Command, Lucknow, Uttar Pradesh, India; Phone: +91 8554061554; E-mail: sarangabharathi@gmail.com

Cite this article as: Banerjee J.K., Bharathi R.S.: Minimally Invasive Repair of Acquired Benign Thoracic Tracheo-Esophageal Fistula; Pol Przegl Chir 2019: 91 (5): 55–58