Mucocele of the sphenoid sinus: a rare entity to keep in mind

Mucocele zatoki klinowej – rzadka zmiana, o której warto pamiętać

Jihene Marrakchi, Maha Mejbri, Sana Mahfoudhi, Ghazi Besbes

Department of Oto-Rhino-Laryngology and Cervico-Facial Surgery of 'Rabta' Hospital Tunisia, Medicine Faculty, El Manar University, Tunisia; Head: Prof. Ghazi Besbes

Article history: Received: 07.05.2019 Accepted: 01.07.2019 Published: 09.07.2019

ABSTRACT: Isolated sphenoid sinus mucocele (SSM) is a rare entity that can result in serious sequelae if diagnosis and treatment are inappropriately delayed. Typically, mucoceles are asymptomatic, and they are accidentally identified after computed tomography scan or magnetic resonance imaging of the maxillofacial area performed for other pathological issues. We report a case of isolated SSM that presented only with a headache for over a year, and also review the literature regarding surgical management of such an entity.

KEYWORDS: endoscopic, imaging, mucocele, sphenoid sinus

STRESZCZENIE: Izolowane mucocele zatoki klinowej (SSM, ang. *sphenoid sinus mucocele*) to rzadka zmiana chorobowa, która – w przypadku zbyt późnego rozpoznania lub leczenia – wiąże się z poważnymi następstwami. Najczęściej jest ona bezobjawowa i wykrywana przypadkowo podczas tomografii komputerowej lub rezonansu magnetycznego okolicy szczękowo-twarzowej, wykonywanych z powodu innych zmian chorobowych. W niniejszej pracy opisano przypadek izolowanego śluzowiaka zatoki klinowej, którego jedynym objawem był utrzymujący się przez ponad rok ból głowy, a także dokonano przeglądu literatury na temat chirurgicznych metod leczenia mucocele.

SŁOWA KLUCZOWE: badania obrazowe, endoskopowy, mucocele, zatoka klinowa

ABBREVIATION

SSM–sphenoid sinus mucocele

INTRODUCTION

Mucoceles are benign, encapsulated, expansile, locally destructive masses within cavities, filled with mucous and lined by epithelium. Only 1-2% of all paranasal sinus mucoceles are located in the sphenoid sinus [1]. Typically, mucoceles are asymptomatic, and they are accidentally identified after computed tomography (CT) scan or magnetic resonance imaging (MRI) of the maxillofacial area performed for other pathologic issues. Symptoms, if present, are unspecified and result from mechanical pressure on neighboring structures and/or involvement of nerves in the inflammatory process. The most common symptoms include headache, visual loss and palsies of the III and VI cranial nerve [2]. We report a case of isolated SSM that only presented with headache for over a year, treated with the endoscopic technique.

CASE REPORT

A 69-year-old woman was examined by a neurologist for a headache lasting for over a year. The headache was intermitted, but recently it had become more severe in intensity. The neurological examination was normal as well as the ophthalmological examination. Nasal endoscopy did not reveal any anomalies. In order to exclude other symptomatic headaches, brain CT was performed and showed no intracerebral structural lesions. However, it revealed an expansile mass centered in the sphenoid sinus measuring 31x35 mm with erosion of the bony wall of over 7 mm in size (Fig. 1., 2.). The MRI study of the maxillofacial area visualized a cystic mass of the sphenoid sinus that had a high signal intensity on T2-weighted images and on T1-weighted images, without enhancement after injection of contrast medium and with extension to the left parapharyngeal space (Fig. 3., 4., 5.). Endoscopic marsupialization was realized under general anesthesia (Fig. 6.). A Merocel sponge was placed in the nasal cavity to avoid postoperative bleeding. That sponge was removed 48 hours after the surgical procedure. The patient has been completely relieved of her symptoms, without recurrence of the pathology for the last 24 months.

DOI: 10.5604/01.3001.0013.2796

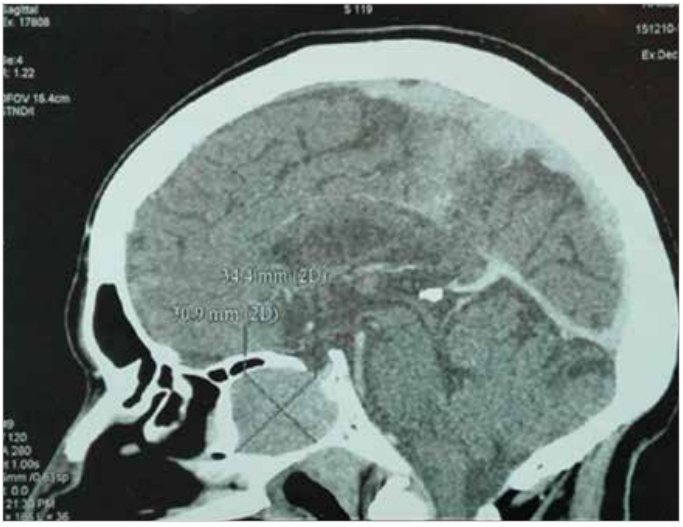

Fig. 1. CT examination (sagittal view) showing a mass centered in the sphenoid sinus, measuring 31x35 mm with erosion of the bony wall of over 7 mm.

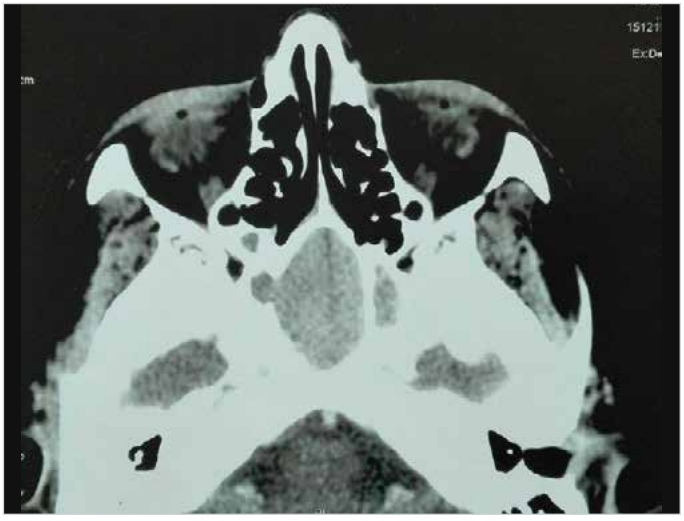

Fig. 2. CT examination (axial view) showing opacification and expansion of the sphenoid sinus.

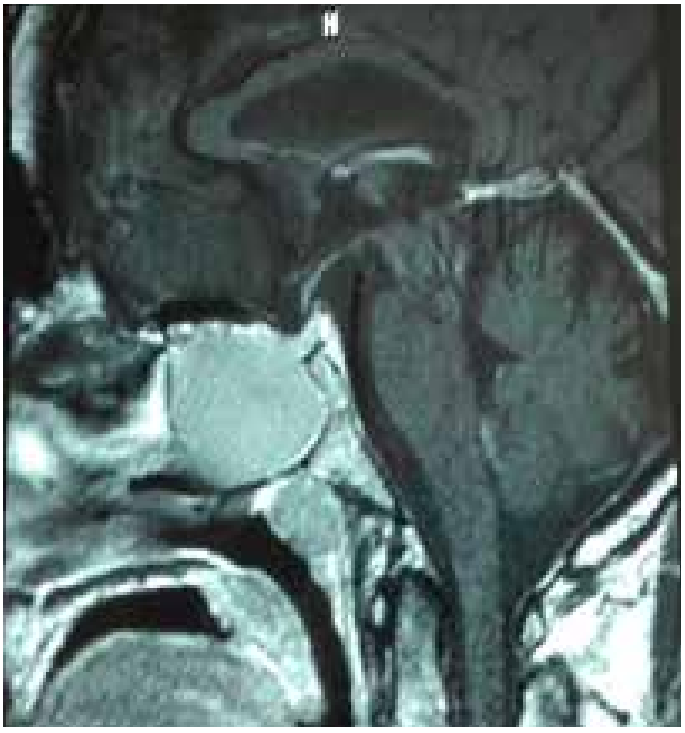

Fig. 3. and 4. MRI examination (sagittal and coronal views) on T1-weighted images showing a hyperintense sphenoid sinus mucocele.

DISCUSSION

Isolated SSM is a rare entity that can result in serious sequelae if diagnosis and treatment are inappropriately delayed. International literature assesses its incidence between 10% and 17% of sphenoid isolated benign lesions [3, 4]. The etiology is still unknown, but different infective or traumatic factors have been described as possible pathogenetic causes [5]. It commonly occurs in the third and fourth decades of life and is extremely rare in children [6]. Histologically, the mucocele consists of a thin layer of mucus-excreting cells and a large cavity of liquid or semisolid material. Although pathologically benign, SSM may involve vital structures, including the dura, pituitary gland, optic chiasm, cavernous sinus, pterygoid canal and nerve, internal carotid artery, and cranial nerves (III, IV, V, and VI) which are vulnerable to injury from the sphenoid lesion. Complications include permanent diplopia, blindness, meningitis, cavernous sinus thrombophlebitis, and the formation of carotid artery aneurysms [7]. Baseline symptoms depend on tumor dimensions; more frequently, they are characterized by localized headache, pain, and persistent sinusitis not responding to medical therapy. The most commonly reported symptoms when complication occurs are headache (89% of cases), decreased visual acuity (57%), oculomotor palsies (56%), exophthalmia (25%) and nasal symptoms (12%) [8]. Our patient suffered from a severe headache. It has been suggested that headache results from stretching of the dura over the planum sphenoidale. CT imaging of patients com-

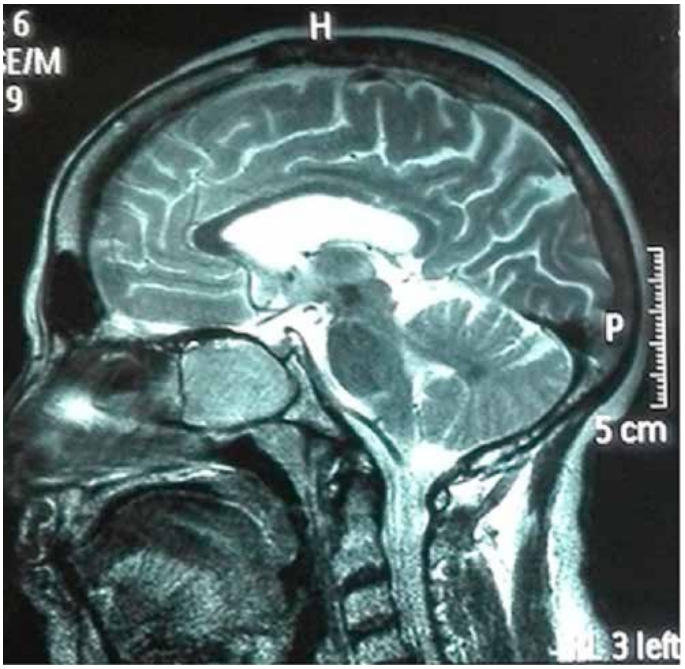

Fig. 5. Sagittal, T2-weighted, magnetic resonance imaging, showing a hyperintense sphenoid sinus mucocele.

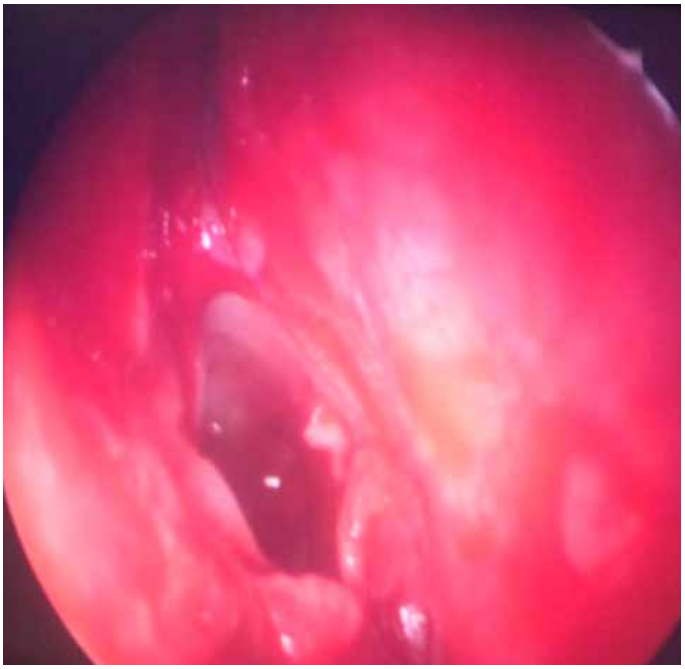

Fig. 6. Intraoperative image: sphenoid sinus after sphenoidotomy and marsupialization.

plaining of rebel headaches with normal neurological examination can clearly reveal a lesion. CT scan with bone algorithm is nowadays the elective x-ray imaging examination; MRI instead is a complementary study very useful in the cases with intracranial or intraorbital extension;

Mucoceles may show various imaging features, depending on their protein contents and possible superinfection. They often have low attenuation on CT, a low signal on T1-weighted MRI and a high signal on T2-weighted MRI, due to their high-water content [9]. There is usually no enhancement, or at most marginal enhancement, on CT and T1-weighted MRI, whereas many of the lesions in the differential diagnosis show contrast enhancement. Differential diagnosis has to be made with chronic sphenoid sinusitis, a fungus ball, benign neoplasms such as inverted papilloma, and rarely with malignant neoplasms [10]. The purpose of surgical treatment of the SSM is to create a large ostium that will allow drainage into the sphenoethmoidal recess. Surgical approach to sphenoid sinus mucocele could be either traditional or endoscopic. At present, the endoscopic approach represents the gold standard for sphenoid sinus mucocele treatment because it allows the best view of the sphenoid sinus and grants better restoration of the respiratory function and a higher compliance from the patient [11]. Endoscopic technique is described in many studies; it can be performed with a direct paraseptal approach with individuation of the natural sphenoid sinus ostium that is positioned 1 to 1.5 cm from the superior border of the choanae. The transethmoidal approach is described. In this case, the endoscope passes laterally to the medium turbinate bone, and an anterior and posterior ethmoidectomy is performed. Afterward, the superior turbinate is isolated, and the lower part is excised. Subsequently, inferiorly and medially, the natural sphenoid sinus ostium can be individuated, and it is then enlarged. The current surgical indication for mucocele treatment is marsupialization of the sphenoid sinus and drainage without excision of the whole mucosa [4,12]. This approach offers lower morbidity and complication rate and prevents recurrence. Postoperative follow-up for patients who underwent endoscopic surgery must involve periodic control of mucous membrane healing.

CONCLUSION

Mucocele involving the sphenoid sinus is a rare entity. Clinicians should suspect this entity if a patient presents with chronic, non-specific symptoms and/or with visual symptoms. The clinical examination may be normal. Imaging is crucial for diagnosis. Treatment is by endoscopic drainage, which is safe and effective in eradication of the disease.

References

1. Soon S., Lim C., Singh H., Sethi D.: Sphenoid sinus mucocele: 10 cases and literature review. J Laryngol Otol., 2010; 124(1): 44–47.
2. Friedman A., Batra P.S., Fakhri S.: Isolated sphenoid sinus disease: etiology and management. Otolaryngol Head and Neck Surg., 2005; 133: 544–550.
3. Wang Z., Kanoh N., Dai C.: Isolated sinus disease: an analysis of 122 cases. Ann Otol Rhinol., 2002; 111: 323–327.
4. Giovannetti F., Filiaci F., Ramieri V., Ungari C.: Isolated sphenoid sinus mucocele: etiology and management. J Craniofac Surg., 2008; 19(5): 1381–1384.
5. Kosling S., Hinter M., Brandt S., Schulz Th., Bloching M.: Mucocele of the sphenoid sinus. Eur J Radiol., 2004; 51: 1–5.
6. Kataria R., Gupta S., Chopra S., Bagaria H., Sinha V.: Mucocele of the sphenoid sinus: A rare cause of reversible third nerve palsy. Ann Indian Acad Neurol. 2012; 15(2): 158.

7. Celenk F., Gulsen S., Gonuldas B., Baysal E., Durucu C., Kanlikama M.: Isolated sphenoid sinus disease: an overlooked cause of headache. J Craniomaxillofac Surg., 2015; 43(9): 1914–1917.
8. Mohebbi A., Jahandideh H., Harandi A.A.: Sphenoid sinus mucocele as a cause of isolated pupil-sparing oculomotor nerve palsy mimicking diabetic ophthalmoplegia. Ear Nose Throat J., 2013; 92(12): 563.
9. Darouassi Y., Righini C.A., Reyt E.: Mucoceles of the sphenoidal sinus: a report of four cases and review of the literature. B-ENT, 2005; 2013: 181–185.
10. Lee K.E., Kim K.S.: Headache induced by the sphenoid sinus mucocele. Braz J Otorhinolaryngol., 2015; 81(1): 113–114.
11. Mayne M.D., Moya-Plana A., Malinvaud D., Laccourreye O., Bonfils P.: Sinus mucocele: natural history and long-term recurrence rate. Eur Ann Otorhinolaryngol Head Neck Dis, 2012; 129(3): 125–130.
12. Castelnuovo P., Pagella F., Semino L., De Bernardi F., Delù G.: Endoscopic treatment of the isolated sphenoid sinus lesions. Eur Arch Otorhinolaryngol., 2005; 262(2): 142–147.

Word count: 1250 Tables: – Figures: 6 References: 12

DOI: 10.5604/01.3001.0013.2796 Table of content: https://otorhinolaryngologypl.com/issue/12343

Competing interests: The authors declare that they have no competing interests.

Corresponding author: Jihene Marrakchi, Department of Oto-Rhino-Laryngology and Cervico-Facial Surgery of 'Rabta' Hospital Tunisia, Medicine Faculty, El Manar University, Tunisia; E-mail: jihenemarrakchi@yahoo.fr

Cite this article as: Marrakchi J., Mejbri M., Mahfoudhi S., Besbes G.: Mucocele of the sphenoid sinus: a rare entity to keep in mind; Pol Otorhino Rev 2019: 8(3): 31-34