INDEX COPERNICUS INTERNATIONAL

ARTYKUŁ ORYGINALNY / ORIGINAL RESEARCH ARTICLE

Treatment of deafness using bone anchored hearing device (BAHD)

Leczenie głuchot z zastosowaniem implantów na przewodnictwo kostne

Wiesław Konopka[1,2], Małgorzata Strużycka[1], Małgorzata Śmiechura[1]

[1]Department of Otolaryngology, Polish Mother's Memorial Hospital Research Institute
[2]Division of Pediatric Education, Medical University of Łódź, Head of the Department and the Division: Prof. Wiesław Konopka, MD, PhD.

Article history: Received: 22.01.2016 Accepted: 20.02.2016 Published: 30.03.2016

ABSTRACT: People with hearing loss or deafness in the course of chronic middle ear, external or birth defects, which cannot wear conventional hearing aids or not treatable surgery are candidates for the implant to the bone conduction. The second category candidates are patients with „one-sided" deafness. Currently available to patients and physicians are many technical solutions that can be successfully used in the majority of treated giving them the opportunity satisfactory hearing. A special group of patients are children who can be the use of BAHD (Bone Anchored Hearing Device) from 4–5 years of age. The introduction of recently BAHD of wireless accessories also allows patients to wirelessly and connect to other devices. In contrast, solutions to hide the implant under the skin deprives treated stigma and is comfortable in everyday use. The aim of the study is to present the most widely used solutions using Bone Anchored Hearing Device in the rehabilitation of hearing and present their own experiences.

KEYWORDS: Bone Anchored Hearing Device

STRESZCZENIE: Osoby z niedosłuchem – lub głuchotą w przebiegu przewlekłych chorób ucha środkowego, zewnętrznego czy wad wrodzonych – które nie mogą nosić klasycznych aparatów słuchowych, czy też nie poddają się leczeniu chirurgicznemu są kandydatami do wszczepienia implantu na przewodnictwo kostne. Druga kategoria kandydatów to chorzy z głuchotą „jednostronną". Obecnie pacjenci i lekarze mają do dyspozycji wiele rozwiązań technicznych, które z powodzeniem mogą być zastosowane u większości leczonych, dając im możliwość satysfakcjonującego słyszenia. Szczególną grupą chorych są dzieci, u których zastosowanie aparatów zakotwiczonych w kości możliwe jest już od 4–5 roku życia. Wprowadzenie implantów zakotwiczonych w kości z akcesoriami bezprzewodowymi pozwala pacjentom dodatkowo na bezprzewodowe korzystanie i łączenie się z innymi urządzeniami. Rozwiązania z magnetycznym wspornikiem umożliwiają schowanie implantu pod skórę, pozbawiają leczonych stygmatyzacji i są wygodne w codziennym użytkowaniu.

SŁOWA KLUCZOWE: BAHD, dzieci

INTRODUCTION

Hearing aids in hearing-impaired patients differ in the method for the delivery of sound waves to the cochlea. The majority of devices are air conduction (AC) devices, while another group consists of bone conduction (BC) devices. Despite the fact that bone conduction devices are used in a relatively small population of patients, they are often the only feasible solution available to these patients. Conventional bone conduction devices (BCDs) are affixed by means of various types of bands or eyeglass frames, which markedly restricts their applicability. BCDs are used in rehabilitation of conductive hearing losses, mixed hearing losses as well as in single-sided deafness.

Bone anchored hearing devices (BAHDs) are bone conduction devices anchored within the bone structure. In contrast to conventional bone conduction devices, BAHDs are affixed to a titanium implant anchored within the temporal bone.

Professor Branemark's discovery of the phenomenon of osseointegration, i.e. permanent integration of living bone tissue with titanium oxides on the surface of implants, made in the 1950s, triggered dynamic advances in implantation techniques in different medical areas. In 1965, Branemark et al. (1) presented a report on successful osseointegration in dental surgery and facial skeleton reconstruction. In 1977, in Goethenburg, Tjellström et al. performed the first implantation of a titanium implant to which a bone conduction hearing aid was affixed. This type of devices have been available on the market since 1987. Transcutaneous BAHD systems make use of the solid fixation of titanium implant to the bone for direct propagation of sounds to the inner ear via the skull bone, without impedance contributions from skin and subcutaneous tissues. This solution eliminates the skin compression problems while additionally maintaining high-frequency hearing. Today, BAHDs are an established and widely used method for the treatment of hearing loss or deafness. In 1977, prof. Vanecloo pioneered the use of BAHDs in single-sided deafness.

The goal of this article is to present the most common hearing rehabilitation solutions involving bone anchored hearing aids.

Currently, the main classification of bone conduction devices is that into skin-drive BCDs that conduct the sound through the skin tissue and direct-drive BCDs that conduct the sound directly via the bones.

The first category includes conventional BCDs (headbands or eyeglass frames as well as passive transcutaneous BCDs, i.e. devices featuring subcutaneous magnet implants anchored within the bone (Sophono®, Baha®Attract). The other category includes transcutaneous bone anchored devices (Baha®, Ponto) as well as active transcutaneous BCDS (Bonebridge® and BCI (Bone-conduction implant)).

Indication for BAHD devices are similar in pediatric as well as in adult patients. In children, the use is usually limited by age and skull bone thickness.

The 2011 consensus position of the Polish Society of Otorhinolaryngologists and Head and Neck Surgeons on the use of bone anchored hearing aid systems recommends that the implants are used after the age of 3 (2). In our opinion, the optimum age is above 5 years, as recommended in the US and Canada.

Most common indications include congenital and acquired external auditory canal atresias, microtia, genetic defect syndromes (Treacher-Collins syndrome, etc.), bilateral conductive or mixed hearing losses in patients incapable of using classic air conduction devices (chronically refractory exudative inflammations of the middle ear, chronic skin inflammations within the external auditory canals (e.g. eczemas, radical ear surgeries), single-sided deafness, deafness secondary to resection of the 8th cranial nerve tumor.

Audiological results: conductive hearing loss – average bone conduction in the affected ear lower or equal to 45-55 dB HL (depending on the model) at 500 Hz, 1 kHz, 2 kHz and 3 kHz, speech recognition in single-syllable test of ≥ 60%, symmetrical bone conduction in case of bilateral implantation. Mixed hearing loss cochlear reserve ≥ 30 dB, sensorineural component < 65 dB.

Single-sided deafness: normal hearing in one ear (AC PTA ≤ 20 dB HL – average for 0.5, 1, 2, and 3 kHz) and deep hearing loss in contralateral ear.

Studies show that in the case of conduction hearing loss, patients with cochlear reserve of more than 30 dB benefit more from BAHDs as compared to ACDs (3). The larger the cochlear reserve, the greater the benefit of BAHDs for patients.

In pediatric patients, early stimulation of the hearing organ with sound is very important; when anatomical conditions prevent surgery, this may be achieved by means of a headband device.

Preoperative use of headband-worn BAHDs is a standard of treatment that demonstrates the patient the improvement of hearing to be achieved after surgery. In addition, the efficacy and benefits of the use of the devices may be assessed by means of behavioral observational audiometry (BOA) in infants, visual reinforcement audiometry (VRA) in children between 6 months and 2-3 years of age or e.g. play audiometry in older children.

Due to the elimination of the impact of impedance of skin and subcutaneous tissue, the improvement in hearing after surgical treatment is usually higher than in the case of headband devices. Verstraeten demonstrated that the sensitivity of transcutaneous hearing in the range of 1-4 kHz is 8-20 dB worse in headband BCDs as compared to transcutaneous BAHDs (4).

Transcutaneous bone anchored hearing aids in which the vibrations are transmitted directly from the support and the implant via the bone into the inner ear are currently available as two types of systems: Baha® and Ponto. Solutions offered by Cochlear Baha include Baha Bp100®, Baha 4®, and Baha 5®. Oti-

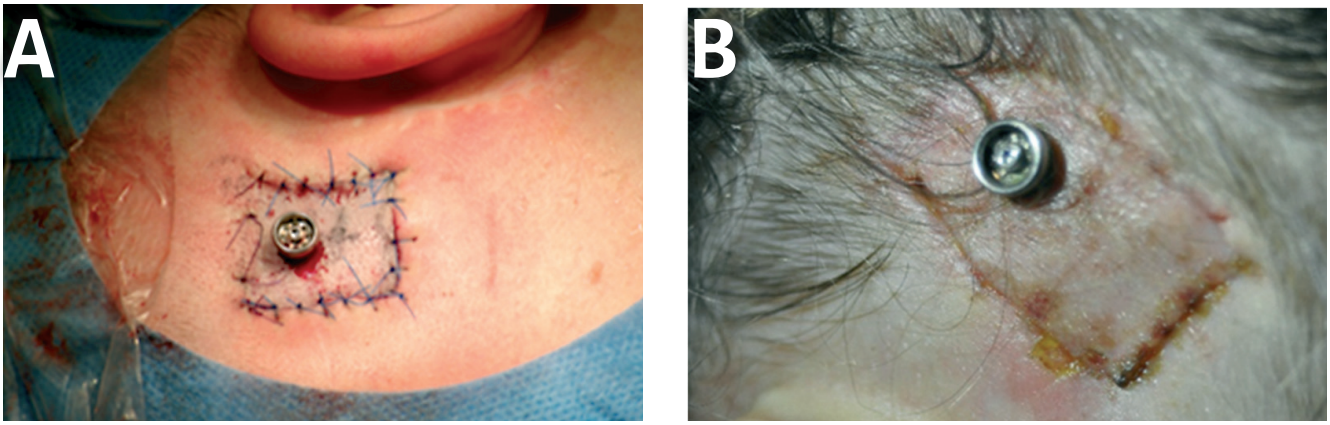

Fig. 1. Surgical technique involving the use of a dermatome: A – immediately after surgery; B – 14 days after the surgery; slight inflammation (Holgers' grade 1) can be seen

con Medical products include Ponto, Ponto Pro, and Ponto Pro Power. Audiometric outcomes obtained with these devices are similar and very good.

Disadvantages of transdermal direct-drive BCDs include the need of everyday maintenance care, skin complications manifesting as inflammatory reactions or cicatrization of the abutment. In addition, a risk of implant loss exists, either spontaneous due to insufficient osseointegration, or following an injury (5, 6).

The surgical procedure of BAHD implantation evolved from a two-stage to a single-stage procedure using a dermatome or linear incision; however, it was constantly based on a abutment extending to the outside surface of head skin to support the processor.

In the classic procedure using the dermatome (Fig. 1), local skin complications are commonly observed around the support abutment; these complications are assessed using a four-point Holgers scale.

Novel technical solution introduced to both systems were related to implant design so as to ensure its better osseointegration and stability. In addition, technical advances related to the shape of the support abutment or to the abutment being covered with hydroxyapatite to reduce skin reactions (7).

In case of linear incision technique (Fig. 2) and hydroxyapatite-covered implants, the skin reactions are markedly less pronounced and less common; however, cases of serious skin reactions or cicatrization of the support abutment are still encountered.

A very important aspect of the trancutaneous technique consists in stigmatization of the patient, particularly in the group

Fig. 2. Operating technique involving linear incision

of adolescents and adults who do not accept such solutions for aesthetic reasons.

These problems were eliminated by the technique including placement of magnets under the skin to support BAHD devices; this technique was introduced by Sophono, and later on also by Cochlear.

The technique involving the concealment of magnets started from the novel solution presented by Prof. Ralf Siegert in 2004, consisting in subcutaneous placement of two connected magnets being fixed using titanium screws. Only as late as in 2013 Cochlear presented their own proprietary solution consisting in the magnetic part being placed subcutaneously on an implant being screwed-in the temporal bone as in direct-drive BCDs.

Fig. 3. Status post-BAHA Connect implantation using linear incision approach (24 months). Holgers' grade IV inflammation and trend towards abutment cicatrization are visible.

Fig. 4. Status immediately after abutment removal and wound closure

Fig. 5. BAHA Attract support system implanted – 4 months after the procedure.

Fig. 6. Speech processor mounted to the magnetic BAHA Attract support

The use of magnets of large areas and different strengths as well as specially designed Baha SoftWear pads in case of Baha Attract devices allowed for elimination of undesirable skin compression.

In the group of patients subjected to linear incision surgery to implant a Cochlear Baha Connect device, the support abutment extending to the surface of the skin can be replaced by an invisible magnetic abutment which is particularly useful in patients prone to support cicatrization or serious inflammatory reactions of skin surrounding the abutment.

In the Department of Otolaryngology of Polish Mother's Memorial Hospital Research Institute, such procedures were performed in three patients to yield good functional and aesthetic effects (Fig. 3, 4, 5, 6).

In addition, continuous technological advances introduced to both Baha® and Ponto systems included upgrades and miniaturization of the processor, improved aesthetics as in the case of BAHD 5, and the possibility of using peripherals for remote control of the processor or for integration with e.g. iPod devices, which is particularly useful for younger users.

Both solutions provided similar level of hearing improvement. In their report concerning the use of Sophono devices in a quite diverse group of 20 patients aged 6 through 60, Siegert and Kanderske (9) declared hearing improvements of up to 28 dB while Iseri (10) reported hearing improvements of up to 19 dB in a group of 9 patients aged 5 through 65 using the Baha Attract system. No complications were observed in both studies other than reduction of the external magnet strength being required in some patients.

The comparison of Sophono Alpha 1 with transcutaneous BAHD as carried out by Hol et al. (11) demonstrated slightly better hearing in free acoustic field in patients with BAHDs. The author additionally highlighted the advantages of Sophono devices including the absence of skin reactions or the impossibility of implant loss. The reports by Sylvester, Magliulo, and O'Niel (12, 13, 14) are indicative of marked improvement of hearing in the range of 21 to 30 dB with simultaneous improvement in speech recognition while using the Sophono devices. All these authors highlight the benefits of magnetic support systems in patients with skin problems.

OWN EXPERIENCE OF AUTHORS

In the own material of the Department of Otolaryngology of Polish Mother's Memorial Hospital Research Institute, a total of 52 BAHD implants were placed in a group of 41 patients (20 boys and 21 girls) aged 5 through 18 years between 2011 and 2015. Bilateral BAHD implantations were performed in 15 patients.

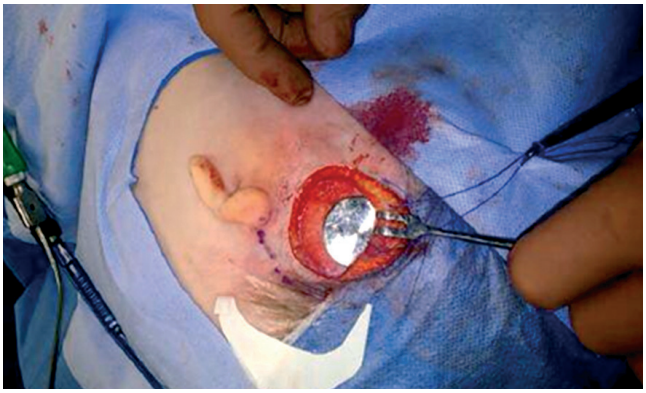

Fig. 7. Surgical technique for the placement of BAHA Attract system – magnetic support can be seen within the surgical field

Fig. 8. Speech processor mounted to the magnet

The indications included:

- bilateral microtia and atresia (8 patients, 14 implants);
- Treacher-Collins syndrome (6 patients, 10 implants);
- conditions after ear surgeries in the course of chronic inflammation (4 patients, 5 implants);
- unilateral microtia and atresia (13 patients);
- single-sided deafness (9 patients),
- Gorlin-Goltz syndrome (1 patient, 2 implants);
- branchio-oto-renal syndrome (1 patient).

A total of 27 transdermal Connect-type transdermal devices were implanted in this group, including 9 procedures performed using the dermatome and 18 linear incision procedures. The remaining 25 implants were the magnetic subcutaneous Baha

Attract devices. Depending on the anatomical conditions, i.e. the bone thickness, 3-mm long implants were used in 5 cases and 4-mm long implants were used in the remaining 47 cases.

OSSEOINTEGRATION ASSESSMENTS

In case of direct-drive BCDs, implant stability measurements are required to monitor the osseointegration process.

In our own assessments of implant stability as the function of bone thickness, we observed that implants were significantly more stable in patients with bone thickness of 4-5 millimeters. Bone thickness is also related to the age of the patients. In our study population, intraoperative implant stability in children below the age of 10 was lower than in the older patients. The baseline implant stability quotients should guide the decisions to connect the processors. In our study material, processors were connected after the average of 7.7 weeks from surgery, with the minimum time of 2 weeks and maximum time of 8 weeks. The decisions were guided by the child's age, bone thickness, ISQ measurements and inflammatory reactions of surrounding tissues (15). In case of Attract-type implants, only intraoperative stability measurements are possible.

No intraoperative complications were observed. Slight postoperative inflammation, Holgers grade 1/2, was observed in 4 patients. In three patients, support abutment was replaced by magnetic support of the Baha Attract type due to abutment cicatrization. The replacement was possible owing to the previous use of linear incision. No replacement would be possible if the dermatome was used. Functional outcomes of bone conduction hearing aids, both passive transcutaneous BCDs (Sophono®, Baha®Attract) or transcutaneous bone anchored hearing devices (Baha®, Ponto) can be predicted due to the possibility of the hearing aid being placed on a headband.

Currently, only the Attract-type magnets (Fig. 4) are implanted at the Department of Otolaryngology of the Polish Mother's Memorial Hospital Research Institute.

SUMMARY

The use of bone anchored hearing aids in single-sided as well as double-sided deafness is effective and markedly improves the quality of life of the patients.

Implants featuring magnetic support ensure good hearing quality while providing the comfort of use and eliminating patient stigmatization.

Patient's decision regarding the implant placement must be well-informed and preceded by a period of hearing aid being worn on a headband.

References

1. Branemark P.I., Adell R., Breine U., Hansson B.O., Lindström J., Ohlsson A.: Intra-osseous anchorage of dental prostheses. I. Experimental studies. Scand. J Plast. Reconstr. Surg. 1969; 3 (2): 81–100.
2. Durko T., Jurkiewicz D., Kantor I., Klatka J., Kuczkowski J., Niemczyk K., Rogowski M., Dobrzyński P., Wiskirska-Woźnica B.: Konsensus na temat leczenia niedosłuchów przy zastosowaniu implantów zakotwiczonych w kości, Polski Przegląd Otorynolaryngologiczny, Volume 1, January–March 2012, 47–50.
3. Håkansson B., Tjellström A., Rosenhall U.: Hearing thresholds with direct bone conduction versus conventional bone conduction. Scand. Audiol. 1984; 13: 3–13.
4. Verstraeten N., Zarowski A.J., Somers T., Riff D., Offeciers E.F.: Comparison of the audiologic results obtained with the bone-anchored hearing aid attached to the headband, the testband, and to the "snap" abutment. Otol. Neurotol. 2009; 30 (1): 70–75.
5. Dun C.A.J., Faber H.T.F., de Wolf M.J.F., Mylanus E.A.M., Cremers C.W.R.J., Hol M.K.S:. Assessment of more than 1,000 implanted percutaneous bone conduction devices: skin reactions and implant survival. Otol. Neurotol. 2012; 33: 192–198.
6. Wallberg E., Granström G., Tjellström A., Stahlfors J.: Implant survival rate in bone-anchored hearing aid users: long-term results. J Laryngol. Otol. 2011; 125 (11): 1131–1135.
7. Mierzwiński J., Konopka W., Grela M., Łaz P., Śmiechura M., Strużycka M., Kuśmierczyk J.: Evaluation of bone conduction implant stability and soft tissue status in children in relation to age, bone thickness, and sound processor loading time. Otology& Neurology, 2015. 36, 7, 1209–1215.
8. Siegert R.: Partially implantable bone conduction hearing aids without a percutaneous abutment (Otomag): technique and preliminary clinical results. Adv. Otorhinolaryngol. 2011; 71: 41–46.
9. Siegert R., Kanderske J.: A new semi-implantable transcutaneous bone conduction device: clinical, surgical, and audiologic outcomes in patients with congenital ear canal atresia. Otol. Neurotol. 2013; 34: 927–934.
10. Işeri M., Orhan K.S., Kara A. et al.: A new transcutaneous bone anchored hearing device – the Baha® Attract System: the first experience in Turkey. Kulak Burun Bogaz Ihtis Derg. 2014; 24 (2): 59–64.
11. Hol M.K.S., Nelissen R.C., Agterberg M.J.H., Cremers C.W.R.J., Snik A.F.M.: Comparison between a new implantable transcutaneous bone conductor and percutaneous bone-conduction hearing implant. Otol. Neurotol. 2013; 34: 1071–1075.

12. Sylvester D.C., Gardner R., Reilly P.G., Rankin K., Raine C.H.: Audiologic and surgical outcomes of a novel, nonpercutaneous, bone conducting hearing implant. Otol. Neurotol. 2013; 34: 922–926.
13. Magliulo G., Turchetta R., Iannella G., di Masino R.V., de Vincentiis M.: Sophono Alpha System and subtotal petrosectomy with external auditory canal blind sac closure. Eur. Arch. Otorhinolaryngol. Epub June 8, 2014.
14. O'Niel M.B., Runge C.L., Friedland D.R., Kerschner J.E.: Patient outcomes in magnet-based implantable auditory assist devices. JAMA Otolaryngol Head Neck Surg. Epub April 24, 2014.
15. Konopka W., Mierzwiński J., Strużycka M., Śmiechura M., Popaś R., Drela M.: Ocena stabilności implantu zakotwiczonego w kości BAHA u dzieci. Otorynolaryngologia, 2014, 13, 2, 100–104.

Word count: 2400 Tables: – Figures: 8 References: 15

Access the article online: DOI: 10.5604/20845308.1196078 Full-text PDF: www.otorhinolaryngologypl.com/fulltxt.php?ICID=1196078

Corresponding author: Prof. dr hab. med. Wiesław Konopka, ul. Rzgowska 281/289, 93-338 Łódź, e-mail: wieslaw.konopka@umed.lodz.pl

Competing interests: The authors declare that they have no competing interests.

Cite this article as: Konopka W., Strużycka M., Śmiechura M.: Treatment of deafness using bone anchored hearing device (BAHD): Pol Otorhino Rev 2016; 5(1): 11-17