INDEX COPERNICUS INTERNATIONAL

# Stoppa method – forgotten surgery

Andrzej Ratajczak, Małgorzata Lange-Ratajczak, Kinga Zastawna

General And Endocrine Surgery And Gastroenterological Oncology Department; Prof. dr hab. Tomasz Banasiewicz

Historia artykułu: Otrzymano: 20.07.2016 Zaakceptowano: 17.09.2016 Opublikowano: 31.10.2017

**BSTRACT:**

**Background:** Treatment of recurrent inguinal hernias undoubtedly creates problems. Causes of the mentioned are changed anatomy after multiple medical procedures, laconic documentation or loss of faith in surgeons' skills and effectiveness. In accordance with the recommendation of the European Hernia Society, recurrent hernias operated on via anterior approach, which are common in Poland, due to low popularity of laparoscopic methods, should be addressed via posterior approach. It is quite a challenge even for experienced surgeons, who often operate on hernia. Basing on our own experience we would like to remind the forgotten in Poland Stoppa surgery, which gives, according to the method's author, less than 1% of recurrences.

**Material and method:** Our humble material which this paper is based on consists of seven men who were operated on via the above method in the past three years in Department of General, Endocrinological Surgery and Gastroenterological Oncology. The only exceptions are the use of a polypropylene mesh instead of polyester and the additional use of histoacrylic glue to mount a mesh in three patients. In order to reach optimal hemostasis, we decided not to mount a Redon drainage tube above the mesh.

**Results:** No one of the patients who underwent the procedure had a relapse of hernia. Complications that we describe in this paper did not require a surgical intervention and did not have a negative effect on quality of life of our patients.

**Conclusion:** Many years of worldwide using this method proved that it is safe for the patient and prevents recurrence of inguinal hernia. Therefore, according to the authors it should be popularized in Poland.

**KEYWORDS:** reccurent inguinal hernia, Stoppa surgery, hernia mesh, posterior preperitoneal approach, herniology

## INTRODUCTION

The problem with treatment of recurrent inguinal hernias is still present. It particularly relates to patients who experienced multiple treatment failures. These patients, after multiple medical procedures performed by different doctors and via various methods, are often sent to other medical facilities with incomplete or laconic documentation. No one is eager to correct the mistakes of others, thus subsequent surgeons do not want to undertake the treatment. Surgeons who have already operated on a patient 2 or 3 times lose faith in their skills and effectiveness of subsequent attempts. The loss of faith works both ways, the patient does not want to return to the doctor whose previous treatment attempts ended in failure. This situation brings difficult patients to surgeons who operate on hernia and the medical facilities where they work. In accordance with the recommendation of the European Hernia Society, recurrent hernias operated on via anterior approach, which are common in Poland (above 90%) due to low popularity of laparoscopic methods, should be addressed via posterior approach (1). Laparoscopic, and therefore posterior, preperitoneal repair of big, repeatedly recurring hernias, especially those with expected adhesions between a sac and a mesh placed anteriorly, is quite a challenge even for experienced surgeons. In exactly such cases a somewhat forgotten and currently very rarely performed in Poland Stoppa surgery can be used. The knowledge of this surgery among surgeons is scarce, and even among colleagues who regularly participate in meetings of hernia surgeons in Poland under the Polish Hernia Club or Hernia Section of the Association of Polish Surgeons it is not common. That is why in this paper we will try to remind the readers of it.

## TECHNIQUE OF THE PROCEDURE

Open fascia through a midline incision from the navel to the symphysis pubis, while paying close attention to leave peritoneum undamaged. Enter the rectus abdominis retromascular space from both sides while delicately dissecting in the avascular space. By going downward the retropubic space, push back the urinary bladder and get behind pubic symphysis to the prostatic cavity. By extending the dissection laterally, you will reach spermatic cords, on which you can apply extraction and remove peritoneum. You will reach the hernial sac or actually its neck - in case of direct inguinal hernia sac, it will be located medially to clearly visible from behind inferior epigastric vessels, laterally oblique to them it is connected to the elements of the funicle. Place the dissected sac inside the stomach without opening it. If the sac is really long, it can be shortened by carefully stitching up peritoneum to keep a barrier between the mesh and intestines. If there are relapses, e.g. after Lichtenstein surgery or another method utilizing mesh implantation, the sac might be strongly fused with the mesh, that is why this stage of the procedure might cause difficulties. After dealing with the sac, continue the dissection in Bogros space until you reach external iliac vessels and go below them (attention! gently and under visual control - technically not difficult, but it is the most dangerous moment of the procedure) and laterally to the iliopsoas muscle. Repeat the same on the other side. Dissecting upwards to anterior superior iliac spines and obtaining adequate supraperitoneal space require to cut linea semilunaris and arcuate line. After finishing, there will be a huge dissected space above peritoneum ready to place the mesh in. The mesh should be very big, but individually selected. Rene Stoppa recommended a mesh with the width equal to a distance between anterior superior iliac spines and its height defined by a distance from the pubic symphysis to the navel (2). The authors' experience shows that usually a 25x15-cm mesh is sufficient, although sometimes it must be bigger. The mesh should have the shape of a chevron, a very flattened and inverted letter V. Long forceps help to set the mesh in correct position, they are used to grasp the bottom and lateral sides of the mesh and insert it as far as possible under the abdominal wall and behind the pubic symphysis. At the same time an assis-


DOI: 10.5604/01.3001.0010.5410

tant pulls the peritoneum cephalad upwards. It helps if a patient is in the Trendelenburg position, the mesh should be carefully spread across the entire previously prepared space, therefore it is needed to pay close attention so the mesh will not roll up during removal of the forceps. In their earlier works, Stoppa and Rives recommended to incise the mesh to let through spermatic cords (3). After refining the method, they decided not to do it. Now they recommend to completely remove the peritoneum from the whole cord and place the mesh behind it. The mesh does not need to be mounted, because after releasing the pulled back peritoneum it is pressed from behind to the lower anterior abdominal wall. The only mounting point is one suture between the upper edge of the mesh (apex of the chevron) and umbilical ring. The procedure ends after placing above the mesh draining tubes and layer suturing. (Fig.1)

## OUR STUDY MATERIAL

Our humble material which this paper is based on consists of seven men who were operated on via the above method in the past three years.

Three patients had repeatedly recurrent inguinal and unilateral scrotal hernias, whereas two patients had bilateral hernias. "The record" was held by a patient who had a seventh relapse on the right side and sixth on the left. Two patients with bilateral idiopathic scrotal hernias were also qualified to the described method. No one of the patients who underwent the procedure had a relapse of hernia. Complications observed in one of the patients included a large hematoma, covering the pubic symphysis and subcutaneous tissue of internal surface of the thighs on both sides. After two weeks, the hematoma was idiopathically absorbed and did not require a surgical intervention. In an ultrasound scan of another patient, there was an encapsulated 6 x 4-cm seroma between the internal surface of the mesh and peritoneum. The size of the seroma has not changed for a year and the patient does not feel any discomfort associated with it. Also in one patient, who was operated on due to a fifth relapse and had a completely destroyed posterior wall of the inguinal canal, there was a visible protrusion of the groin area, but without a relapse, confirmed in an ultrasound scan showing the whole pectineal hiatus, which was pushed out by viscera located at the back. The protrusion has not grown for one and a half year, it also does not grow during activity of the abdominal press. The last patient was operated on a month ago, we are aware of incomplete data due to a small number of operatees and a short monitoring period, consequently it is difficult for us to draw far-reaching conclusions based only on our clinical material.

The authors of this paper try to act according to the above scheme of surgery. The only exceptions are the use of a polypropylene mesh instead of polyester and the additional use of histoacrylic glue to mount a mesh in three patients. In order to reach optimal hemostasis, and it is not difficult while dissecting in avascular anatomical space, we decided not to mount a Redon drainage tube above the mesh.

General anesthesia was used on patients operated on by us. To patients with contraindications to anesthesia, as we know from literature, subarachnoid or epidural anesthesia might be applied during the procedure, and Wantz even recommends local anesthesia for his unilateral repair (4).

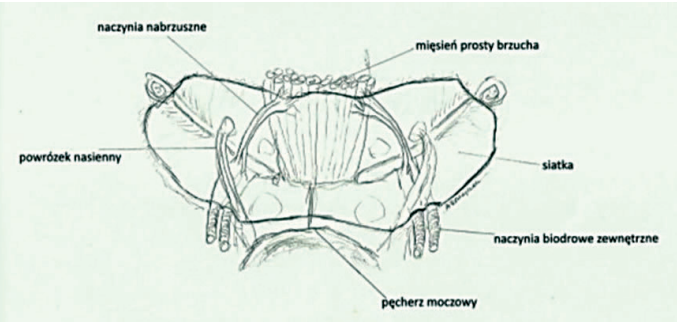


**Fig. 1.** Striped grid - Rearview

## DISCUSSION

The concept of posterior preperitoneal approach was not invented by Stoppa. He, together with Rives, based the development of this surgery method on the works of his mentor, a French anatomist and surgeon Fruchard, the creator of the concept of musculopectineal hiatus, which includes rings of all inguinal and femoral hernias. Stoppa had a correct assumption that an active abdominal press generates intra-abdominal pressure which, in accordance with the Pascal law, forces peritoneum outside the hernia sac through loci minoris resistentie. He decided not to focus on repairing the ring of hernia, but to create an artificial barrier in a form of implanted biomaterial, which placed anteriorly to the peritoneum and posteriorly to the ring of hernia would prevent a protrusion of the sac (5,6). With regard to posterior preperitoneal approach, it is difficult to argue for precedence because Nyhus was using it in his surgeries, although without an implant, nevertheless Rene Stoppa conducted first surgeries in the late 1960s (7). Among newer preperitoneal methods, there is surgery quite popular in USA described by Robert Kugel, Wantz (similar to the Stoppa surgery but with mesh implantation on one side only), further modifications of hernia repairs performed by Gilbert, or minimally invasive open transinguinal preperitoneal repair with implantation of a semi-rigid implant (8,9). It is also undisputed that the Stoppa surgery has paved the way for recently popular laparoscopic TAPP and TEP hernia repairs based on the same principle.

An undoubted advantage of the described technique is a dissection in anatomical space with small tissue traction which allows to freely separate compartments in the avascular layer. However, it should be stressed that a very good anatomical knowledge of the anterior abdominal wall is an important and indispensable condition for the success of this surgery. The surgery is safe, its main complication is a formation of hematoma above the mesh. Author of the method claims that they appear in 5% of cases. Other possible complications include mesh infection and formation of a seroma. Their quantity does not differ from other methods of hernia surgery with a mesh implant. The number of deaths after the Stoppa method is estimated at 0.25-0.5% and those were mainly due to thromboembolic complications. At present, due to routine preventive use of low molecular weight heparins, we can avoid this most serious complication. It is a very effective surgery, the recurrence is less than 1%. By dissecting in the preperitoneal space and not applying stitches, the risk of nerve damage is practically non-existent and therefore no chronic groin pain syndromes are observed which are a very significant complication after the Lichtenstein surgery.

The excellent results presented above come from the author of the method, Rene Stoppa (10). Results of general surgeons, who rarely use the described method, based on significantly smaller study material and taking into account the learning curve, as well as the general volume/outcome principle are probably worse, but it is difficult to prove with data. Of course, this applies not only to the Stoppa surgery, but also to all hernialogy. Definitely better results of specialized medical centers confirm the reasonability of establishing popular in the western Europe Hernia Centers and open a discussion that has been going on for a few years at EHS conventions on hernialogy as a separate specialization. We realize that this stage in Polish conditions is way ahead of us, and these words for the part of the surgical environment sound rather iconoclastic.

## SUMMARY

Stoppa surgery or as often referred to in literature – GPRVS (giant prosthesis for reinforcement of the visceral sac) is a perfect solution for difficult, recurrent inguinal hernias. It can also be used in large, bilateral idiopathic scrotal and femoral hernias (11). It allows to effectively and permanently protect the patient against successive relapses. Many years of using this method proved that it is safe for the patient and therefore should be popularized in Poland. It is also, what is important in Polish conditions, a relatively cheap procedure as it requires only a large standard hernia mesh. According to the authors, every surgeon who treats hernias should have it in their "portfolio" of skills and always consider its application in certain indications.

## REFERENCES


1. M. P. Simons, T. Aufenacker, M. Bay-Nielsen, J. L. Bouillot, G. Campanelli, J. Conze, D. de Lange, R. Fortelny, T. Heikkinen, A. Kingsnorth, J. Kukleta, S. Morales--Conde, P. Nordin, V. Schumpelick, S. Smedberg, M. Smietanski, G. Weber, M. Miserez; European Hernia Society guidelines on the treatment of inguinal hernia in adult patients; Hernia (2009) 13:343–403 DOI 10.1007/s10029-009-0529-7
2. Stoppa RE, Rives JL, Warlaumont CR, Palot JP, Verhaeghe PJ, Delattre JF; The use of Dacron in the repair of hernias of the groin; Surg Clin North Am. 1984 Apr;64(2):269-85
3. Stoppa R, Petit J, Henry X; Unsutured Dacron prosthesis in groin hernias; Int Surg. 1975 Aug;60(8):411-2.
4. Wantz GE; The technique of giant prosthetic reinforcement of the visceral sac performed through an anterior groin incision; Surg Gynecol Obstet. 1993 May;176(5):497-500
5. See comment in PubMed Commons belowStoppa RE; Wrapping the visceral sac into a bilateral mesh prosthesis in groin hernia repair; Hernia. 2003 Mar;7(1):2-12. Epub 2003 Jan 31
6. Wantz GE; Giant prosthetic reinforcement of the visceral sac. The Stoppa groin hernia repair; Surg Clin North Am. 1998 Dec;78(6):1075-87
7. Read RC; Crucial steps in the evolution of the preperitoneal approaches to the groin: an historical review; Hernia. 2011 Feb;15(1):1-5. doi: 10.1007/s10029-010-0739-z. Epub 2010 Oct 26
8. Amid PK; Groin hernia repair: open techniques; World J Surg. 2005 Aug;29(8):1046-51
9. Read RC; Milestones in the history of hernia surgery: prosthetic repair; Hernia. 2004 Feb;8(1):8-14. Epub 2003 Oct 28
10. Stoppa RE; The treatment of complicated groin and incisional hernias; World J Surg. 1989 Sep-Oct;13(5):545-54
11. Munshi IA1, Wantz GE.: Management of recurrent and perivascular femoral hernias by giant prosthetic reinforcement of the visceral sac; J Am Coll Surg. 1996 May;182(5):417-22hernias by giant prosthetic reinforcement of the visceral sac. J. Am. Coll. Surg. 1996 May; 182 (5): 417–422.



Word count: 2300 Page count: 4 Tables: – Figures: 1 References: 11

DOI: 10.5604/01.3001.0010.5410

Table of content: https://ppch.pl/resources/html/articlesList?issueId=10478





Competing interests: The authors declare that they have no competing interests.





Corresponding author: Kinga Zastawna; General And Endocrine Surgery And Gastroenterological Oncology Department; e-mail: kinga.zastawna@gmail.com



Cite this article as: Ratajczak A., Lange-Ratajczak M., Zastawna K.; Stoppa method – forgotten surgery; Pol Przegl Chir 2017: 89 (4): 42-45