INDEX COPERNICUS INTERNATIONAL

Does abdominal ultrasound constituea useful tool in the diagnosis of appendicitis?

Mateusz Kamiński

Department of Gastroenterological, Oncological and General Surgery, 1st Clinical Hospital in Łódź, Poland; Head: PH, MD Piotr Jurałowicz

Article history: Received: 24.08.2017 Accepted: 15.02.2018 Published: 30.06.2018

ABSTRACT:

Introduction: Acute appendicitis is the most common acute abdominal illness. Despite progress in diagnosis, there is still a 20% negative appendectomy rate. The aim of the study was to determine the usefulness of abdominal sonography in the diagnosis of acute appendicitis.

Materials and methods: Data were collected retrospectively from 326 patients operated with suspected appendicitis, who had undergone abdominal ultrasound prior to surgery. Appendicitis was confirmed by pathology reports. There were two variants of positive abdominal sonography. In the first, positive ultrasound was visualized inflamed appendix. In the second variant, the sonographic diagnosis of appendicitis was based on a visualized inflamed appendix or one of indirect signs of appendicitis – localized periappendiceal fluid collection, enlarged lymph nodes, thickening of the intestinal wall in the right iliac fossa. Sensitivity, specificity, positive predictive value (PPV) and negative predictive value (NPV) were defined and compared.

Results: 83.74% patients have appendicitis in their pathologic report. In 39.53% cases, the appendix was visualized via abdominal ultrasound. In 65.95% cases of sonography, there occurred indirect signs. In the first variant, sensitivity, specificity, PPV and NPV amounted to 47.99%, 79.25%, 92.25% and 22.83%, respectively. In the second variant, they amounted to 67.77%, 43.40%, 86.05% and 20.72%, respectively. In the second variant, sensitivity was significantly higher ($p<0.001$), however specificity was significantly lower ($p<0.001$).

Conclusion: Limited sensitivity and specificity cannot be a confirmation of appendicitis. The typical clinical course with a negative ultrasound should not delay correct diagnosis and early surgical treatment.

KEYWORDS: appendicitis, ultrasonography, USG

INTRODUCTION

Acute appendicitis (AA) is the most common acute abdominal illness. It occurs mostly in the young population. The lifetime incidence of AA is 6-8% (1). It can be caused by luminal obstruction due to fecalith, lymphoid hyperplasia, rarely by appendiceal or caecal tumor. Infectious, genetic and family factors are also taken into consideration (2). Early surgical intervention has a good prognosis, however, the case is worse for patients with longer periods of untreated illness; therefore, it is important to make an early diagnosis and perform appendectomy. The final diagnosis is confirmed by a pathology report. Despite progress in diagnostics (diagnostic scales, abdominal sonography and CT-scans), the negative appendectomy rate is 20% and is higher in women (3). The aim of this study was to determine the usefulness of abdominal sonography in AA diagnosis in clinical practice.

MATERIAL AND METHODS

Data were collected retrospectively from 326 consecutive, unselected patients who underwent appendectomy at the Department of General and Transplant Surgery and Department of Gastroenterological, Oncological and General Surgery from January 2014 and December 2016 with AA suspicion who had undergone a preoperative abdominal sonography (AS). AS was performed by radiologists or radiological residents. The final diagnosis was confirmed by a pathology report.

Data were analyzed by using the Statistica 13.1 soft. Sensitivity, specificity, positive (PPV) and the negative (NPV) predictive value were defined in a 95% confidence interval. Sensitivity and specificity were than compared with McNemar's test. The significance level was set at $p<0.05$.

There were two variants of positive AS:

First Variant:

- Positive AS – visualization of a noncompressible appendix with a diameter over 6mm
- Negative AS – visualization of a normal appendix or a nonvisualized appendix

Second Variant:

- Positive AS – visualization of an abnormal appendix or at least one indirect sign of appendicitis: fluid collection in the right iliac fossa, enlarged lymph nodes, thickening of the intestinal wall in the right iliac fossa
- Negative AS – visualization of a normal appendix or a nonvisualized appendix without indirect signs of appendicitis.

RESULTS

326 patients were included in the study. The patient demographics ale listed in Table I. Age distribution of the patients is shown in Figure 1. The youngest patient was 18, the eldest, 84 years old. There were more women than men in the study. The female population was not significantly younger than the male ($p=0.4$). The negative appendectomy rate was 16.26%; acute appendicitis was found in 83.74% pathology reports. The negative appendectomy rate was higher in women than men (19.19% and 12.99%; $p=0.13$ – not statistically significant). In 156 persons, AS appendix was identified, from which it was inflamed in 142 of the cases (39.53% of the population). In 215 cases of (65.95%) AS, indirect signs of the inflammation process in the right iliac fossa or infammed appendix were found (Table II). There were also two women with appendicitis caused by endometriosis (pathology report – Table III).

In the first variant (Table IV) – a positive AS was a visualization of an inflamed appendix, negative AS – normal appendix or appendix not found – sensitivity, specificity, PPV and NPV amounted to 47.99% (95% CI 41.93%-54,09%), 79.25% (65.89%-8916%), 92.25% (87.40-95.34%) and 22.83% (19.83-26.13%), respectively. In the men population, NPV was higher, other values were lower.

In the second variant – a positive AS was a visualization of an inflamed appendix or one of indirect signs of inflammation – sensitivity, specificity, PPV and NPV amounted to 67.77% (95% CI 61.87%-73.27%), 43.40% (29.84%-57.72%), 86.05% (82.77%-88.78%) and 20.72% (15.52%-27.10%), respectively. In this variation, the values, except for NPV, were also lower in women than in men. In the second variant, there was statistically significant higher sensitivity ($p<0.001$) and statistically significant lower specificity ($p<0.001$) of AS.

DISCUSSION

The diagnosis of appendicitis still poses a challenge. It is based on physical examination with the application of a diagnostic scale, for example, the Alvarado and Eskelinen scale, laboratory tests and medical imaging. It decreases a 20% negative appendectomy rate (3). The most common and cheapest medical imaging method is abdominal sonography. The use of AS and the Alvarado scale together in ambiguous clinical cases improves the percentage of correct appendicitis diagnosis from 62.8% to 86.2% (5). However, AS also has certain limitations – it depends from the patient's obesity and radiologist experience with his subjective assessment. In our study, AS sensitivity was 48% (First Variant) and 67.8% (Second Variant – with indirect appendicitis signs). According to other studies, sensitivity varies from 34% (6) to 99.3% (7), whereas specificity ranges from 68.1% (7) to 97% (8). Such large differences and high values depend on the diagnostic criteria of appendicitis and whether AS was performed by well experienced radiologist, which is not always possible in everyday clinical practice. In Doria's meta-analysis (2006), sensitivity and specificity were 83% and 93% (9), respectively. In older meta-analyses (1995), they amoun-

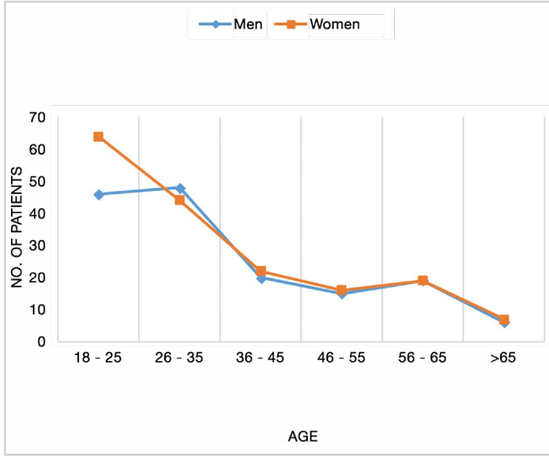

Fig. 1. Age distribution according to gender.

Tab. I. Population.

	WOMEN	MEN	ALL
Number of patients	172 (52.76%)	154 (47.24%)	326
Average age	35.1	35.79	35.4

Tab. II. Ultrasound findings.

	ALL		WOMEN		MEN	
	No.	%	No.	%	No.	%
Appendix visualized	156	47.85%	76	44.19%	80	51.95%
Inflamed appendix	142	43.56%	68	39.53%	74	48.05%
Fluid collection in right iliac fossa	132	40.49%	75	43.60%	57	37.01%
Enlarged mesenteric lymph nodes	24	7.36%	17	9.88%	7	4.55%
Thickening of intestinal wall in right iliac fossa	20	6.13%	10	5.81%	10	6.49%

Tab. III. Pathology report.

	NORMALAPPENDIX		ACUTE APPENDICITIS		PURULENT APPENDICITIS		GANGRENOUS APPENDICITIS		ENDOMETRIOSIS	
	No.	%	No.	%	No.	%	No.	%	No.	%
Women	33	19.19%	38	22.09%	75	43.60%	24	13.95%	2	1.16%
Men	20	12.99%	24	15.58%	80	51.95%	30	19.48%	0	0.00%
All	53	16.26%	62	19.02%	155	47.55%	54	16.56%	2	0.61%

Tab. IV. Sensitivity, Specificity, PPV and NPV of Abdominal Sonography.

	FIRST VARIANT			SECOND VARIANT		
	All	Women	Men	All	Women	Men
Sensitivity	**47.99%**	43.88%	52.24%	**67.77%**	66.91%	68.66%
Specificity	**79.25%**	78.79%	80.00%	**43.40%**	39.39%	50.00%
PPV	**92.25%**	89.71%	94.59%	**86.05%**	82.30%	90.20%
NPV	**22.83%**	25.00%	20.00%	**20.72%**	22.03%	19.23%

PPV – positive predictive value ; NPV – negative predictive value
First Variant – Positive AS – visualized inflamed appendix
Second Variant – Positive AS – visualized inflamed appendix or at least one indirect sign of appendicitis

ted to 84.7% and 92.1% (10), respectively. This study reveals that AS is most favorablein patients with non-typical presentation. In patients with typical symptoms, AS has a high rate of false negative results (12.5%). This leads to delayed appendicitis diagnosis, therefore authors in these cases suggest to operate without AS (10).

Increased use of CT scanning for appendicitis diagnosis can be observed. The limitations of CT are ionizing radiation and the need of contrast application. It is more expansive than sonography, not so common and it delays the time to operation (11, 12). This delay does not influence the appendix perforation rate (12). Sensitivity and specificity vary from 75% (14) to 100% (15), and 83% (14) to 97% (16), respectively. In Doria's meta-analysis, these values were 94% in both cases (9). The negative appendectomy rate decreased from 21.5% to 10.% (11). These results assured some authors that abdominopelvic CT should be the initial approach for suspected appendicitis (6).

Diagnostic laparoscopy can also decrease the negative appendectomy rate. If the appendix is not inflamed during laparoscopy, some authors advise to not perform appendectomy. The greatest benefit from these procedures was observed in women (17). Other authors suggest to perform appendectomy even in such cases, as in 25% of such patients, appendicitis occurs in the pathology report (18).

CONCLUSIONS

Limited sensitivity and specificity of AS cannot unequivocally confirm or exclude acute appendicitis. When indirect signs of inflammation of the right iliac fossa are taken into consideration, the sensitivity of AS is significantly higher, however, in contrast, specificity is significantly lower. AS may allow to find other abnormalities, which is why it should be performed in the suspicion of appendicitis. Result of AS should be considered through clinical examination performed by an experienced surgeon. A negative AS result with a typical clinical course should not delay correct diagnosis and early surgical treatment.

REFERENCES:

1. Addiss D.G., Shaffer N., Fowler B.S., Tauxe R.V.: The epidemiology of appendicitis and appendectomy in the United States. Am. J. Epidemiol. 1990; 132: 910–925.
2. Bhangu A., Soreide K., Di Saverio S., Assarsson J.H., Drake F.T.: Acute appendicitis: modern understanding of pathogenesis, diagnosis, and management. Lancet. 2015; 386: 1278–1287.
3. Stein G.Y., Rath-Wolfson L., Zeidman A. et al.: Sex differences in the epidemiology, seasonal variation, and trends in the management of patients with acute appendicitis. Langenbecks. Arch. Surg. 2012; 397: 1087–1092.
4. Mostbeck G., Jane Adam E., Bachmann Nielsen M. et al.: How to diagnose acute appendicitis: ultrasound first. Insights Imaging. 2016; 7: 255–263.
5. Bielaczyc G., Krasowski G., Sokołowski D., Tukiendorf A.: The Use of Ultrasonography in the Diagnosis of Ambiguous Cases of Appendicitis in Adults. Pol. Przegl. Chir. 2007; 79: 629–634.
6. Wise S.W., Labuski M.R., Kasales C.J. et al.: Comparative assessment of CT and sonographic techniques for appendiceal imaging. AJR Am. J. Roentgenol. 2001; 176: 933–941.
7. Chen S.C., Chen K.M., Wang S.M., Chang K.J.: Abdominal sonography screening of clinically diagnosed or suspected appendicitis before surgery. World J. Surg. 1998; 22: 449–452.
8. Styrud J., Josephson T., Eriksson S.: Reducing negative appendectomy: evaluation of ultrasonography and computer tomography in acute appendicitis. Int. J. Qual. Health Care. 2000; 12: 65–68.
9. Doria A.S., Moineddin R., Kellenberger C.J. et al.: US or CT for Diagnosis of Appendicitis in Children and Adults? A Meta-Analysis. Radiology. 2006; 241: 83–94.
10. Orr R.K., Porter D., Hartman D.: Ultrasonography to evaluate adults for appendicitis: decision making based on meta-analysis and probabilistic reasoning. Acad. Emerg. Med. 1995; 2: 644–650.
11. Pritchett C.V., Levinsky N.C., Ha Y.P., Dembe A.E., Steinberg S.M.: Management of acute appendicitis: the impact of CT scanning on the bottom line. J. Am. Coll. Surg. 2010; 210: 699–707.
12. Bickell N.A., Aufses A.H. Jr, Rojas M., Bodian C.: How time affects the risk of rupture in appendicitis. J. Am. Coll. Surg. 2006; 202: 401–406.
13. Krajewski S., Brown J., Phang P.T., Raval M., Brown C.J.: Impact of computed tomography of the abdomen on clinical outcomes in patients with acute right lower quadrant pain: a meta-analysis. Can. J. Surg. 2011; 54: 43–53.
14. Poortman P., Lohle P.N., Schoemaker C.M. et al.: Comparison of CT and sonography in the diagnosis of acute appendicitis: a blinded prospective study. AJR Am. J. Roentgenol. 2003; 181: 1355–1359.
15. Kan J.H., Fines B.P., Funaki B.: Conventional and hydrocolonic US of the appendix with CT correlation performed by on-call radiology residents. Acad. Radiol. 2001; 8: 1208–1214.
16. Horton M.D., Counter S.F., Florence M.G., Hart M.J.: A prospective trial of computed tomography and ultrasonography for diagnosing appendicitis in the atypical patient. Am. J. Surg. 2000; 179: 379–381.
17. van den Broek W.T., Bijnen A.B., van Eerten P.V., de Ruiter P., Gouma D.J.: Selective use of diagnostic laparoscopy in patients with suspected appendicitis. Surg. Endosc. 2000; 14: 938–941.
18. Hussain A., Mahmood H., Singhal T., Balakrishnan S., El-Hasani S.: What is positive appendicitis? A new answer to an old question. Clinical, macroscopical and microscopical findings in 200 consecutive appendectomies. Singapore Med. J. 2009; 50: 1145–1149.

Word count: 1090 Page count: 4 Tables: 4 Figures: 1 References: 18

DOI: 10.5604/01.3001.0011.8165 Table of content: https://ppch.pl/issue/11207

Competing interests: The authors declare that they have no competing interests.

Corresponding author: Mateusz Kamiński, Oddział Chirurgii Gastroenterologicznej, Onkologicznej i Ogólnej, USK nr 1 im. N. Barlickiego w Łodzi, ul. Kopcińskiego 22, 90-153 Łódź, fax: +48 42 678 11 76, e-mail: kaminski.mat@gmail.com

Cite this article as: Kamiński M.; Does abdominal ultrasound constituea useful tool in the diagnosis of appendicitis?; Pol Przegl Chir 2018: 90 (3): 10-13