INDEX COPERNICUS INTERNATIONAL

ORIGINAL ARTICLE

Asymptomatic radiological changes in computed tomography in children with head trauma

Authors' Contribution:
A – Study Design
B – Data Collection
C – Statistical Analysis
D – Data Interpretation
E – Manuscript Preparation
F – Literature Search
G – Funds Collection

Aleksandra Marciniak[ABCDEF], Grażyna Mielnik-Niedzielska[DEF]

Pediatric Otolaryngology Clinic Medical University of Lublin, Poland; Head: Grażyna Mielnik-Niedzielska MD PhD

Article history: Received: 17.02.2019 Accepted: 17.06.2019 Published: 09.07.2019

ABSTRACT:

Introduction: Computed tomography is an important imaging technique in Emergency Units. Thanks to its popularity, radiological changes are found in healthy children more commonly. The aim of this paper is to evaluate the incidence of maxillary sinus radiological changes in children with head trauma who admitted to the Emergency Unit of the University Children Hospital in Lublin.

Material and Methods: A retrospective analysis of computed tomography scans of children suffering from head trauma admitted to the Emergency Unit of the University Children Hospital in Lublin was carried out. A group of 425 patients was analyzed.

Results: Maxillary findings were present in 81 cases (19.06%); in 38 patients (8.94%) the changes were unilateral, while in 43 (10.12%) they were bilateral. Maxillary mucosal thickening was the most common radiological abnormality, present in almost 12% of the investigated cases (approximately 62% of all revealed changes). Maxillary total opacification as an isolated finding was found in younger children only. Retention cysts and maxillary polyps were found with a similar low frequency as maxillary opacification but in elder children only.

Discussion: Asymptomatic radiological changes in computed tomography scans are common. Maxillary mucosal thickening is the most frequent asymptomatic abnormality. Maxillary polyps and pseudocysts are rare in the paediatric population. Maxillary opacification suggests other more significant pathologies and requires further diagnostics. Physicians should avoid diagnosing patients with sinusitis without proper examination and based on radiological abnormalities only. Paediatric patients with revealed maxillary changes should remain under regular laryngological control.

KEYWORDS: child, maxillary sinus, radiography

INTRODUCTION

Computed tomography (CT) is one of the most important imaging techniques in Emergency Units in cases of head trauma. It allows rapid diagnosis and adequate treatment adjustment when it comes to brain injuries. Due to its popularity, there are radiological changes found in healthy children more and more commonly. These changes are frequently localized in maxillary sinuses. Detectability of these radiological pathologies may lead to unreasonable therapy in children who do not require urgent medical interventions. It is vital to remember that clinical symptoms have to occur to diagnose sinusitis. Research performed in many countries shows that the incidence of maxillary sinus radiological changes in adults ranges between 16 and 44% [1–3], and in children between 26% and 61% [4, 5]. Some of the authors take into account sinus mucosa thickening only, excluding retention cysts or maxillary sinus polyps; age structure seems to be also a significant factor, as well as climate conditions in which the patients live. Presumably, all mentioned factors may interfere with the cited outcomes. The aim of this paper is to evaluate the incidence of maxillary sinus radiological changes in CT in children with head trauma admitted to the Emergency Unit of the University Children Hospital in Lublin.

MATERIALS AND METHODS

Retrospective analysis of CT scans of children between 1- and 18-years old suffering from head trauma, admitted to the Emergency Unit of the University Children Hospital in Lublin between April and September 2018 was performed. Due to high percentage (ranging up to 80%) of radiological maxillary abnormalities in children aged under 1 year [6], these patients were excluded from the study. Eventually, 570 CT images were taken under analysis. Medical records of the included patients were investigated, which led to exclusion of cases presenting facial trauma, symptomatic sinusitis and ongoing upper respiratory tract infection. Incomplete CT scans not showing maxillary sinuses as a whole were also eliminated from the study.

CT scans were performed with Simens Definition AS+ CT scanner in spiral protocol. Radiological abnormalities found in maxillary sinuses included mucosal thickening, maxillary polyp, maxillary retention cyst and maxillary sinus total opacification.

Maxillary mucosal thickening was recognized as thickness of the layer in CT image of at least one wall exceeding 3 mm (Fig. 1.). Maxillary polyp was defined as a pedunculated homogenous

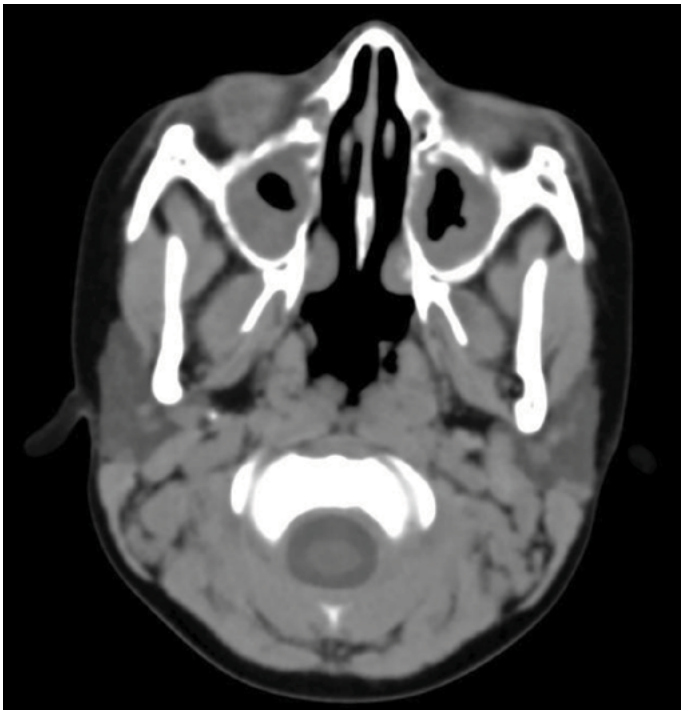

Fig. 1. Massive bilateral maxillary mucosal thickening.

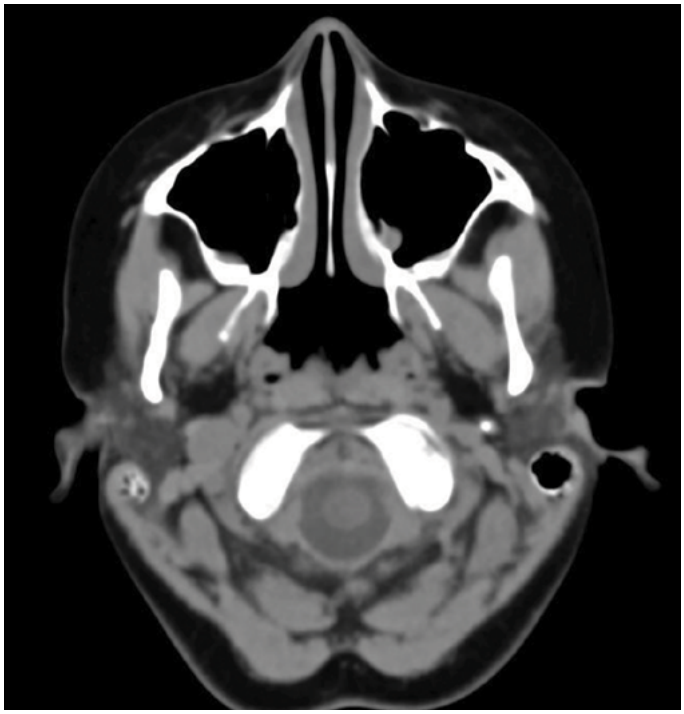

Fig. 2. Polypoid mass located in left maxillary sinus.

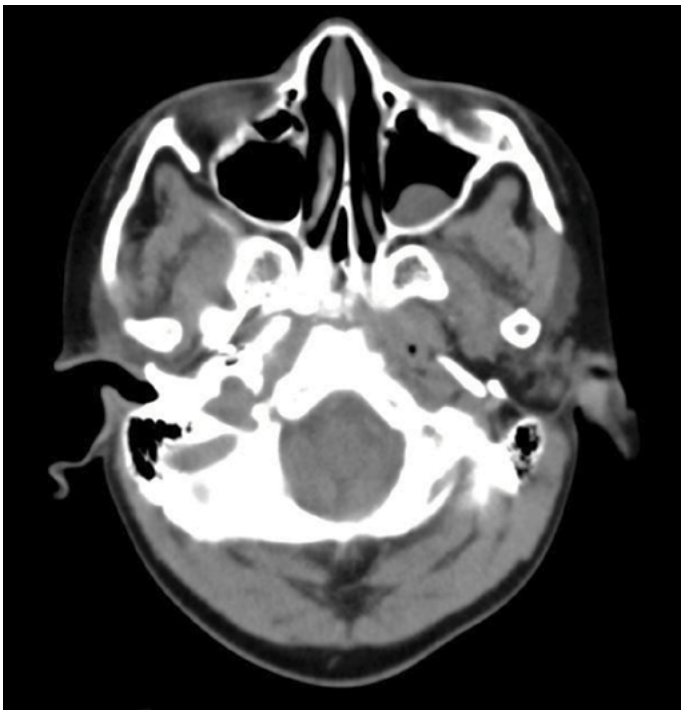

Fig. 3. Retention cyst located in left maxillary sinus.

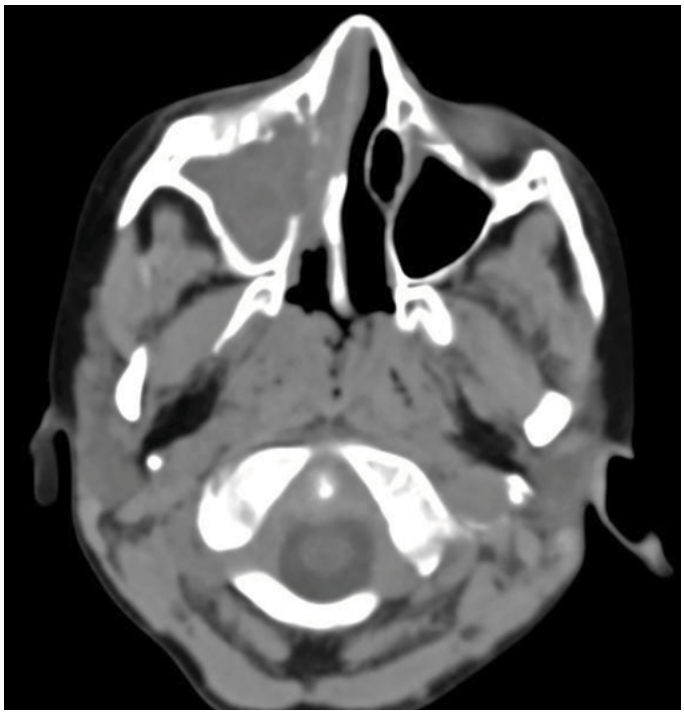

Fig. 4. Total opacification of right maxillary sinus.

mass projecting from the maxillary mucosa (Fig. 2.). Retention cysts were represented as round hypodense homogenous lesions with a sharp edge, situated within the sinus borders (Fig. 3.). Total opacification referred to increased attenuation comprising at least two-thirds of the maxillary air space (Fig. 4.). Statistical analysis for the study was performed using Microsoft Excel and Statistica software. Outcomes were presented in tables or diagrams and thoroughly described in the text below.

RESULTS

A group of 425 children (consisting of 185 girls and 240 boys) was analyzed. Subjects were divided into two age categories: 1–9 years old (younger children) and 10–18 years old (older children) for statistical purposes. Group structures are presented in Tab. I.; mean age of patients was 10 years (± 4.6). In 344 cases (80.94%) the CT scans revealed no maxillary abnormalities. Radiological changes

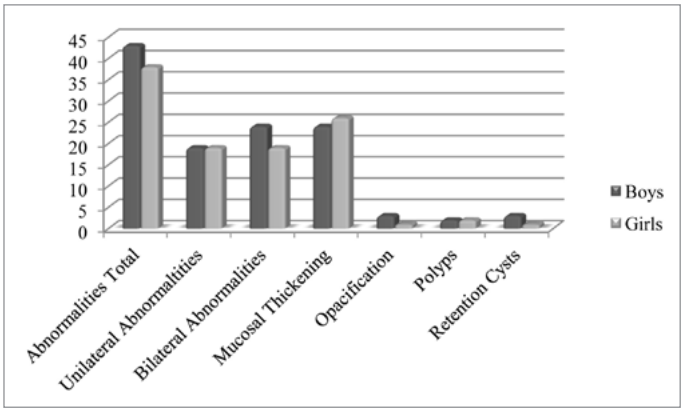

Fig. 5. Radiological abnormalities occurrence depending on gender.

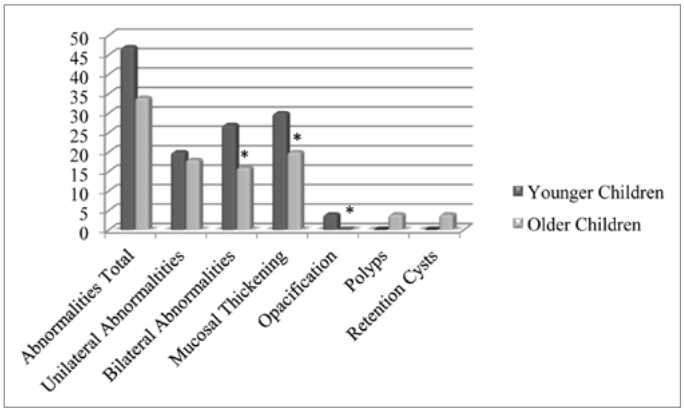

Fig. 6. Radiological abnormalities occurrence depending on age.

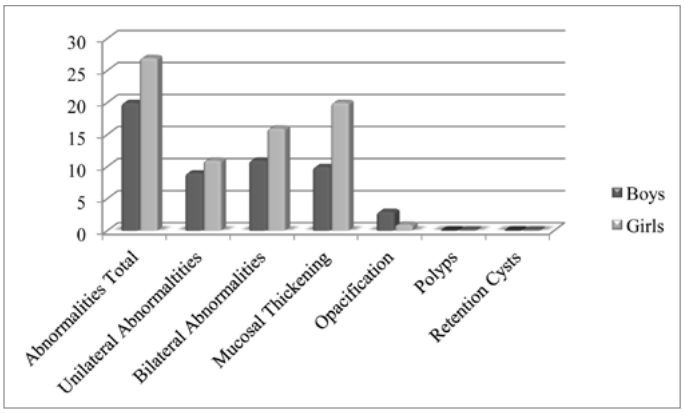

Fig. 7. Radiological abnormalities occurrence in younger children depending on gender.

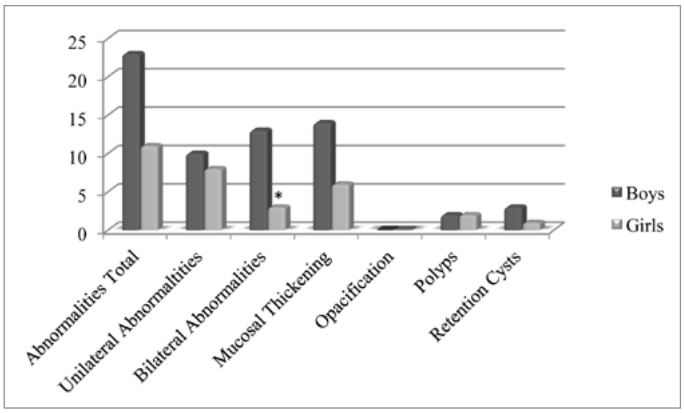

Fig. 8. Radiological abnormalities occurrence in older children depending on gender.

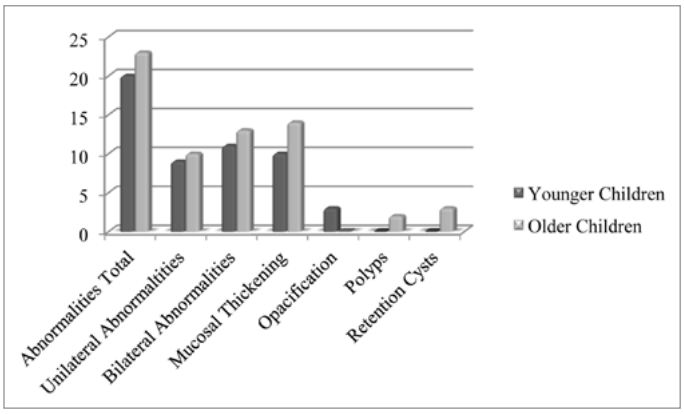

Fig. 9. Radiological abnormalities occurrence in boys depending on age.

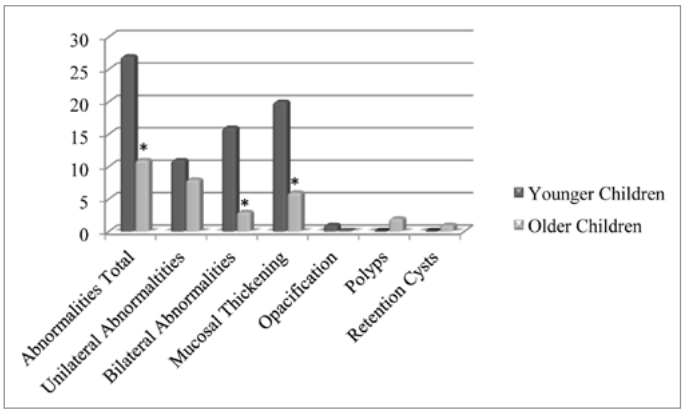

Fig. 10. Radiological abnormalities occurrence in girls depending on age.

were found with comparable frequency in both genders (Fig. 5.). Maxillary findings were present in 81 cases (19.06%); in 38 patients (8.94%) the changes were unilateral, while in 43 patients (10.12%) the changes were bilateral (Tab. II.). Bilateral abnormalities were presented significantly more often in younger children group regardless of the gender (P = 0.0269) (Fig. 6.); maxillary mucosal thickening was the most frequent bilateral finding in the study.

Maxillary mucosal thickening was the most common radiological abnormality in the analyzed group, present in almost 12% of the investigated cases (approximately 62% of all revealed changes) its occurrence did not vary between boys and girls but was significantly higher in children aged 1-9 years (P = 0.0468) (Fig. 6.). Maxillary total opacification as an isolated finding was discovered exclusively in younger children (P = 0.0324) (Fig. 6.). Retention cysts and maxillary polyps were found with a similar low frequency as maxillary opacification; however, the above-mentioned abnormalities were not found in younger children (Tab. III.). No significant difference concerning the presence of radiological changes was observed between both genders in the younger children group (Fig. 7.).

Tab. I. Group structure.

AGE GROUP	1–9 YEARS OLD	10–18 YEARS OLD
Girls	90 (21.17%)	95 (22.35%)
Boys	109 (25.65%)	131 (30.83%)
Total	199 (46.82%)	226 (53.18%)

Bilateral findings were observed significantly more often in elder boys than elder girls (P = 0.0357); other disparities showed no statistical significance (Fig. 8.).

No significant difference concerning the occurrence of radiological changes was observed between boys from both age groups (Fig. 9.). Meanwhile, statistical significance was found when comparing female patients from both age groups: maxillary abnormalities occurred significantly more often in girls aged 1–9 years (P = 0.0019), significantly more often bilaterally in younger girls (P = 0.0011), and significantly more often in this gender group CT scans revealed maxillary mucosal thickening among younger children (P = 0.0019).

DISCUSSION

Radiological changes located in maxillary sinuses are rather common. Many authors connected the occurrence of those abnormalities with patients' health condition including dental status, place of inhabitancy or influence of climate and environment factors.

The analysis performed for this study showed that in most cases the images of maxillary sinuses found in CT scans were normal, which conforms with the results presented by other authors [1].

It is believed that recent exposure to upper respiratory tract infection may be a potential cause for occurrence of abnormal findings in paranasal sinuses [7]; reactive maxillary mucosal thickening may persist for several weeks after symptoms of common cold subside. Allergy co-participation is another commonly assumed cause of incidental CT maxillary findings, especially when the abnormalities are revealed in peak season for allergen activity (spring and summer months) [2]. Some of the authors consider mucosal thickening not exceeding 3 mm in CT images as physiological periodic changes in the mucosa of the maxillary sinuses [8].

Statistical differences described by various authors may be caused by the characteristics of the study groups including quantity, age, health status and symptoms, inclusion and exclusion criteria for patients; imaging examination factors such as scanning device characteristics and features, diagnostic criteria of radiological abnormalities, type of maxillary changes included in the analysis [3]; and lastly, climate and environment factors or occurrence of upper respiratory tract infection [7].

Asymptomatic radiological abnormalities located in the maxillary sinuses are estimated to occur in 16.7–33.3% of the paediatric population [3]. Our study showed a similar incidence (19% cases). Mucosal thickening can be revealed in 16–26.2% of conventional CT scans performed among healthy children [3, 7]. Our analysis showed a lower incidence of the abnormality (11% of cases), which may be due to a seasonal factor – CT scans chosen for the study were performed during summer months when the incidence of upper respiratory tract infections is lower compared to other seasons. Therefore, continuing the study may be implicated. The difference may also result from excluding infants from analysis. Due to the lack of adequate information in the Emergency Unit medical records concerning recent upper respiratory tract infections or co-existing allergies, the influence of the mentioned above factors could not be properly assessed.

Maxillary polyps were present in almost 1% of the analyzed cases. Ani et al. estimated the occurrence of polyps at 8.3% in adult and children population [1]. Polypoid abnormalities in paranasal sinuses appear extremely rarely in younger children (under 5 years old), with their incidence rising with age [9]. It is assumed that polyps arise from mucosa irritated by recurrent upper respiratory tract infections or long-term exposure to hostile environment factors; hence, paranasal polyps are not commonly found in young population [1].

Asymptomatic retention cysts located in the maxillary sinuses are present in 2.9% to almost 36% of patients depending on demographic factors and imaging techniques [10]. Authors of the cited studies do not present the percentage rates for particular age groups; therefore, it seems infeasible to compare them to our study results. It is widely known that incidentally discovered asymptomatic maxillary retention cysts tend to either regress spontaneously or do not grow bigger in long-term observations; in most cases these pathological structures remain clinically silent [11]. Moreover, some authors believe that the incidence of maxillary retention cysts is even greater in asymptomatic patients (35.6%) than in people suffering from chronic sinusitis (22%) [12].

In a study including patients under 13 years, maxillary or ethmoid opacification was present in one third of paediatric patients who underwent CT scanning for non-laryngological indications [3]; our study revealed the incidence of total opacification of the maxillary sinus of 1% of cases. The difference may be explained by minor clinical significance of the presented radiological changes, and the fact that many radiologists ignore its presence in standard image descriptions, especially in cases when other more vital maxillary abnormalities e.g. polyps or mucosal thickening are visualized [7].

Nowadays, cone beam computed tomography (CBCT) has become the basic highly specialistic imaging technique used widely by dentists; due to much lower doses of radiation in comparison to a conventional (spiral) CT, it is becoming more commonly chosen by laryngologists to assess the nasopharynx, paranasal sinuses or inner ear structures. The incidence of asymptomatic maxillary abnormalities in CBCT images ranges from 24% to 63% in general population and nearly 50% in paediatric patients [13, 14].

Edwards et al. estimated that maxillary mucosal thickening can be present in 18.1% of CBCT images performed in patients aged from 5 to 46 years [13]. Another study revealed mucosal abnormalities in 31.3% of asymptomatic subjects aged from 9 to 74 years [10]. Other authors evaluated the incidence of clinically silent maxillary mucosal changes or retention cysts at 55% among patients aged from

Tab. II. Maxillary CT image findings.

CT IMAGE OF MAXILLARY SINUSES	NORMAL	UNILATERAL ABNORMALITIES	BILATERAL ABNORMALITIES	ABNORMALITIES TOTAL
1–9 years old Total	152 (76.38%)	47 (23.62%)	20 (10.05%)	27 (13.57%)
1–9 years old Girls	63 (70.00%)	27 (30.00%)	11 (12.22%)	16 (17.78%)
1–9 years old Boys	89 (81.65%)	20 (18.35%)	9 (8.26%)	11 (10.09%)
10–18 years old Total	192 (84.96%)	34 (15.04%)	18 (7.96%)	16 (7.08%)
10–18 years old Girls	84 (88.42%)	11 (11.58%)	8 (8.42%)	3 (3.16%)
10–18 years old Boys	108 (82.44%)	23 (17.56%)	10 (7.63%)	13 (9.93%)
Total	344 (80.94%)	81 (19.06%)	38 (8.94%)	43 (10.12%)
Girls	147 (79.46%)	38 (20.54%)	19 (10.27%)	19 (10.27%)
Boys	197 (82.08%)	43 (17.92%)	19 (7.92%)	24 (10.00%)

Tab. III. Types of maxillary changes.

ABNORMALITY	MUCOSAL THICKENING	OPACIFICATION	POLYP	RETENTION CYST
1–9 years old Total	30 (15.08%)	4 (2.01%)	0 (0.00%)	0 (0.00%)
1–9 years old Girls	20 (22.22%)	1 (1.11%)	0 (0.00%)	0 (0.00%)
1–9 years old Boys	10 (9.17%)	3 (2.75%)	0 (0.00%)	0 (0.00%)
10–18 years old Total	20 (8.85%)	0 (0.00%)	4 (1.77%)	4 (1.77%)
10–18 years old Girls	6 (6.32%)	0 (0.00%)	2 (2.11%)	1 (1.05%)
10–18 years old Boys	14 (10.69%)	0 (0.00%)	2 (1.53%)	3 (2.29%)
Total	50 (11.76%)	4 (0.94%)	4 (0.94%)	4 (0.94%)
Girls	26 (14.05%)	1 (0.54%)	2 (1.08%)	1 (0.54%)
Boys	24 (10.00%)	3 (1.25%)	2 (0.83%)	3 (1.25%)

5 to 87 years [15]. We failed to find studies that consisted of paediatric population exclusively, hence, the cited statistics considered both children and adult subjects. The incidence of asymptomatic radiological abnormalities in magnetic resonance imaging seems to exceed the results found in computed tomography; some authors assess their presence at almost 60% in the adult population [7]. Lim et al. estimated the incidence of clinically silent paranasal pathologies in Australian children aged from 0 to 15 years to subtly exceed 30% [16]. German researchers revealed paranasal mucosal thickening in 48% of magnetic resonance images of paediatric subjects [5].

Asymptomatic radiological changes resolve untreated in most cases [17]. It is required to attentively follow up pathologies that demonstrate progression in sequent imaging or when distressing symptoms occur [13]. Taking this into consideration, children with clinically silent abnormalities on CT (or other imaging techniques) should be regularly controlled by an otolaryngologist.

A radiologist should carefully assess every radiological change and avoid diagnosing patients with sinusitis on the basis of imaging scans only. Children suspected of sinusitis should be referred to an otolaryngologist for adequate medical attention, regular controls with symptom assessment and, if needed, effective treatment.

CONCLUSIONS

1. Asymptomatic radiological changes in CT scans are common, with the incidence in young children being twice as high as in elder children;

2. Mucosal thickening of the maxillary sinus greater than 3 mm in CT scans is the most frequent asymptomatic abnormality;

3. Maxillary polyps and pseudocysts are rare in paediatric population, especially in patients aged under 10 years;

4. Maxillary opacification suggests other more significant pathologies and requires further diagnostics;

5. Radiological changes in paranasal sinuses require proper health status assessment;

6. Physicians should avoid diagnosing patients with sinusitis without proper examination and based on radiological images only;

7. Paediatric patients with revealed maxillary changes should remain under regular laryngological control.

REFERENCES

1. Ani C.C., Adoga A.A., Tawe G.S.: Incidental maxillary sinus findings on cranial computerized tomographic scan in a tropical setting. J West African Coll Surg [Internet], 2016; 6(2): 39–51. Available from: http://ovidsp.ovid.com/ovidweb.cgi?T=JS&PAGE=reference&D=prem&NEWS=N&AN=28344946.
2. Manning S.C., Biavati M.J., Phillips D.L.: Correlation of clinical sinusitis signs and symptoms to imaging findings in pediatric patients. Int J Pediatr Otorhinolaryngol., 1996; 37(1): 65–74.
3. Nazri M., Bux S.I., Tengku-Kamalden T.F., Ng K.H., Sun Z.: Incidental detection of sinus mucosal abnormalities on CT and MRI imaging of the head. Quant Imaging Med Surg., 2013; 3(2): 82–88.
4. Ortega H.W., Vander Velden H., Reid S.: Incidental findings on computed tomography scans in children with mild head trauma. Clinical Pediatrics, 2012.
5. Von Kalle T., Fabig-Moritz C., Heumann H., Winkler P.: Incidental findings in paranasal sinuses and mastoid cells: A cross-sectional magnetic resonance imaging (MRI) study in a pediatric radiology department. RoFo Fortschritte auf dem Gebiet der Rontgenstrahlen und der Bildgeb Verfahren., 2012; 184(7): 629–634.
6. Glasier C.M., Mallory G.B., Steele R.W.: Significance of opacification of the maxillary and ethmoid sinuses in infants. J Pediatr., 1989; 114(1): 45–50.
7. del Rio A., Trost N., Tartaglia C., O'Leary S.J., Michael P.: Seasonality and incidental sinus abnormality reporting on MRI in an Australian climate. Rhinology., 2012; 50(3): 319–324.
8. Rak K.M., Newell J.D., Yakes W.F., Damiano M.A., Luethke J.M.: Paranasal sinuses on MR images of the brain: Significance of mucosal thickening. Am J Roentgenol., 1991; 156(2): 381–384.
9. Uduma F., Yaouda D.: Incidental Para-Nasal Polyps on Brain MRI Images in a Cameroonian Population. Glob J Health Sci [Internet], 2011; 3(2): 118–122. Available from: http://www.ccsenet.org/journal/index.php/gjhs/article/view/7869
10. Çağlayan F., Tozoğlu Ü.: Incidental findings in the maxillofacial region detected by cone beam CT. Diagnostic Interv Radiol., 2012; 23(11): 1261–1268.
11. Wang J.H., Jang Y.J., Lee B.J.: Natural course of retention cysts of the maxillary sinus: Long-term follow-up results. Laryngoscope, 2007; 117(2): 341–344.
12. Harar R.P.S., Chadha N.K., Rogers G.: Are maxillary mucosal cysts a manifestation of inflammatory sinus disease? J Laryngol Otol., 2007; 121(8): 751–754.
13. Edwards R., Alsufyani N., Heo G., Flores-Mir C.: The frequency and nature of incidental findings in large-field cone beam computed tomography scans of an orthodontic sample. Prog Orthod., 2014; 15: 37.
14. Diament M.J., Senac M.O., Gilsanz V., Baker S., Gillespie T., Larsson S.: Prevalence of incidental paranasal sinuses opacification in pediatric patients: A CT study. J Comput Assist Tomogr., 1987; 11(3): 426–431.
15. Allareddy V., Vincent S.D., Hellstein J.W., Qian F., Smoker W.R.K., Ruprecht A.: Incidental findings on cone beam computed tomography images. Int J Dent., 2012; 12.
16. Lim W.K., Ram B., Fasulakis S., Kane K.J.: Incidental magnetic resonance image sinus abnormalities in asymptomatic Australian children. J Laryngol Otol., 2003; 117(12): 969–972.
17. Phothikhun S., Suphanantachat S., Chuenchompoonut V., Nisapakultorn K.: Cone-Beam Computed Tomographic Evidence of the Association Between Periodontal Bone Loss and Mucosal Thickening of the Maxillary Sinus. J Periodontol., 2012; 85(5): 557–564.

Word count: 2650 Tables: 3 Figures: 10 References: 17

DOI: 10.5604/01.3001.0013.2459 Table of content: https://otolaryngologypl.com/issue/12452

Competing interests: The authors declare that they have no competing interests.

Corresponding author: Aleksandra Marciniak; Pediatric Otolaryngology Clinic Medical University of Lublin, Poland; Prof. Antoniego Gębali Street 6, 20-867 Lublin; Phone: + 48 510 081 082; E-mail: marciniak.alex@gmail.com

Cite this article as: Marciniak A., Mielnik-Niedzielska G.: Asymptomatic radiological changes in computed tomography in children with head trauma; Otolaryngol Pol 2019; 73 (5): 5-11